

# Prevention and treatment of experimental peri-implantitis

Ahmed Almohandes

Department of Periodontology,  
Institute of Odontology at  
Sahlgrenska Academy  
University of Gothenburg

Gothenburg, Sweden, 2021



UNIVERSITY OF  
GOTHENBURG

*Prevention and treatment of experimental peri-implantitis*

© 2021 Ahmed Almohandes

Ahmed.Almohandes@gu.se

ISBN 978-91-8009-544-0 (PRINT)

ISBN 978-91-8009-545-7 (PDF)

<http://hdl.handle.net/2077/69671>

Printed in Borås, Sweden 2021

Stema Specialtryck AB



*To my parents  
Saleha and Ali  
and to my little family  
Azzah, Ali Jr. and the special Mohammed ..*





# Abstract

Peri-implantitis is a plaque-associated pathological condition occurring in tissues around dental implants. It is characterized by inflammation in the peri-implant mucosa and progressive loss of supporting bone. The aims of the present series of studies were to (a) analyze the effect of plaque-formation on implant abutments with an antibacterial coating, (b) evaluate the effect of surgical treatment of experimental peri-implantitis using different decontamination methods, (c) evaluate the effect of the use of bone substitute materials on soft and hard tissue healing following reconstructive surgical therapy and (d) evaluate the accuracy of bone level assessments using either cone beam computed tomography, intra-oral periapical radiographs or histology.

In Study I, plaque formed on implant abutments with an antimicrobial coating for 6 months. Data from radiological, microbiological and histological examinations were analyzed. In Study II, III and IV, different surgical treatment protocols of experimental peri-implantitis were applied to implants with different surface characteristics. Radiographs were obtained to longitudinally evaluate disease progression and treatment outcome and block biopsies were obtained and prepared for histological analysis. In Study IV, cone beam computed tomography was obtained following reconstructive treatment of experimental peri-implantitis.

Implant abutments with an antibacterial coating failed to prevent biofilm formation and did not influence the inflammatory response in the adjacent peri-implant mucosa (Study I). Disease resolution of experimental peri-implantitis occurred after surgical therapy using different methods for implant surface decontamination (Study II and III). Healing following surgical treatment of experimental peri-implantitis was superior around implants with a smooth surface than at implants with rougher surfaces (Study II and III). Defect fill and re-osseointegration following reconstructive peri-implantitis surgery occurred at 23 out of 24 implants with a smooth surface and at 13 out of 24 implants with a moderately rough surface. The additional effect of using bone substitute materials during surgery was small (Study III). Significant correlations were observed between assessments of marginal bone levels using cone beam computed tomography, periapical radiographs or histology. Measurements in periapical radiographs consistently resulted in an overestimation of the bone level of about 0.3 mm (Study IV).

**Keywords:** Antibacterial, bone substitute material, CBCT, histology, implant surface, marginal bone level, peri-implantitis, radiograph, surface decontamination



# Sammanfattning på svenska

Peri-implantit är bakterieorsakad sjukdomsprocess i vävnader runt tandimplantat. Tillståndet kännetecknas av inflammation i den peri-implantära slemhinnan och förlust av stödjevävnad. Syftet med denna serie av studier var att utvärdera (a) effekten av en antibakteriell ytbehandling på tandimplantat på bildandet av bakteriebeläggningar, (b) läkningsresultatet efter kirurgisk behandling av experimentellt inducerad peri-implantit med olika rengöringsmetoder, (c) tilläggseffekten av benersättningsmaterial i samband med rekonstruktiv kirurgisk behandling av experimentell peri-implantit och (d) precisionen vid bennivåbestämningar runt tandimplantat genom mätningar i intraorala röntgenbilder, datortomografi, eller histologiska preparat.

I studie I ansamlades bakterier under 6 månader på implantatdistanser med en antibakteriell ytbehandling och resultat från röntgenologiska-, mikrobiologiska- och histologiska undersökningar analyserades. I studierna II, III och IV användes olika protokoll vid kirurgisk behandling av experimentell peri-implantit vid implantat med olika ytstrukturer. Röntgenundersökningar genomfördes under försöket för att utvärdera effekten av sjukdomsutveckling och efterföljande behandling. Blockbiopsier uthämtades för histologisk preparation och analys. I studie IV kompletterades undersökningen vid försökets slut med datortomografi.

Implantatdistanser med en antibakteriell ytbehandling förhindrade inte uppbyggnaden av bakteriebeläggningar och påverkade därmed inte det inflammatoriska svaret i den peri-implantära slemhinnan (studie I). Olika rengöringsmetoder av implantat i samband med kirurgisk behandling av experimentell peri-implantit resulterade i utläkning av sjukdom (studie II och III). Läkningsresultatet efter behandling var bättre vid implantat med slät yta jämfört med implantat med en rå yta (studie II och III). Läkning av bendefekter med återskapande av benkontakt mot implantat efter rekonstruktiv kirurgisk behandling inträffade vid 23 av 24 implantat med slät yta och vid 13 av 24 implantat med rå yta. Tilläggseffekten av användandet av benersättningsmaterial vid rekonstruktiv kirurgisk behandling var liten (studie III). Signifikant korrelation noterades mellan bennivåbestämningar som utförts genom mätningar i intraorala röntgenbilder, datortomografi, eller histologiska preparat. Mätningar i intraorala röntgenbilder resulterade i en överskattning av bennivån på cirka 0,3 mm (studie IV).



# List of papers

This thesis is based on the following studies, referred to in the text by their Roman numerals.

- I. Almohandes, A., Abrahamsson, I., Dahlén, G., & Berglundh, T. (2021). Effect of biofilm formation on implant abutments with an anti-bacterial coating: A pre-clinical in vivo study. *Clinical Oral Implants Research*, 32(6), 756-766.
  
- II. Almohandes, A., Abrahamsson, I., Dionigi, C., & Berglundh, T. (2021) Surgical treatment of experimental peri-implantitis using mechanical and chemical procedures. A pre-clinical in vivo study. *Submitted for publication*.
  
- III. Almohandes, A., Carcuac, O., Abrahamsson, I., Lund, H., & Berglundh, T. (2019). Re-osseointegration following reconstructive surgical therapy of experimental peri-implantitis. A pre-clinical in vivo study. *Clinical Oral Implants Research*, 30(5), 447-456.
  
- IV. Almohandes, A., Lund, H., Carcuac, O., Petzold, M., Berglundh, T., & Abrahamsson, I. (2021) Accuracy of bone level assessments following reconstructive surgical treatment of experimental peri-implantitis. *Submitted for publication*.



# Content

<b>13</b>	<b>Abbreviations</b>
<b>15</b>	<b>Introduction</b>
15	Peri-implant diseases
15	Prevention of peri-implant disease
16	Experimental peri-implantitis
19	Treatment of experimental peri-implantitis
19	Implant surface characteristics
20	Radiological assessment of surgical therapy
<b>25</b>	<b>Research questions and aims</b>
<b>27</b>	<b>Material and Methods</b>
30	The preparatory phase
30	Dental implant units
30	Experimental peri-implant disease
31	Intra-oral photographs
32	Radiographic examination
32	Intra-oral periapical radiographs
34	Cone beam computed tomography
35	Microbiological sampling and analysis
35	Culturing technique
36	Checkerboard DNA-DNA hybridization technique
37	Surgical treatment of experimental peri-implantitis
39	Histological preparation and analysis
43	Data analysis
<b>45</b>	<b>Results</b>
<b>61</b>	<b>Main findings</b>
<b>63</b>	<b>Concluding remarks</b>
63	Experimental peri-implantitis models
64	Prevention of peri-implant diseases
67	Implant surface decontamination
67	Impact of implant surface on healing following treatment
69	Reconstructive treatment protocols
70	Accuracy of radiological assessments
<b>73</b>	<b>Acknowledgements</b>
<b>75</b>	<b>References</b>
<b>85</b>	<b>Appendix</b>





# Abbreviations

<b>aBiofilm</b>	Apical termination of the biofilm
<b>A/F</b>	Abutment/fixture
<b>aJE</b>	Apical termination of the barrier/junctional epithelium
<b>ANOVA</b>	Analysis of variance
<b>B</b>	Most coronal position of bone to implant contact
<b>BC</b>	Most coronal position of the bone crest
<b>BD</b>	Bottom of the defect
<b>BIC</b>	Bone to implant contact
<b>CBCT</b>	Cone beam computed tomography
<b>e-PTFE</b>	Expanded polytetrafluoroethylene
<b>EDTA</b>	Ethylene-diamine-tetra-acetic acid
<b>Er:YAG</b>	Erbium doped yttrium-aluminum-garnet
<b>FDDB</b>	Freeze-dried demineralized bone
<b>GBR</b>	Guided bone regeneration
<b>ICT</b>	Infiltrated connective tissue
<b>MBL</b>	Marginal bone level
<b>mg/L</b>	Milligram per Liter
<b>MPO</b>	Myeloperoxidase
<b>N<sub>2</sub>O:O<sub>2</sub></b>	Nitrous oxide: Oxygen
<b>PA</b>	Periapical
<b>PM</b>	Peri-implant mucosa
<b>PVD</b>	Physical Vapor Deposition
<b>r</b>	Pearson correlation coefficients
<b>SD</b>	Standard deviation
<b>SLA</b>	Sandblasted, large grit, acid-etched
<b>Ti-Bi-Ga</b>	Titanium-Bismuth-Gallium
<b>TPS</b>	Titanium plasma sprayed
<b>TTC</b>	Tetracycline Hydrochloric acid
<b>TVC</b>	Total viable count
<b>VLC</b>	Visible light cure



# Introduction

## Peri-implant diseases

Peri-implant diseases is a collective term for the two entities peri-implant mucositis or peri-implantitis (Berglundh, Armitage, Araújo, Avila-Ortiz, Blanco, Camargo, Chen, Cochran, Derks, Figuero, Hämmerle, Heitz-Mayfield, Huynh-Ba, Iacono, Koo, Lambert, McCauley, Quirynen, Renvert, Salvi, Schwarz, Tarnow, Tomasi, Wang, & Zitzmann, 2018a). Peri-implant mucositis is a plaque-associated pathological condition in the peri-implant mucosa in the absence of peri-implant bone loss (Heitz-Mayfield & Salvi, 2018), while peri-implantitis in addition to inflammation in the peri-implant mucosa is characterized by loss of supporting bone (Berglundh et al., 2018a; Schwarz, Derks, Monje, & Wang, 2018). Peri-implant mucositis is a reversible condition if adequately treated (Meyer et al., 2017; Roos-Jansåker, Renvert, & Egelberg, 2003; Salvi et al., 2012). In the absence of treatment, however, it may progress into peri-implantitis.

Peri-implantitis is a common condition among patients treated with dental implants (Derks & Tomasi, 2015). In a large randomly selected sample from the Swedish population, peri-implantitis was detected in 45% of patients 9 years after dental implant therapy (Derks et al., 2016). The focus on prevention and treatment of peri-implant diseases is therefore justified. In order to maintain peri-implant health, the consensus report from XI European Workshop on Periodontology emphasized that preventive measures according to individual needs should be performed on a regular basis (S. Jepsen et al., 2015; Salvi & Zitzmann, 2014).

## Prevention of peri-implant diseases

Adequate self-performed infection control in combination with professional supportive therapy following dental therapy is a successful method to prevent peri-implant diseases (Heitz-Mayfield & Salvi, 2018; Salvi & Zitzmann, 2014). Nevertheless, the prevalence of peri-implantitis still remains high (Derks et al., 2016). Therefore, an implant device that can provide antimicrobial properties preventing biofilm formation might reduce the occurrence of peri-implant diseases. The concept of using implant devices with antimicrobial properties was

investigated in both *in-vitro* and *in-vivo* preclinical studies (Carinci et al., 2019; Cochis et al., 2015; 2016; Ghensi et al., 2019; Sobolev et al., 2019; Xing et al., 2015). It was reported from several *in-vitro* experiments that certain implant coatings may prevent bacterial colonization (Cochis et al., 2015; 2016; Nagay et al., 2019). Nagay et al. (2019) in an *in-vitro* experiment reported on antimicrobial activity on titanium discs co-doped with nitrogen and bismuth. Moreover, Cochis et al. (2015) performed *in-vitro* and *in-vivo* experiments on the antibacterial effect of silver and gallium ion-treated titanium discs. The discs were mounted on dental acrylic splints that were placed in seven volunteers. After 24 hours of plaque accumulation, silver and gallium-treated discs showed to be effective in reducing the number of bacterial colonies. Information on antibacterial properties of different materials, however, seems to be restricted to short-term evaluations in clinical settings. Experimental models that mimic clinical settings are therefore needed for long-term evaluations of potential antibacterial effects of materials.

## Experimental peri-implantitis

Pre-clinical *in-vivo* models have been widely used in studies on dental implants (Grunder, Hürzeler, Schupbach, & Strub, 1993; Lindhe, Berglundh, Ericsson, Liljenberg, & Marinello, 1992; Marinello et al., 1995; Persson, Ericsson, Berglundh, & Lindhe, 1996; Tillmanns, Hermann, Cagna, Burgess, & Meffert, 1997). The ligature-induced experimental peri-implantitis is such a model, which has been used to evaluate the progression and the treatment of peri-implantitis (Carcuac et al., 2013; Carcuac, Abrahamsson, Charalampakis, & Berglundh, 2015; Hürzeler, Quiñones, Morrison, & Caffesse, 1995; Persson et al., 1996; Zitzmann, Berglundh, Ericsson, & Lindhe, 2004). Throughout the years, the method for inducing experimental peri-implantitis has been developed and different ligature techniques, materials and time of exposure have been used (Carcuac, Abrahamsson, Derks, Petzold, & Berglundh, 2020; Lindhe et al., 1992; Schüpbach, Hürzeler, & Grunder, 1994). The idea of using ligatures is to disrupt the mucosal seal and allow biofilm to accumulate sub-marginally (Lindhe et al., 1992). Moreover, the number and frequency of ligature replacements have varied between studies (Table 1). Lindhe et al. (1992) in an experimental study in dogs, placed cotton ligatures in a sub-marginal position around implants in order to induce experimental peri-implantitis. During a period of plaque formation, the ligatures were replaced after 3 weeks and removed after additional 3 weeks. It was reported that peri-implantitis became established with a disease process that surrounded the implants. Schüpbach et al. (1994) used ligatures together with

plaque formation over 5 months to induce peri-implantitis. The ligatures were replaced every month during the experiment. Marinello et al. (1995) used ligatures for 4-6 weeks but with no replacement. They reported that about 25% of original bone height was lost during the experimental period. Recently, Carcuac et al. 2020 introduced a new model with a single and short-term (one month) use of ligatures to induce experimental peri-implantitis. Following ligature removal, plaque formation was allowed to continue accumulation for 6 months as spontaneous progression of experimental peri-implantitis. It was demonstrated that the short-term use of ligatures disrupted the soft tissue barrier and together with plaque formation initiated the disease process. Carcuac et al. (2020) observed a small amount of bone loss after the short period of ligatures. Therefore, such a model can be used to investigate the potential antibacterial effect of implant materials on the prevention of experimental peri-implantitis.

**Table 1.** Examples of pre-clinical studies using different protocols of ligature induced peri-implantitis.

Author (Year)	Total ligature period	Number of replacement		Ligature material
Lindhe et al. (1992)	6 weeks	1	Biopsy after one month	Cotton
Grunder et al. (1993)	5 months	5	Treatment after ligature removal	Cotton
Marinello et al. (1995)	4-6 weeks	0	Biopsy after 1 and 3 months	Cotton
Persson et al. (1996)	6 weeks	0	Treatment after one month of ligature removal	Cotton
Tillmanns et al. (1997)	3 and 6 months	If needed	Biopsy after 3 and 6 months	Cotton
Persson et al. (1999)	3 months	2	Treatment after one month of ligature removal	Cotton
Wetzel et al. (1999)	4 months	3	Treatment after one month of ligature removal	Silk
Machado et al. (1999)	1 month	0	Treatment after one month of ligature removal	Cotton
Nociti et al. (2001)	4 weeks	0	Treatment after two weeks of ligature removal	Cotton
Deppe et al. (2001)	3 months	0	Treatment after two weeks of ligature removal	Cotton
Shibli et al. (2003)	2 months	2	No spontaneous progression period	Cotton
Zitzmann et al. (2004)	2 months	3	Spontaneous progression for 12 months	Cotton
Hayek et al. (2005)	120 days	0	Spontaneous progression for 120 days	Unspecified
Schwarz et al. (2006)	3 months	3	Treatment after one month of ligature removal	Cotton
Berglundh et al. (2007)	4 months	7	Spontaneous progression for 5 months	Cotton
Albouy et al. (2008)	12 weeks	3	Spontaneous progression for 24 weeks	Cotton
Madi et al (2013)	4 months	4	Spontaneous progression for 5 months	Silk
Carcuac et al. (2013)	10 weeks	2	Spontaneous progression for 26 weeks	Cotton
Fickl et al. (2015)	10 weeks	4	Treatment after one month of ligature removal	Silk
Viganò et al. (2019)	3 months	1	Treatment after one month of ligature removal	Unspecified
Carcuac et al. (2020)	1 month	0	Spontaneous progression for 6 months	Cotton

## Treatment of experimental peri-implantitis

The experimental peri-implantitis model has been used to evaluate the efficacy of different systemic and local antimicrobial procedures (Carcuac et al., 2015; Ericsson, Persson, Berglundh, Edlund, & Lindhe, 1996; Persson, Araújo, Berglundh, Gröndahl, & Lindhe, 1999; Shibli et al., 2006) (Table 2). Ericsson et al. (1996) studied the effect of different antimicrobial therapies on experimental peri-implantitis lesions. Prior to and during the surgical treatment of peri-implantitis, a combination of systemic antibiotics was administered. In one side of the mandible, surgical removal of the granulation tissues around the implants in conjunction with sterilization of the dental abutments was performed, while the implants in the other side were left without any further treatment. It was reported that the plaque associated infiltrate in the untreated group remained. It was concluded that systemic antibiotic therapy alone was not sufficient to achieve disease resolution, while in the surgically treated group, disease resolution occurred. In another *in-vivo* study on treatment of experimental peri-implantitis, Persson et al. (1999) reported on the outcome of two different methods for decontamination (cotton pellets soaked in sterile saline or abrasive pumice with a rotating brush) of machined implant surfaces. It was reported that the inflammatory lesions were resolved and that small amounts of newly formed bone had formed in the original defects. No significant difference was observed between the treatment groups. Shibli et al. (2006) reported on the outcome of different local decontamination procedures during surgical treatment of peri-implantitis around implants with different types of surfaces. The local therapy was carried out using plastic curettes alone or in combination with bactericidal photosensitization. No differences between the treatment protocols or between different types of implants were observed. Carcuac et al. (2015) evaluated the effect of anti-infective procedures including gauze soaked in either saline or chlorhexidine during surgical treatment of experimental peri-implantitis at implants with four different surfaces. It was concluded that the additional local treatment with chlorhexidine had limited effect on the outcomes and that the results were mainly influenced by implant surface characteristics.

## Implant surface characteristics

Implant surfaces have been categorized based on surface roughness into smooth, minimally rough, moderately rough and rough (Albrektsson & Wennerberg, 2004). Moderately rough surfaces were claimed to have clinical advantages compared to other types of surfaces (Albrektsson & Wennerberg, 2004). Some clinical data, however, indicated a higher prevalence of peri-implantitis at im-

plants with a modified surface compared to implants with non-modified surface (Mir-Mari, Mir-Orfila, Figueiredo, Valmaseda-Castellón, & Gay-Escoda, 2012).

While the majority of studies on surgical treatment of experimental peri-implantitis focused on local or systemic antimicrobial treatment, few investigated the influence of different surface characteristics on the outcome of surgical treatment of peri-implantitis (Albouy et al., 2011; Carcuac et al., 2015; Wetzel, Vlassis, Caffesse, Hämmerle, & Lang, 1999). The outcome of experimental peri-implantitis treatment was superior around implants with a non-modified surface compared to implant with a modified surface irrespective of type of treatment (Albouy et al., 2011; Carcuac et al., 2015). A similar influence of implant surface characteristics was also reported in clinical studies (Berglundh, Wennström, & Lindhe, 2018b; Carcuac et al., 2016). Research aiming at improving dental implants should therefore focus on implant surfaces presenting with optimal healing capacities and a low propensity to onset and progression of peri-implant diseases.

## **Radiological assessment of surgical therapy**

In day-to-day clinical practice and in reporting on results from clinical studies on surgical treatment of peri-implantitis, clinical data are combined with radiological observations (Carcuac et al., 2016; K. Jepsen et al., 2016; Renvert, Roos-Jansåker, & Persson, 2018; Wohlfahrt et al., 2012). Thus, the radiological assessment is a key tool in monitoring and evaluating peri-implant hard tissues. Moreover, in trials reporting on treatment of peri-implantitis using reconstructive techniques, results from radiological assessments were frequently the main reported outcome (K. Jepsen et al., 2016; Renvert et al., 2018; Wohlfahrt et al., 2012). Moreover, while conventional (two-dimensional) radiographs cannot show the peri-implant bone level in the buccal and lingual aspects, cone beam computed tomography (CBCT) may provide a circumferential image of the peri-implant tissues. Nevertheless, the influence of using augmentation materials on the accuracy of radiological assessment of treatment of peri-implantitis is unknown. Thus, the necessity of evaluating the accuracy of radiological assessment following reconstructive surgical treatment of peri-implantitis is required.



**Table 2.** Pre-clinical in-vivo studies using different decontamination methods and different augmentation materials during surgical treatment of experimental peri-implantitis.

Author (Year)	Number of animals/implants	Implant type	Surface decontamination	Augmentation materials	Remarks
Hürzeler et al. (1995)	4 dogs 24 implants	Brånemark System	Air-powder abrasive	<ul style="list-style-type: none"> <li>Resorbable hydroxyapatite</li> <li>FDDB</li> <li>Gore-Tex membrane only</li> <li>FDDB + membrane</li> </ul>	There was no significant difference between guided bone regeneration and combinations of guided bone regeneration and different graft materials.
Persson et al. (1996)	5 dogs 30 implants	Brånemark System	<ol style="list-style-type: none"> <li>Mechanical + delmopinol HCl</li> <li>No surgery</li> </ol>	<ul style="list-style-type: none"> <li>e-PTFE membrane</li> </ul>	The elimination of the inflammation in the peri-implant tissues was achieved after surgical treatment.
Wetzel et al. (1999)	7 dogs 41 implants	Straumann <ul style="list-style-type: none"> <li>TPS</li> <li>SLA</li> <li>machined</li> </ul>	Mechanical + Chlorhexidine	<ul style="list-style-type: none"> <li>e-PTFE membrane</li> </ul>	Bone fill occurred at peri-implant bony defects. Re-ossseointegration appeared to be difficult to achieve.
Machado et al. (1999)	4 dogs 16 implants	Napio® System	Air-powder abrasive	<ul style="list-style-type: none"> <li>e-PTFE membrane</li> <li>Bio-Oss + e-PTFE membrane</li> </ul>	No significant differences between treatment groups. Reconstructive methods provided more hard tissue fill than debridement alone.
Persson et al. (1999)	4 dogs 24 implants	Straumann (TPS)	<ol style="list-style-type: none"> <li>Cotton pellet soaked in sterile saline</li> <li>abrasive pumice with rotative brush</li> </ol>	<ul style="list-style-type: none"> <li>None</li> </ul>	Disease resolution and new bone formation occurred following both treatments. No significant differences between treatment groups.
Persson et al. (2001)	4 dogs 24 implants	Straumann <ul style="list-style-type: none"> <li>SLA</li> <li>Machined</li> </ul>	Mechanical only	<ul style="list-style-type: none"> <li>None</li> </ul>	Resolution of peri-implantitis and bone fill in adjacent bone defects were achieved around both types of implants.
Deppe et al. (2001)	6 dogs. 60 implants	Straumann (TPS)	<ol style="list-style-type: none"> <li>Air-powder abrasive</li> <li>CO<sub>2</sub> laser</li> <li>Air-powder abrasive + CO<sub>2</sub> laser</li> </ol>	<ul style="list-style-type: none"> <li>e-PTFE membrane</li> </ul>	No significant differences between treatment groups regarding bone gain. Implants in the laser groups showed more BIC% than implants in the other groups.

4 dogs 12 implants	Brånemark System	1. Cotton pellets soaked with citric acid (30 sec) + rinsing with saline solution 2. Toothbrush + saline (1 min) 3. Cotton pellet soaked with 10% hydrogen peroxide (1 min) + rinsing with saline solution.	None	Direct bone-to-implant contact on the previously exposed implant surface was achieved in all treatment groups.
8 monkeys 64 implants	Straumann (TPS)	1. Air-powder abrasive + citric acid 2. Air-powder abrasive 3. Gauze soaked with saline + citric acid. 4. Gauze soaked with chlorhexidine and saline	<ul style="list-style-type: none"> <li>• Autogenous bone</li> <li>• e-PTFE membrane</li> </ul>	Bone fill and re-osseointegration were significantly higher in defects treated with autogenous bone e-PTFE membrane than other treatments.
8 monkeys 64 implants	Straumann (TPS)	gauze soaked alternately in 0.1% aqueous chlorhexidine and saline	<ul style="list-style-type: none"> <li>• Bio-Oss + e-PTFE membrane</li> <li>• Bio-Oss</li> <li>• e-PTFE membrane</li> </ul>	Bio-Oss + e-PTFE membrane group showed higher bone fill following treatment compared with the other three treatments. Prior to treatment, bony defects were significantly smaller in the control group than in the test group.
4 dogs 24 implants	Straumann <ul style="list-style-type: none"> <li>• Machined</li> <li>• SLA</li> </ul>	1. Curettes + cotton pellets soaked in sterile saline. 2. Curettes + CO <sub>2</sub> laser + hydrogen peroxide solution irrigation.	None	No significant difference between treatment groups in terms of re-osseointegration.
6 dogs 60 implants	Friadent (Plasma-sprayed)	1. Air-powder abrasive 2. Laser treatment alone 3. Combination of air-powder abrasive and laser treatment	None	All groups showed re-osseointegration following treatment. CO <sub>2</sub> laser irradiation rendered significantly more new bone formation compared to the air-powder abrasive group.
5 dogs 30 implants	Straumann (SLA)	1. Er:YAG laser 2. Ultrasonic device 3. Plastic curettes + local application of metronidazole gel	None	All treatment procedures showed a significant clinical improvement

Shibli et al. (2006)	5 dogs 40 implants	Implanted (Machined / TPS)  Biomet 3i (Osseotite)  Conexão Implants (microrough)	1. plastic curettes 2. plastic curettes + lethal photosensitization	e-PTFE membrane	No differences regarding re-osseointegration were observed between the different implant surface types.
Takasaki et al. (2007)	4 dogs 12 implants	Straumann (SLA)	1. Plastic curettes + sterile saline solution irrigation 2. Er-YAG laser + sterile saline solution irrigation	None	No significant difference was found between treatment groups.
Alhag et al. (2008)	4 dogs 12 implants	Nobel Biocare (TiUnite)	1. Cotton pellets soaked with citric acid (30 sec) + rinsing with saline solution 2. Toothbrush + saline (1 min) 3. Cotton pellet soaked with 10% Hydrogen peroxide (1 min) + rinsing with saline solution	None	All treatments promoted direct bone-to-implant contact on the previously exposed part of the implant.
Albouy et al. (2011)	6 dogs 48 implants	Biomet 3i (Turned) Astra Tech AB (Tioblast) Straumann (SLA) Nobel Biocare (TiUnite)	Gauzes impregnated with a sterile saline solution	None	Resolution of peri-implantitis following treatment without systemic or local antimicrobial therapy was possible. Treatment outcome was influenced by implant surface characteristics.
Caruane et al. (2015)	6 dogs 48 implants	Astra Tech AB (Tioblast) Astra Tech AB (OsseoSpeed) Astra Tech AB (AT-I) Nobel Biocare (TiUnite)	Gauze soaked in: 1. Saline 2. Chlorhexidine	None	The local use of chlorhexidine had a minor influence on treatment outcome. Treatment outcome was influenced by implant surface characteristics.

Park et al. (2015)	6 dogs 24 implants	Osstem (SA) (sandblasted with large grit alumina and acid-etched with HCl/H2SO4)	1. Manual irrigation 2. Dental water jet 3. Dental water jet + Superfloss	Xenograft bone Absorbable membrane	Decontamination using a dental water jet and dental floss was an effective method for mechanical debridement.
Namgoong et al. (2015)	5 dogs 30 implants	Osstem: Turned SA (sandblasted/acid-etched) HA (sandblasted/acid-etched and hydroxyapatite nanocoated)	Plastic curettes Cotton pellet alternately soaked in chlorhexidine and saline	Resorbable collagen membrane	The histometric analysis showed significantly enhanced bone formation (height) at SA and SA/HA compared with turned implants following reconstructive surgery. Amount of newly formed bone around SA/HA and turned implants was not significantly different.
Htet et al. (2016)	5 dogs 30 implants	Nobel Biocare (TiUnite)	1. Er:YAG laser 2. PDT (gallium aluminum arsenide diode laser) 3. Titanium bur 4. Titanium bur with 40% citric acid	Resorbable collagen membrane	Mechanical and chemical treatments were more effective for the anodized implant surface.
Ramos et al. (2017)	8 dogs 64 implants	Straumann (SLA)	1. TTC: (tetracycline HCL) 2. aPDT: (photosensitizer)	Xenograft bone Absorbable membrane	No significant differences were found between neither the two antimicrobial protocols nor the adjunctive use of GBR in terms of re-osseointegration or bone gain.
Vigano et al. (2019)	6 dogs 24 implants	Premium (ZrTi surface) <i>sand-blasting with zirconium oxide and acid etching with mineral acids</i>	1. Gauzes soaked in saline 2. Titanium rotating brush	None	No statistically-significant differences were found after the treatment.

# Research questions and aims

The following research questions and aims were addressed in the present series of pre-clinical studies.

## Questions

1. Can an implant surface with antimicrobial properties prevent or reduce peri-implant mucositis and peri-implantitis?
2. Do implant surface characteristics influence healing following treatment of peri-implantitis using different decontamination and reconstructive procedures?
3. Do different augmentation protocols influence healing following treatment of peri-implantitis using reconstructive procedures?
4. How do radiographic outcomes compare to results from histological assessments?

## Aims

- to analyze the long-term effect of plaque/biofilm formation on implant abutments with an antibacterial coating and the ensuing host response in peri-implant tissues (*Study I*).
- to evaluate the effect of surgical treatment of experimental peri-implantitis using mechanical and chemical decontamination methods (*Study II*).
- to evaluate the effect of the use of bone substitute materials on soft and hard tissue healing following reconstructive surgical therapy of experimentally induced peri-implantitis (*Study III*).
- to evaluate the effect of different surgical treatment protocols of experimental peri-implantitis at implants with different surface characteristics (*Study II & III*).
- to evaluate the accuracy of bone level assessments using either cone beam computed tomography, intra-oral periapical radiographs or histology following reconstructive treatment of experimental peri-implantitis (*Study IV*).

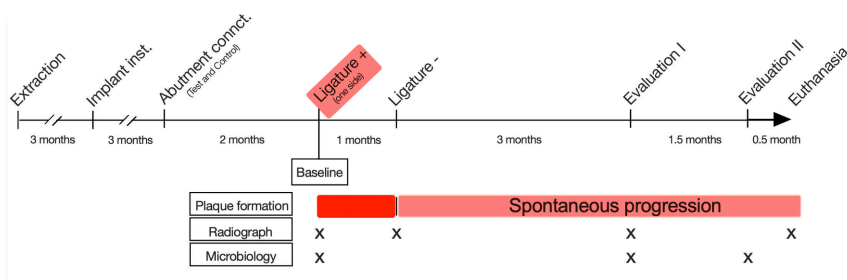
# Material and Methods

The four papers included in this thesis are based on three animal experiments (Fig. 1). For each experiment six, about one year old, Labrador dogs were used. The study protocols were approved by the regional Ethics Committee for Animal Research, Göteborg, Sweden (Dnr 106–2015), (Dnr 122-2017) and (Dnr 5-2014). All experiments utilized both sides of the dog mandible.

	Preparatory phase	Active breakdown period using ligatures	Treatment	Monitoring
Experiment I ( study I)	Tooth Extraction Implant installation	One month One side of the mandible	No treatment	Spontaneous progression for 6 months Microbiology
Experiment II ( study II)		Three months	Different decontamination procedures	Observation and oral hygiene
Experiment III (study III and IV)		Both sides of the mandible	Different reconstructive procedures	Observation and oral hygiene Intra-oral radiograph and photograph CBCT assessment

*Figure 1. Outline of the experiments.*

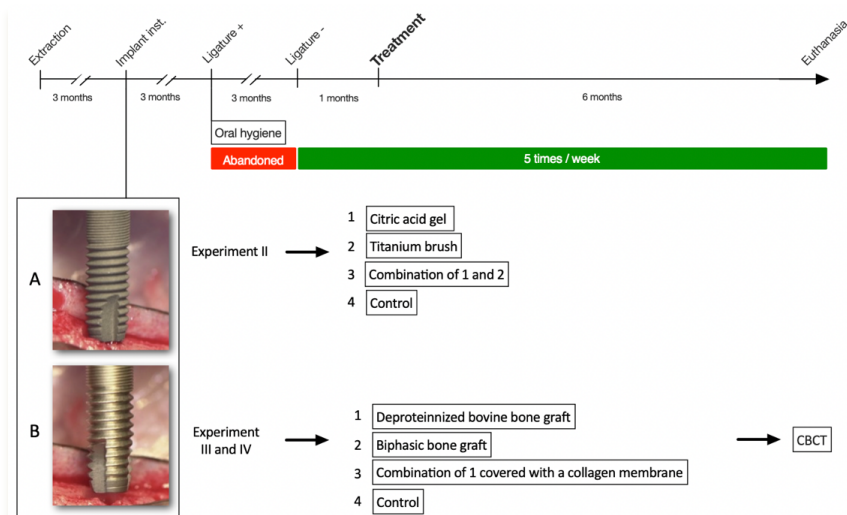
Study I was comprised of a preparatory period followed by an active breakdown period (using cotton ligatures) in one side of the mandible for one month, while a spontaneous progression of experimental peri-implantitis was allowed to the other side in the mandible. The spontaneous phase continued for 6 months. Radiological and microbiological examinations were made during the study and histological sections were prepared at the end of the study (Fig. 2).



**Figure 2.** Experiment I (Study I) outline.



In Study II, III and IV, a preparatory phase was followed by an active breakdown period (using cotton ligatures) for 3 months. The ligatures were exchanged every 3rd week. When about 40-50% of bone loss was assessed, different treatments of experimental peri-implantitis were performed. Radiographs were obtained at different timepoints to evaluate disease progression and treatment outcome. Histological sections for analysis were produced at the end of the experiments (Fig. 3).



**Figure 3.** Experiment II (Study II) and III (Study III and IV) outline.

## **The preparatory phase**

Prior to all surgical procedures, general anaesthesia was induced with intravenously injected Propofol (10 mg/ml, 0.6 ml/kg) and sustained with N<sub>2</sub>O:O<sub>2</sub> (1:1.5-2) and Isoflurane employing endotracheal intubation. Analgetics were provided during 3 days following all surgical procedures. All surgical procedures were performed by specialists in periodontology. All mandibular premolars and the 1<sup>st</sup>, 2<sup>nd</sup> and 3<sup>rd</sup> maxillary premolars were extracted. Three months later, mucoperiosteal flaps were elevated, 4 osteotomy preparations were made and implants were installed in each mandibular premolar region.

## **Dental implant units**

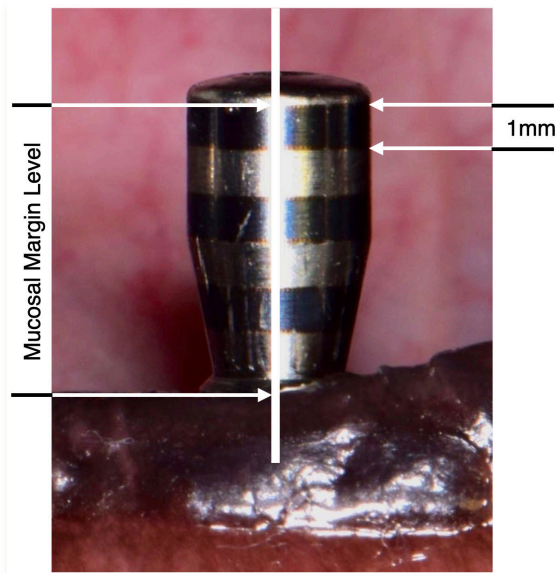
In Study I, one implant type (3.6 x 11mm Astra Tech Implant EV System; Dentsply Implants IH AB) and two different abutment types, test and control, were used. The test abutment was an experimental c.p. titanium Uni abutment (Astra Tech Implant System™, Dentsply Implants IH AB) with a Titanium-Bismuth-Gallium (Ti-Bi-Ga) coating while the control abutment was an uncoated c.p. titanium Uni abutment. In Study II,III and IV, 4 implants, 3.6 x 11mm, with 2 different surface characteristics (A and B) were installed in each mandibular premolar region. Implant A had a TiO<sub>2</sub>-blasted and etched surface (moderately rough), while implant B had a turned surface modified by a dual acid-etching (smooth). Healing abutments were Uni abutment and Zebra abutments in Study II and III, respectively.

## **Experimental peri-implant diseases**

Oral hygiene procedures were abandoned and experimental peri-implant disease was initiated three months after implant installation in all studies (I - IV). In Study I, cotton ligatures were placed in a sub-marginal position for one month in one side of the mandible and plaque formation was allowed until the end of the experiment. In Study II, III and IV, however, cotton ligatures were placed in a sub-marginal position around the neck portion of the implants and replaced every 3<sup>rd</sup> week until the final removal at 12 weeks. Oral hygiene procedures were re-instituted immediately after ligature removal.

## Intra-oral photographs (*Study III*)

At the time of surgery, intra-oral photographs were taken from each healing abutment using a digital camera (NIKON D5300, Nikon Corporation). A software program (ImageJ64, National Institutes of Health) was used for the analysis of the photographs. Using the known distance between the lines on each healing abutment (Zebra abutment), a calibration of the measurements was made (Fig. 4). The distance between the most coronal line on the healing abutment to the mid-buccal mucosal margin level was measured at each implant. Subsequent intra-oral photographs were taken every 2<sup>nd</sup> month following surgery until the final examination.



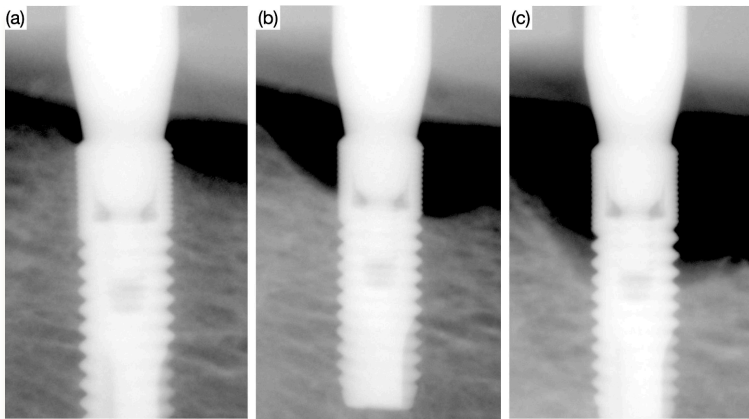
**Figure 4.** Photograph representing the mid-facial mucosal margin level. The known distance (1 mm) between marked lines on each healing abutment was used for the calibration of the coronal-apical measurements.

## Radiographic examination

### Intra-oral periapical radiographs

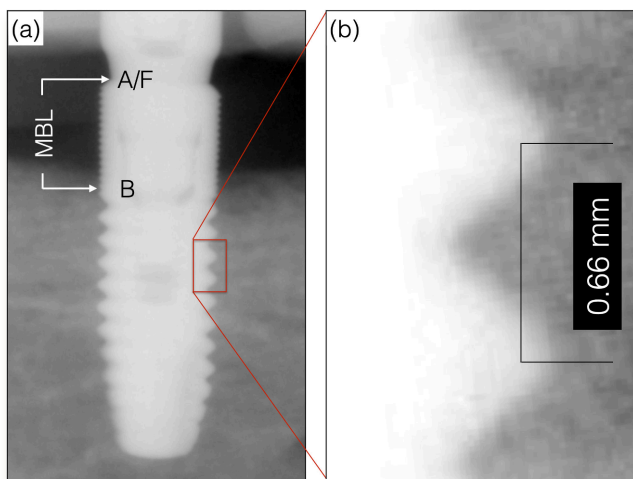
Intra-oral periapical radiographs were obtained using a long-cone paralleling technique and sensors for digital radiography from all implants at different time points during the experiments. Customized sensor holders were made using bite blocks and a silicon impression material, as previously described (Albouy et al., 2008; Persson et al., 1999).

In Study I, the first set of intra-oral periapical radiographs was taken at abutment connection. The radiographic examination was then repeated 2 (baseline), 3, 6 and 8 months after abutment connection. In Study II, III and IV, the first intra-oral periapical radiographs were taken three months after implant installation (ligature placement). During the phase of disease induction (three months), the radiographic examination was repeated every 3rd week (Fig. 5). An additional set of radiographs was obtained 2 weeks after surgical treatment of experimental peri-implantitis. In Study III, intra-oral periapical radiographs were also obtained at every 2<sup>nd</sup> month until the final examination.



**Figure 5.** Series of radiographs representing bone level changes around an implant during active (ligature-induced) experimental peri-implantitis at baseline (ligature placement) (a), 1.5 months (b) and at ligature removal (3months).

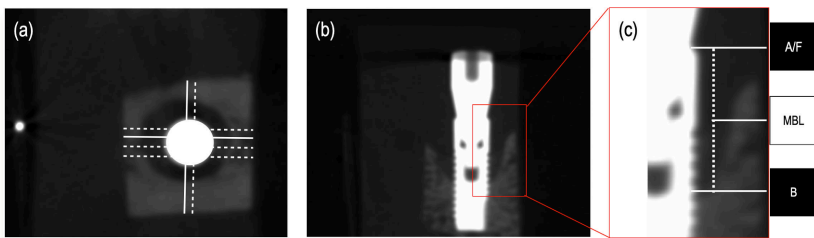
The intra-oral periapical radiographs were analyzed using a software (ImageJ64; National Institutes of Health, Bethesda, MD, USA). The known diameter and the inter-thread distance were used for the coronal-apical measurements (Fig. 6). In the radiographs, the abutment/fixture (A/F) shoulder and the most coronal position of bone to implant contact (B) were identified on mesial and distal sides of each implant. The marginal bone level (MBL), distance between A/F and B, at the mesial and distal aspect of each implant was measured on a high-definition monitor (10x magn.).



**Figure 6.** A radiograph (a) showing marginal bone level (MBL) from abutment/fixture junction (A/F) to the most coronal bone to implant contact (B). A magnified radiographic section (b) showing the known inter-thread distance.

## Cone beam computed tomography (CBCT) (*Study IV*)

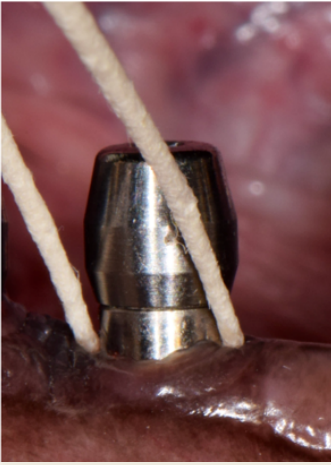At the end of experiment III (*Study IV*), the mandibles were retrieved and tissue blocks containing one implant and the surrounding soft and hard tissues were prepared. The tissue blocks were then placed in a plexiglass bowl, embedded in a soft tissue equivalent material, and thereafter placed on a stand in the radiographic equipment. The radiographic examination was performed using Accu-tomo 170 (J. Morita Mfg. Corp, Kyoto, Japan) utilizing an image volume of 40mm x 40mm, exposure parameters 80kV, 5mA and a 360-degree rotation. The voxelsize was set to 0.08mm. Image data, comprising axial slices with slice thickness and interval of 0.08mm, were exported using DICOM-format (Digital Imaging and Communications in Medicine). Thereafter the image data were imported into Osirix MD (Pixmeo SARL, 266 Rue de Bernex, CH-1233 Bernex, Switzerland) for image processing. In the CBCT images, MBL was defined as the distance between A/F and B. The MBL was assessed at four positions on each aspect around each implant (in all 16 positions / implant). Two central measurements and two other measurements were made 1 mm lateral to the central measurements (Fig. 7).



**Figure 7.** CBCT section (a) illustrating the orientation of CBCT cuts that correspond to histological sections (white line) and other cuts (dotted lines). Mesio-distal CBCT images (b). A magnified mesio-distal demonstrating marginal bone level (MBL) (c).

## Microbiological sampling and analysis (*Study I*)

Two months after the abutment connection procedure, sub-mucosal microbiological samples were collected from all experimental sites using paper-points (Fig. 8). The samples were placed in sterile Eppendorf tubes containing 300 microliters of TE buffer. Part of the sample solution was immediately analyzed for the total viable counts using a culture technique, while the remaining sample solution was analyzed using the checkerboard DNA-DNA hybridization technique. The microbiological sampling was repeated at 6 and 7.5 months after abutment connection.



*Figure 8. Photo showing paper-points collecting sub-mucosal microbiological samples.*

### Culturing technique

The samples were diluted and then spread over the surface of a Brucella agar plate (Acumedia, Neogen Corporation, Lansing, Michigan, USA) enriched with 5% defibrinated horse blood, 0.5% hemolysed horse blood and 5 mg/L of menadione. The plates were anaerobically incubated for 7 days in jars at 37 °C with an atmosphere of 10% H<sub>2</sub>, 10% CO<sub>2</sub> and 80 % N<sub>2</sub>. The total viable count (TVC) was determined as the total number of colony-forming units obtained on the Brucella agar plates.

## Checkerboard DNA-DNA hybridization technique

The checkerboard panel included 17 bacterial strains; 5 *Porphyromonas* species (*Porphyromonas gulae*, *Porphyromonas canoris*, *Porphyromonas crevoricanis*, *Porphyromonas cangingivalis* and a non-specified *Porphyromonas* species), 11 additional strains (*Tannerella forsythia*, *Fusobacterium canilifelium*, *Fusobacterium russi*, *Filifactor alocis*, *Filifactor villosus*, *Bacteroides tectus*, *Bacteriodes* sp, *Campylobacter oricanis*, *Pasturella stomatis*, *Campylobacter* sp, and *Peptostreptococcus canis*) and one human strain (*Treponema denticola*).

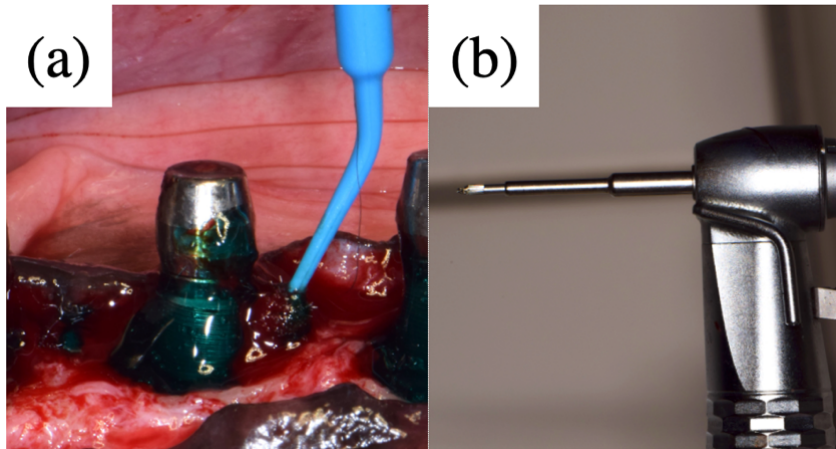
All samples from all three occasions and each dog were analyzed on one and the same checkerboard membrane. Evaluation of the signal was performed at a LumiImager<sup>TM</sup> workstation (Boehringer-Mannheim) by comparing the obtained signals with those of pooled standard samples containing  $10^6$  (high-standard) or  $10^5$  (low standard) of each of the 17 bacterial species of the panel. The obtained chemiluminiscent signals were transformed into a scale of scores from 0 to 5 (Socransky et al., 1994). In brief, score 0 represents no signals; score 1, a signal density weaker than the one of the low standard (i.e.  $< 10^5$  bacteria); score 2, a signal density equal to the one of the low standard ( $=10^5$  bacteria); score 3, a signal density higher than the one of the low standard but lower than that of high standard ( $>10^5$  but  $< 10^6$  bacteria); score 4, a signal density equal to the one of the high standard ( $=10^6$  bacteria) and score 5, a signal density higher than the one of the high standard ( $>10^6$  bacteria). The score 1 cut-off was selected to contrast colonized vs. non-colonized sites and the score 3 cut-off was used to contrast heavily colonized (score 3 or more) vs. non-colonized and less heavily colonized sites.



## **Surgical treatment of experimental peri-implantitis (Study II, III and IV)**

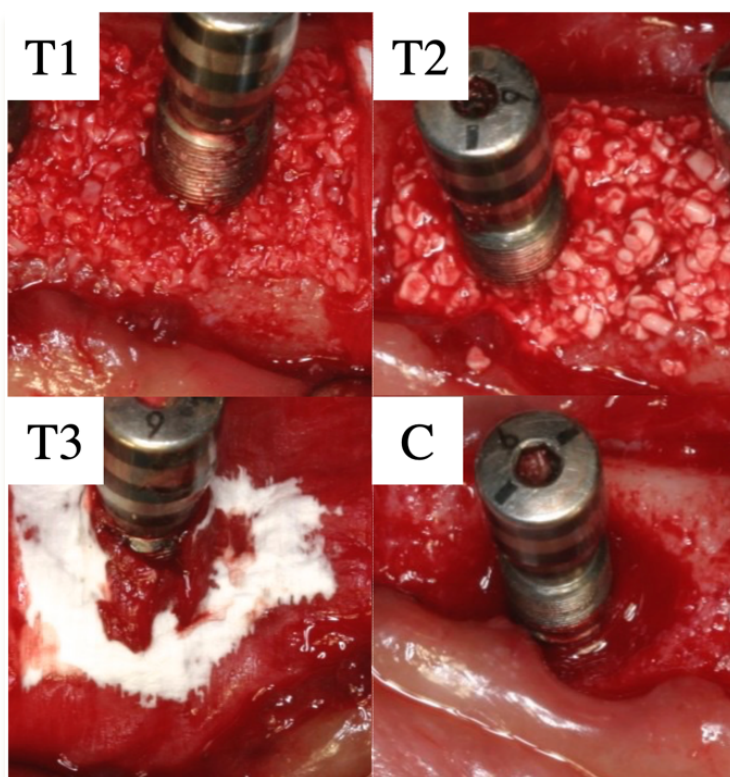
Four weeks after ligature removal, peri-implantitis surgery was performed in Study II, III and IV. Following elevation of full-thickness flaps and removal of inflamed connective tissue all implant sites were subjected to mechanical cleaning with curettes and cotton pellets soaked in saline. After that, four different treatment protocols were applied for each pair of implants (A and B) in each animal.

In Study II, additional local decontamination procedures were applied as follows: T1 (Test 1) received a chemical disinfection using deposition of citric acid gel on the exposed implant surface for 30 seconds followed by irrigation with saline, T2 (Test 2) received mechanical cleaning using a rotating titanium brush, T3 (Test 3) received a combination of mechanical and chemical treatment using the rotating titanium brush and deposition of citric acid gel on the exposed implant surface for 30 seconds followed by irrigation with saline and C (control) received no additional treatment (Fig. 9).



**Figure 9.** Photographs representing citric acid gel application (a) during surgical treatment and rotating titanium brush (b).

In Study III and IV, the peri-implantitis surgery was supplemented with different augmentation procedures as; T1 (Test 1); the bone defect was filled with deproteinized bovine bone mineral granules, T2 (Test 2); the bone defect was filled with a biphasic bone graft material, T3 (Test 3); the bone defect was filled with deproteinized bovine bone mineral granules and covered with a bio-resorbable type I/III collagen membrane and C (control); no augmentation material was added (Fig. 10). The mucoperiosteal flaps were repositioned and sutured around the healing abutments of all implants to allow a non-submerged healing. Two weeks later the sutures were removed and mechanical supra-mucosal infection control was reinstated. Furthermore, in Study III and IV, a fluorochrome (oxy-tetracycline, 25 mg/kg body weight, Engemycin Vet, Merck & Co., Inc.) was injected intravenously.



**Figure 10.** Photographs representing T1 (Test 1); bone defect filled with a deproteinized bovine bone mineral, T2 (Test 2); bone defect filled with a biphasic bone graft material, T3 (Test 3); bone defect filled with deproteinized bovine bone mineral granules and covered with a bio-resorbable type I/III collagen membrane and C (control); no augmentation.

## Histological preparation and analysis

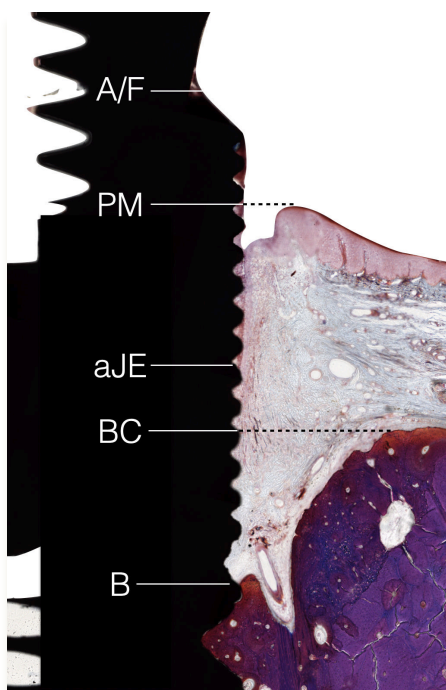
At the end of all experiments, the dogs were euthanized with a lethal dose of Sodium-Pentothal® (Hospira Enterprises B.V., Hoofddorp, Netherlands) and perfused through the carotid arteries with a fixative (4% formaldehyde). The mandibles were retrieved and 4 tissue blocks from each hemi-mandible containing the implant and the surrounding tissues were dissected using a diamond saw (Exakt®, Kulzer, Norderstedt, Germany) and stored in the fixative.

In Study I, two tissue blocks (one test and one control) from each side of the mandible were randomly selected to be processed for decalcified paraffin-embedded sections. The blocks were placed in ethylene-diamine-tetra-acetic acid (EDTA) and further processed using the fracture technique (Berglundh, Lindhe, Jonsson, & Ericsson, 1994). Following initial decalcification, incisions parallel with the long axis of the implant were made through the peri-implant tissues. Four segments, mesio-buccal, disto-buccal, mesio-lingual and disto-lingual were produced and then detached from the implant. Decalcification was continued using EDTA and the specimens were embedded in paraffin. Sections were produced with the microtome set at 5 µm. The sections were de-waxed and incubated in an antigen pre-treatment solution (Diva Decloaker, Biocare medical, Concord, CA, USA) at 60°C over night. Immunohistochemical preparation was made using antibodies for CD20, CD68, Myeloperoxidase (MPO) and CD3 using the DAKO EnVision + System-HRP (Agilent, Santa Clara, CA, USA). MPO-positive cells with a polymorphonuclear appearance indicated neutrophils, while markers for CD3, CD20 and CD68 indicated T cells, B cells and macrophages, respectively. The histological evaluation of cell markers was performed using a microscope equipped with an image system (Leitz DMRBE Q-500 MC® image system; Leica). Digital images were obtained using a PC-based image analysis system (Image-Pro Premier 9.3; Media Cybernetics Inc.). The ICT in each image was outlined using a mouse cursor. Cells with positive cell markers within the ICT were defined and identified using “smart segmentation” by a pixel classification algorithm. The area occupied by each positive cell category was measured, and the percentage of the entire ICT area was calculated.

The other tissue blocks from all experiments were prepared for ground sectioning. The blocks were dissected using a diamond saw (Exakt®, Kulzer, Germany). The ground sectioning was performed according to methods described by Donath and Breuner (1982). Tissue samples were dehydrated in ascending grades of ethanol and embedded in Technovit 7200 VLC-resin (Kulzer) and prepared as previously described (Albouy, Abrahamsson, & Berglundh, 2012) .

From each block four sections were produced. Two parallel sections were obtained in a mesio-distal and in a bucco-lingual plane. The sections were then reduced in thickness by microgrinding (Exakt, Apparatebau) to approximately 30  $\mu\text{m}$  and stained in toluidine blue and fibrin stain of Ladewig (Donath & Breuner, 1982).

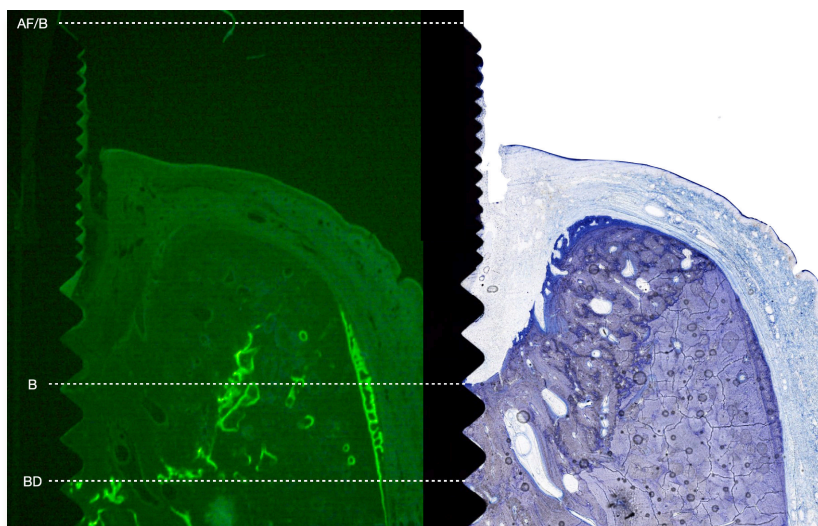
Histological analyses of ground sections were performed using a Leica DM-RBE microscope (Leica, Heidelberg, Germany) and a PC-based image analysis system (Image-Pro Premier, Media Cybernetics Inc.). The following landmarks were identified and used for the measurements: the marginal border of the peri-implant mucosa (PM), the apical termination of the barrier/junctional epithelium (aJE), the most coronal bone-to-implant contact (B), the most coronal position of the bone crest (BC), the abutment/fixture (implant) border (A/F). The landmarks were used to assess the linear distances PM-aJE, aJE-B and A/F-B (Fig. 11).



**Figure 11.** Photo of a buccal-lingual ground section indicating histological landmarks; A/F: the abutment/fixture junction, PM: the margin of the peri-implant mucosa, aJE: the apical termination of the barrier epithelium, BC: bone crest and B: the marginal level of bone to implant contact., Fibrin stain of Ladewig.

In Study II and III, persisting inflammation was assessed using ICT scores according to Carcuac et al. (2015). Thus, Score 0 indicated no or only scattered inflammatory cells identified in an area  $<1 \text{ mm}^2$ , while Score 1 indicated scattered inflammatory cells located in an area  $<2 \text{ mm}^2$ . Sites with Score 2 had clusters of inflammatory cells in infiltrates of a total area  $<3 \text{ mm}^2$ , while Score 3 was used in specimens with abundance of inflammatory cells in a total ICT area  $>3 \text{ mm}^2$ .

In Study III, the fluorochrome indicated the bottom (BD) and the lateral wall of the original bone defect (Fig. 12). Areas of the newly formed bone (B-BD-BC) and, when indicated, the residual intra-bony defect (defined by the bone wall between B and BC). Re-osseointegration was defined as newly formed bone in contact with the implant between BD and B. Further, the degree of bone-to-implant contact (BIC percentage) was assessed in the zone between B and BD and around the remaining portion of the implant apical of BD.



**Figure 12.** Micrographs including a fluorochrome marker and corresponding ground section indicating the bottom (BD) and the lateral wall of the original bone defect, the marginal level of bone to implant contact (B), and the abutment/ fixture junction (AF).




## Data analysis

Analyses of continuous variables were reported as mean values  $\pm$  standard deviation (SD). Bivariate analyses were performed using ANOVA and Student's t test for paired samples. Regression analysis was used to identify parameters affecting the dependent variables: radiographic bone level, mucosal margin alterations following surgical therapy of peri-implantitis and histological dimensions.

The following independent variables were evaluated: implant (A-B), treatment modality (T1, T2, T3 and C). The distribution of outcome variables was explored, and models were constructed considering the dog and the implant as potential levels. In Study II, ordered probit regression model was used to explore the differences in ICT scores between different treatment modality (T1, T2, T3 and C) and implant (A-B). The animal was used as the statistical unit (n=6).

In Study IV, bivariate correlation analyses were made between MBL data obtained from (a) histological sections and corresponding CBCT images, (b) CBCT images and corresponding PA radiographs and (c) PA radiographs and corresponding histological sections (Fig. 13). Correlations were tested and Bland-Altman plots were applied to evaluate the agreement between MBL assessments obtained from (a) histological sections and CBCT images, (b) CBCT images and PA radiographs, (c) PA radiographs and histological sections. The SPSS 24.0 software package (SPSS Inc., Chicago, Illinois, USA), Stata (Statistical Software: Release 16; StataCorp LLC) and GraphPad Prism version 8.3.1 (GraphPad Software, San Diego, California USA) were used.



**Figure 13.** Implant site documented by a CBCT image (a), PA radiograph (b) and histological section (c). A/F: abutment /fixture (implant) border, B: the most coronal bone-to-implant contact.





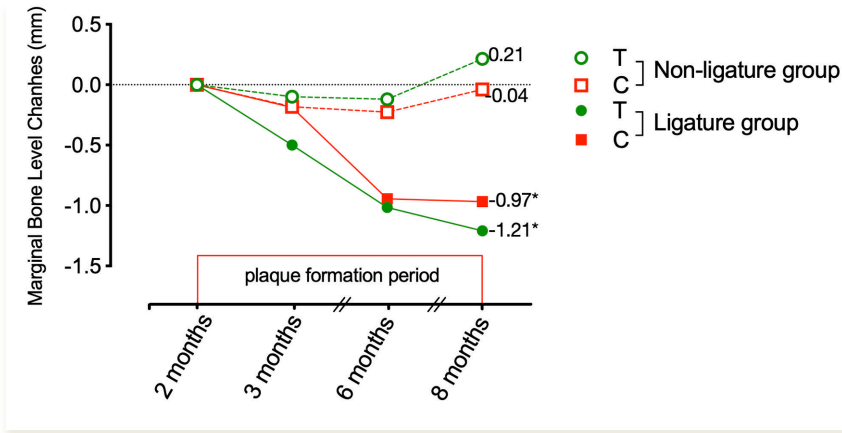
# Results

In all experiments, healing after implant placement was uneventful except for two implants in one animal of experiment I (one test and one control implant, both in the non-ligature group) demonstrating post-operative infection and early bone loss. Those implants were excluded from the analysis. After the biofilm formation period in experiment I, all implant sites showed clinical signs of inflammation in the peri-implant mucosa. In experiments II and III, however, the peri-implant mucosae demonstrated absence or only minor clinical signs of inflammation following surgical treatment of the experimental peri-implantitis until the end of the experiments.

# Study I: Biofilm formation on implant abutments with an antibacterial coating

## Radiological bone level alteration

During the biofilm formation period (from 2 months to 8 months, Fig. 14), bone loss occurred around the majority of implants. The amount of bone loss that occurred during the plaque accumulation period was significantly larger in the ligature group than in the non-ligature group  $-1.09 \pm 1.06$  and  $0.13 \pm 0.48$  mm, respectively. The amount of bone loss (mean  $\pm$  SD) during the same period around test and control abutment sites in the ligature group were  $-1.21 \pm 1.19$  and  $-0.97 \pm 0.95$  mm, respectively. The amount of bone level alteration (mean  $\pm$  SD) around test and control abutment sites in the non-ligature group was smaller and amounted to  $0.21 \pm 0.41$  and  $-0.04 \pm 0.65$  mm, respectively. The differences regarding bone loss between test and control abutment sites within the ligature and the non-ligature groups were not statistically significant.



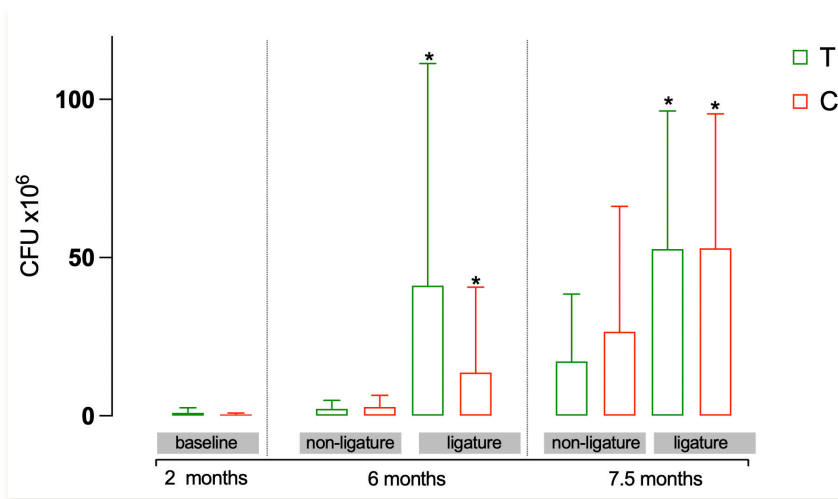
**Figure 14.** Radiographic bone level alterations (mm) during disease progression period.

\*Indicates  $p < 0.05$  between ligature and non-ligature groups at 8 months.

## Microbiological findings

### Culturing technique

The results from the microbiological evaluation using the culturing technique are presented in Fig. 15. Significantly larger bacterial growth around implants in the ligature group than in the non-ligature group at 6 and 7.5 months were detected. The differences between samples from test and control abutment sites were not statistically significant.

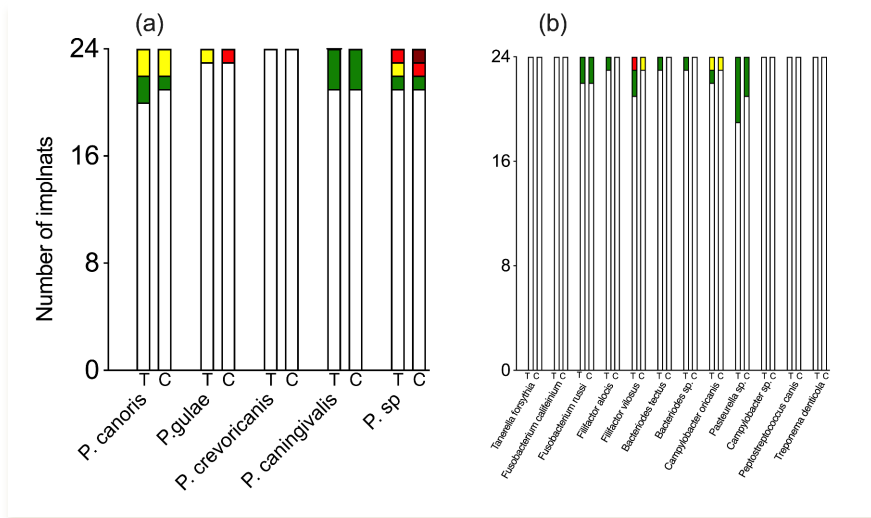


**Figure 15.** Microbiological results from the evaluations made on samples using culturing technique at 2 months after abutment connection (baseline), 6 months and 7.5 months for both type of abutments (T and C) of the non-ligature and ligature groups.

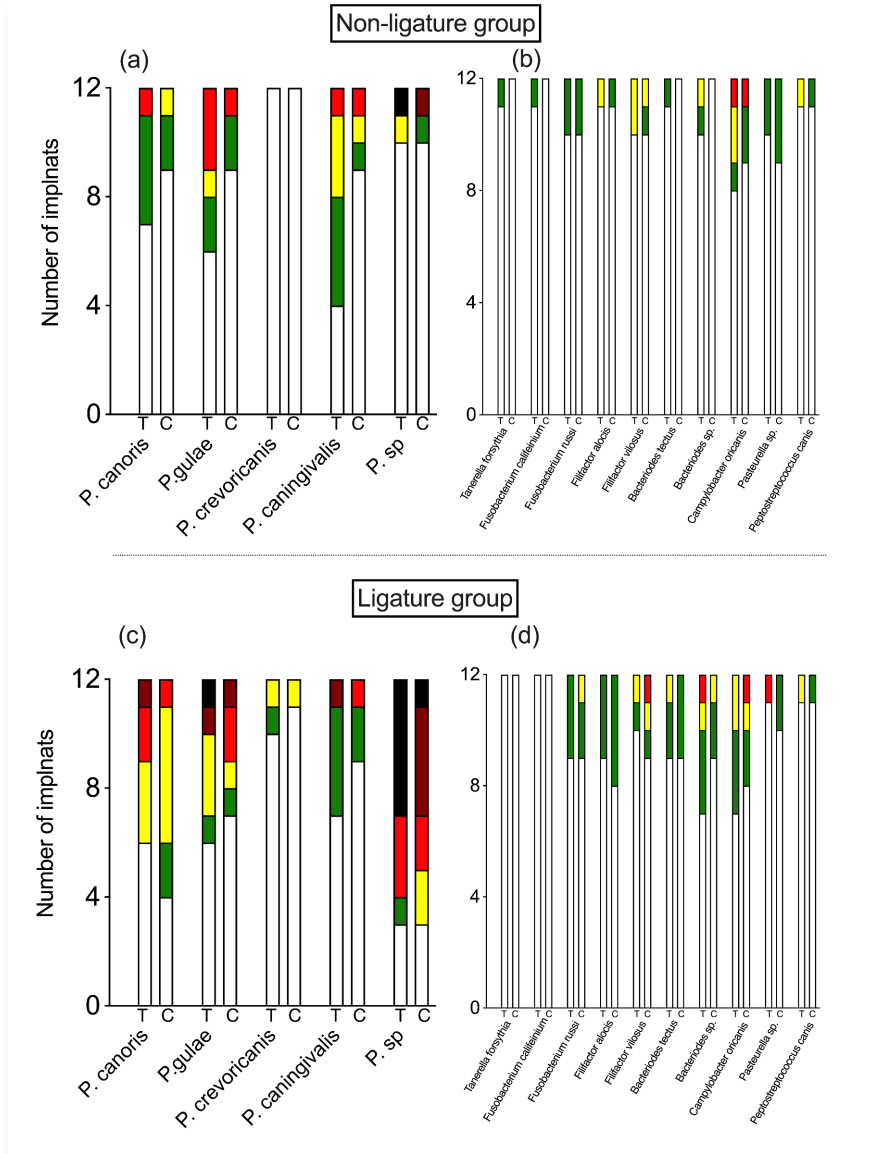
\*Indicates  $p < 0.05$  between ligature and non-ligature groups at 6 and 7.5 months

## Checkerboard technique

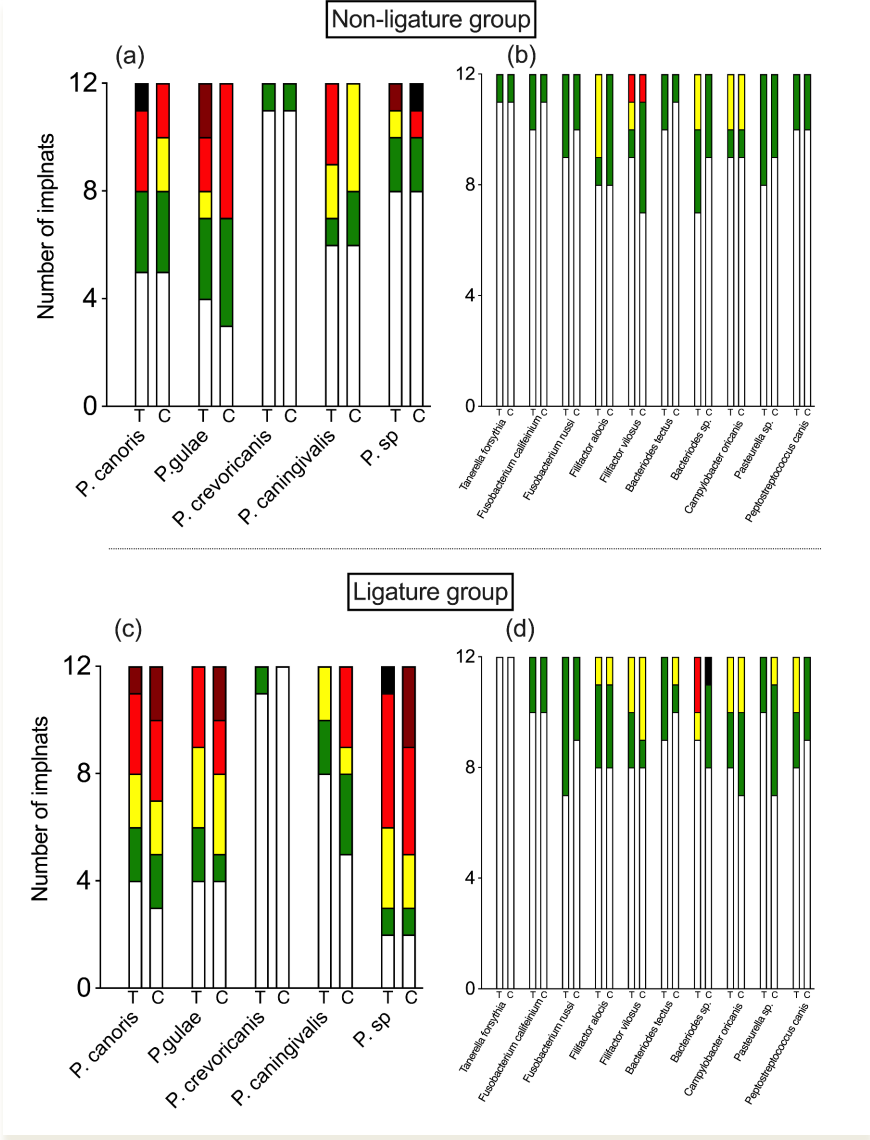
The results from the microbiological analysis using the DNA–DNA hybridization checkerboard technique is presented in Figs. 16 - 18. *Campylobacter* species and *Treponema denticola* were not detected at any time point while the remaining 15 species were detected during the course of the experiment around the implants. From baseline to the last microbiological evaluation, the number of implants that were positive to DNA probes increased with time. This increase was higher at implants in the ligature group than in the non-ligature group. There were no statistically significant differences between the ligature and the non-ligature implant groups or between test and control abutment sites at any time point during the course of the experiment.



**Figure 16.** Microbiological findings from the samples at baseline processed with DNA probes of Porphyromonas species (a) and other different types of bacteria (b) obtained from both types of abutments (T and C). Score 0 = no reaction (white),  $1 < 10^5$  (green),  $2 = 10^5$  (yellow),  $3 > 10^5$  (red),  $4 = 10^6$  (brown) and  $5 > 10^6$  (black).



**Figure 17.** Microbiological findings from the samples at 6 months processed with DNA probes of *Porphyromonas* species (a and c) and other different types of bacteria (b and d) obtained from both types of abutments (T and C). Score 0 = no reaction (white), 1 < 10<sup>5</sup> (green), 2 = 10<sup>5</sup> (yellow), 3 > 10<sup>5</sup> (red), 4 = 10<sup>6</sup> (brown) and 5 > 10<sup>6</sup> (black).



**Figure 18.** Microbiological findings from the samples at 7.5 months processed with DNA probes of *Porphyromonas* species (a and c) and other different types of bacteria (b and d) obtained from both types of abutments (T and C). Score 0 = no reaction (white),  $1 < 10^5$  (green),  $2 = 10^5$  (yellow),  $3 > 10^5$  (red),  $4 = 10^6$  (brown) and  $5 > 10^6$  (black).

## Histological findings

The results from the histometric measurements made in the ground sections are reported in Table 2 of Paper I. The size of the infiltrated connective tissue area around implants of the ligature and the non-ligature groups was  $0.69 \pm 0.63$  and  $0.25 \pm 0.31 \text{ mm}^2$ , respectively. Differences in vertical distances (PM-aJE, aJE-B, A/F-B and PM-aBiofilm) between test and control sites in the ligature and non-ligature groups were small and not statistically significant.

The histological findings from the immunohistochemical analyses of the paraffin-embedded sections using different markers from the non-ligature group are presented in Table 3 of Paper I. The size of the ICT at control and test abutments was  $0.56 \pm 0.51$  and  $0.21 \pm 0.12 \text{ mm}^2$ , respectively. The difference between control and test abutments did not reach a significant level. CD3 and MPO-positive cells in the ICT occupied an area corresponding to  $4.73 \pm 1.12$  and  $2.93 \pm 2.46$  % of the ICTs, respectively. At the control sites CD3 and MPO-positive cells occupied  $5.65 \pm 1.59$  and  $4.67 \pm 3.31$  %, respectively. The difference in the CD3 and MPO-positive cells between control and test abutments did not reach a significant level.

## **Study II: Treatment using different mechanical and chemical procedures**

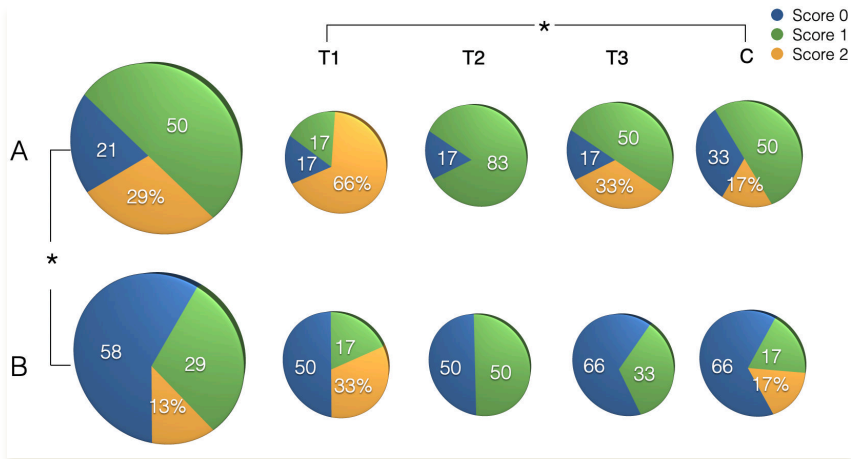
### Radiological bone level alteration

The mean radiological bone level alterations following surgical treatment at implants A and B were  $0.63 \pm 0.92$  and  $0.65 \pm 0.67$  mm, respectively. No significant differences in bone level alterations between implant types or treatment groups were found.

## Histological findings

The results from ICT score assessments are presented in Figure 19. Within the same implant type, no test treatment showed significantly better outcome compared to the control treatment. Score 0 was found in 21 % and 58 % of A and B implant sites, respectively. Score 1 was found in 50 % and in 29 % of A and B implant sites, respectively. Score 2 was found in 29 % and in 13 % of A and B implant sites, respectively. No implant had Score 3.

Ordered probit regression analysis showed that the difference in ICT scores between both types of implants was statically significant ( $p < 0.05$ ). The ICT scores were significantly higher in T1 (Citric acid) compared to C (Control) group ( $p < 0.05$ ) (Figure 19).



**Figure 19.** ICT scores for different treatment categories at implant types A and B; T1 ( Citric acid), T2 (Titanium brush), T3 (Citric acid+ Titanium brush), and C (control). Score 0: no or only scattered inflammatory cells identified in an area  $< 1 \text{ mm}^2$ , Score 1: scattered inflammatory cells located in an area  $< 2 \text{ mm}^2$ , Score 2: clusters of inflammatory cells in infiltrates of a total area  $< 3 \text{ mm}^2$   
 $*p < 0.05$  between ICT score of T1 and C independent of implant type

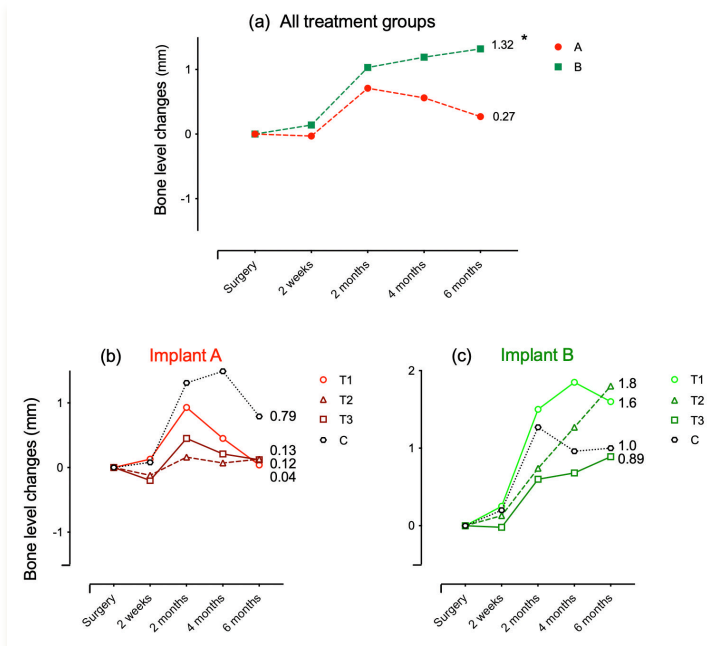


Results from the histometric measurements representing T1, T2, T3 and C procedures for implant type A and B are presented in Paper II (Table 2). Within the same implant type, no statistically significant differences were found between treatment groups. A regression model, however, revealed that the PM-aJE distance was significantly longer at A implants compared to B implants irrespective of treatment group ( $p < 0.05$ ). The mean AF-B distance at implants A and B were  $4.56 \pm 1.75$  and  $4.28 \pm 1.23$  mm, respectively. No statistically significant differences were found between treatment groups or implant types.

## **Study III: Treatment with different reconstructive procedures**

### **Radiological bone level alterations**

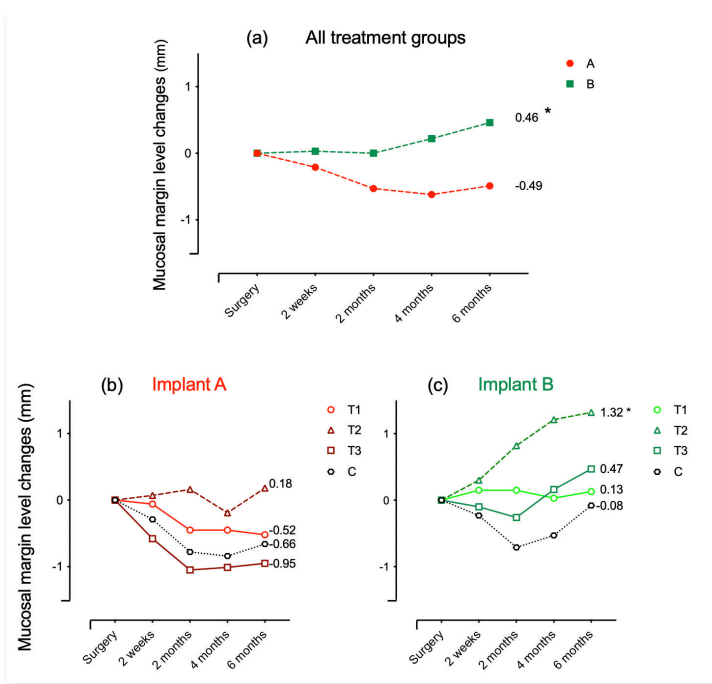
The results from the radiological measurements are presented in Fig. 20. The amount of bone loss that occurred during the period of ligature-induced breakdown at A and B implants were  $4.66 \pm 0.62$  and  $4.64 \pm 0.76$  mm, respectively. The amount of bone gain following surgical therapy around implants A and B were  $0.27 \pm 1.76$  and  $1.32 \pm 0.69$  mm, respectively. The regression analysis revealed that bone level gain was significantly larger at B than A implants. The amount of bone gain around implant A following T1 (Bio-Oss), T2 (Symbios), T3 (Bio-Oss + BioGide), and C (control) treatment was  $0.04 \pm 1.74$ ,  $0.13 \pm 2.44$ ,  $0.12 \pm 1.81$  and  $0.79 \pm 1.18$  mm, respectively. The corresponding amount of bone gain around implant B following treatment T1, T2, T3, and C was  $1.60 \pm 0.39$ ,  $1.80 \pm 0.58$ ,  $0.89 \pm 0.66$  and  $1.00 \pm 0.45$  mm, respectively. No statistically significant differences in bone level changes were found between treatment groups among type A and type B implants.



**Figure 20.** Bone level changes in radiographs (mm) following surgical treatment for implants A (red) and B (green) (a) and different treatment groups among implant A and B sites (b and c). T1 (Bio-Oss), T2 (Sym-bios), T3 (Bio-Oss + BioGide), and C (control). \*indicates  $p < 0.05$  implant A versus B

## Mucosal margin alterations

Data on alterations of the mucosal margin that occurred following reconstructive surgical treatment are presented in Fig. 21. The mean mid-facial mucosal margin alterations for implants A and B were  $-0.49 \pm 1.19$  and  $0.46 \pm 0.82$  mm, respectively. These findings indicated on average a recession of the mucosal margin for A implants and a coronal migration after surgical therapy for B implants. The difference between A and B implants was statistically significant. Regarding different treatments, no statistically significant differences were found between treatment groups among A implants. For B implants, linear regression analysis revealed that the treatment group T2 showed significant coronal migration of the mucosal margin than the C group ( $p < 0.05$ ).

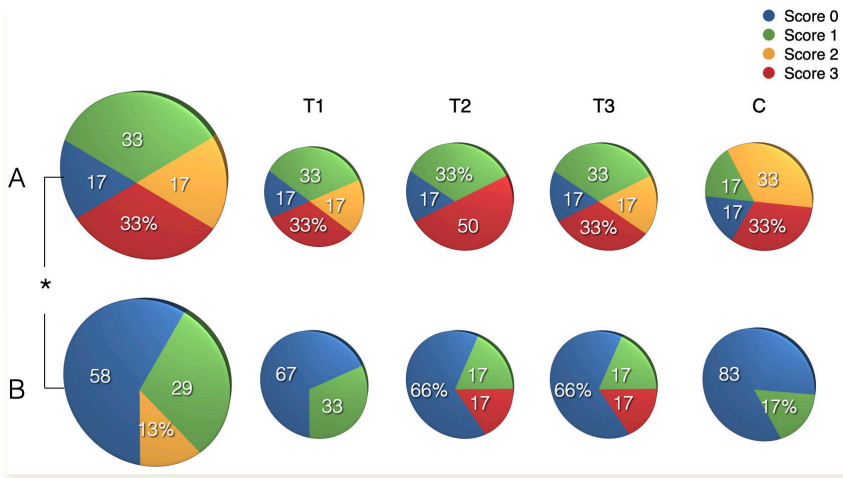


**Figure 21.** Mucosal margin level changes (mm) following reconstructive surgical treatment for implants A (red) and B (green) (a) and different treatment groups among implant A and B sites (b and c). T1 (Bio-Oss), T2 (Symbios), T3 (Bio-Oss + BioGide), and C (control).

\* indicates  $p < 0.05$  between T2 and C

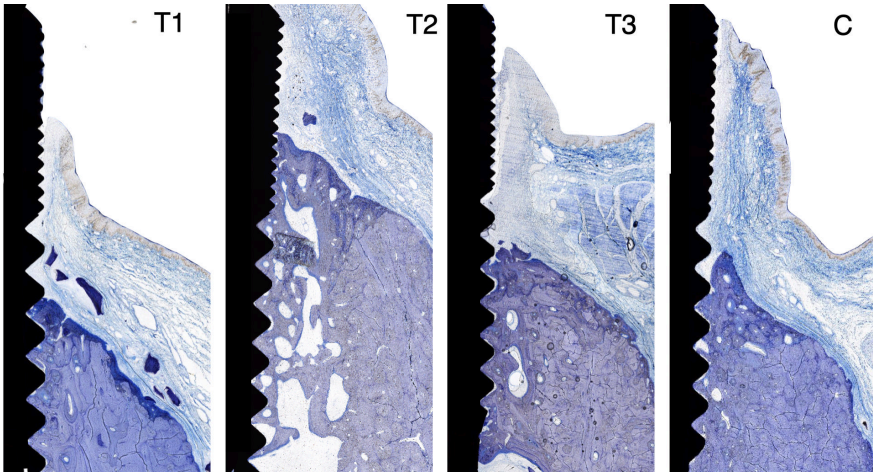
## Histological findings

The results from the ICT scores assessments are presented in Fig. 22. Scores 0 and 1 were found more frequent on B implant sites than A implant sites. This difference in score distribution between A and B implants was statistically significant. No significant differences were found between treatment groups.



**Figure 22.** ICT scores for different treatment categories at implant types A and B; T1 (Bio-Oss), T2 (Sym-bios), T3 (Bio-Oss + BioGide), and C (control). Score 0: no or only scattered inflammatory cells identified in an area <math>< 1 \text{ mm}^2</math>, Score 1: scattered inflammatory cells located in an area <math>< 2 \text{ mm}^2</math>, Score 2: clusters of inflammatory cells in infiltrates of a total area <math>< 3 \text{ mm}^2</math>, Score 3: abundance of inflammatory cells in a total ICT area <math>> 3 \text{ mm}^2</math>

Micrographs of ground sections representing implants at control and test treatment sites are presented in Fig. 23. The results from the assessments of defect fill and re-osseointegration are presented in Paper III (Table 1). About 54% of A implants showed newly formed bone and defect fill following the treatment. The corresponding percentage on B implants was 96%. Binary logistic regression analysis showed an odds ratio of 25.5 for B as opposed to A implants to exhibit bone fill. The amount of defect fill, when occurring, was about 3.0 mm<sup>2</sup> for both A and B implants.



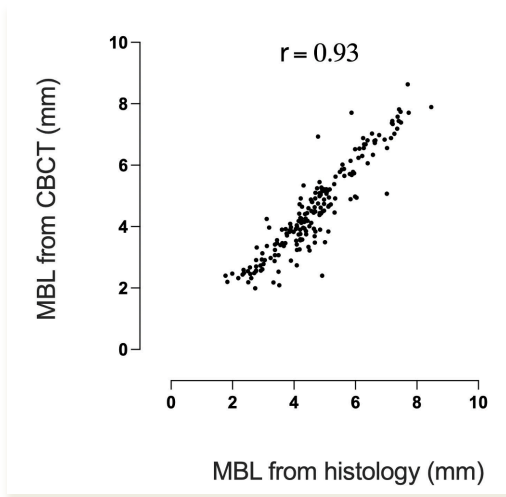
*Figure 23. Micrographs of ground sections representing the different treatment categories; T1 (Bio-Oss), T2 (Symbios), T3 (Bio-Oss + BioGide) and C (control).*

The results from the measurements of soft tissue dimensions are reported in Paper III (Table 3). The PM-aJE distance was  $3.17 \pm 1.53$  mm at A implants and  $1.84 \pm 0.47$  mm at B implants. The aJE-B distance was  $1.56 \pm 0.49$  and  $2.73 \pm 0.64$  mm at A and B implants, respectively. The differences in soft tissue dimensions between A and B implants were statistically significant.

## Study IV: Comparison between peri-implant bone level assessments using different methods

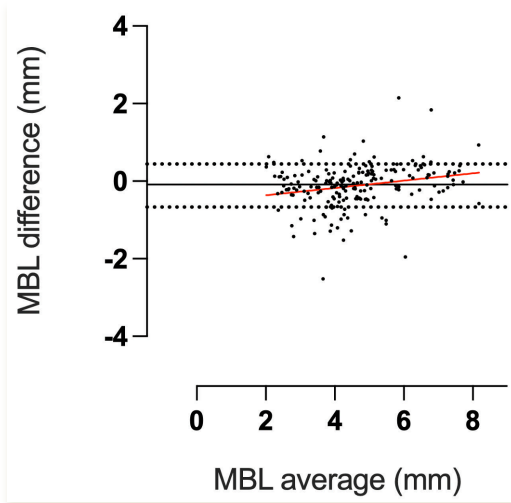
### Cone beam computed tomography vs. histology

Correlations between MBL-data obtained from measurements on histological sections and corresponding CBCT images are illustrated in Figure 24. Pearson correlation coefficients ( $r$ ) was 0.93. This correlation was statistically significant ( $p < 0.05$ ).



**Figure 24.** Plots illustrating correlations between MBL-data obtained from histological sections (X axis) and corresponding CBCT images (Y axis).

Plot diagram illustrating differences in data between histological sections and corresponding CBCT images is presented in Figure 25. The mean differences in MBL data between histological sections and corresponding CBCT images at mesial, distal, buccal and lingual aspects was  $-0.12 \pm 0.56$ . A simple linear regression analysis did not reveal any significant trend for differences of MBL assessments over different bone levels (Figure 25).



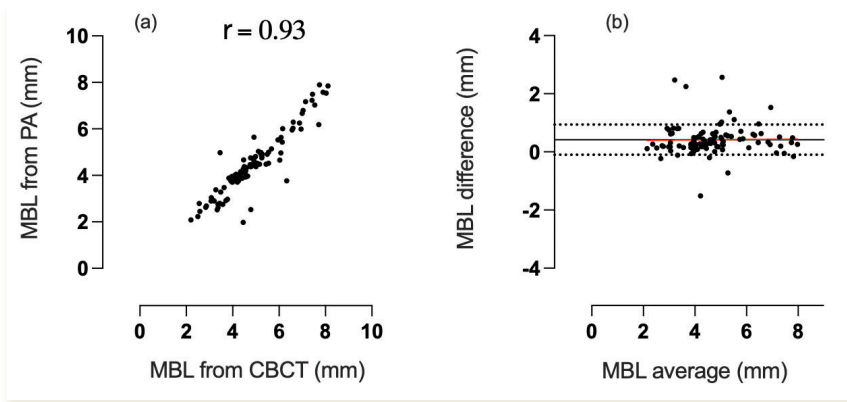
**Figure 25.** Bland-Altman plots representing the average of MBL data (X axis) and the difference in data (Y axis) between histological sections and corresponding CBCT images at (a) mesial, (b) distal, (c) buccal and (d) lingual aspects. Mean (black line), standard deviation (dotted lines) and simple linear regression (red line) of differences.

The mean differences between histological data and corresponding CBCT data for treatment categories C, T1, T2 and T3 were  $-0.31 \pm 0.56$ ,  $-0.13 \pm 0.74$ ,  $-0.06 \pm 0.48$  and  $0.02 \pm 0.35$  mm, respectively. No statistically significant differences were detected between the two methods.

The mean MBL discrepancy between interproximal and bucco-lingual sites assessed on CBCT images was  $0.12 \pm 0.26$  mm. The corresponding discrepancy assessed on histological sections was  $0.01 \pm 0.01$  mm.

## Cone beam computed tomography vs. periapical radiographs

Correlation between MBL assessments on PA radiographs and maximum MBL in corresponding CBCT images is illustrated in Figure 26a. Pearson correlation coefficients ( $r$ ) was 0.93. This correlation was a statistically significant ( $p < 0.05$ ). The mean differences between MBL in PA radiographs and maximum MBL in corresponding CBCT images at mesial and distal aspects was  $0.42 \pm 0.53$ . A simple linear regression analysis did not reveal a significant trend for differences of MBL assessments over different bone levels (Figure 26b).



**Figure 26a:** Plots illustrating correlations between maximum MBL from CBCT images (X axis) and MBL-data obtained from PA radiographs (Y axis). **Figure 26b:** Bland-Altman plots representing the average of MBL data (X axis) and the difference in data (Y axis) between PA radiographs and maximum MBL in CBCT images. Mean (black line), standard deviation (dotted lines) and simple linear regression (red line) of differences.

## Periapical radiographs vs. histology

The mean differences in the marginal bone level data between histological sections and corresponding PA radiographs at mesial and distal aspects were  $-0.13 \pm 0.58$  and  $-0.28 \pm 0.56$  mm, respectively. A simple linear regression analysis did not reveal any significant trend for differences of MBL assessments over different bone levels. Pearson correlation coefficients ( $r$ ) between histological sections and corresponding PA radiographs were 0.92. This correlation was a statistically significant ( $p < 0.05$ ).



# Main Findings

- Plaque formation combined with a short-term use of ligatures resulted in more peri-implant disease progression than plaque formation without ligatures (*Study I*).
- Dental abutments coated with Ga-Bi-Ti failed to prevent biofilm formation and did not influence the inflammatory process in the adjacent peri-implant mucosa. (*Study I*)
- Disease resolution of experimental peri-implantitis can be achieved after surgical therapy using gauze soaked in saline as an implant-surface decontamination method. Other local decontamination procedures did not show any superior results in term of disease resolution. (*Study II and III*)
- Healing following surgical treatment of experimental peri-implantitis was superior around implants with a smooth surface than at implants with rougher surfaces. (*Study II and III*)
- Re-osseointegration following surgical treatment of experimental peri-implantitis can be achieved with or without reconstructive procedures including bone substitute materials. (*Study III*)
- The additional effect on re-osseointegration and bone fill of using bone substitute biomaterials during surgical treatment of experimental peri-implantitis was small. (*Study III*)
- Significant correlations were observed between assessments of marginal bone levels using either on cone beam computed tomography, intra-oral periapical radiographs or histology. Measurements in periapical radiographs consistently resulted in an overestimation of the bone level of about 0.3 - 0.4 mm. (*Study IV*)
- The discrepancy of bone levels around dental implants between interproximal and bucco-lingual sites following reconstructive treatment of peri-implantitis was small. (*Study IV*)



# Concluding remarks

## Experimental peri-implantitis models

The ligature-induced experimental peri-implant disease model was inherited from a previous model to induce periodontitis around teeth (Lindhe & Ericsson, 1978). The concept with the use of ligatures is to open the mucosal seal, allowing plaque accumulation in the peri-implant sulcus and thus, to initiate an inflammatory reaction in the peri-implant tissue. The effect of plaque accumulation after ligature placement was first evaluated in a rat model (Rovin, Costich, & Gordon, 1966). Ligatures were placed in the gingival margin of first molars in conventional and germfree rats. Two to ten folds higher inflammatory infiltration was demonstrated in the periodontal area of conventional than of germfree rats. Thus, the same concept was further developed in the dog model around teeth and dental implants (Lindhe et al., 1992). The technique in the dog model is to gently introduce the ligature in a sub-marginal position of the mucosal pocket (Lindhe et al., 1992). At the same time, plaque control measures are abandoned. Historically, different types of ligatures have been used in the model (Lindhe et al., 1992; Wetzel et al., 1999). The effect of different types of ligatures, however, has not been compared within the same experimental peri-implantitis model.

The disease progression in the experimental peri-implantitis model is controlled and monitored by clinical and radiographical examinations (Albouy et al., 2011; Carcuac et al., 2015). Thus, according to the goal of the experiment and aiming at keeping the mucosal seal open, the ligatures in Study II and III of the present series were replaced every 3rd week during the (active) disease induction period. At every ligature replacement, the ligatures were placed in a more apical position compared to the previous ligature position. When the desired amount of peri-implant destruction (about 40-50% of bone loss) was detected, the ligatures were removed.

The main goal of Study II and III was to evaluate different protocols for treatment of experimental peri-implantitis and, hence, the ligature induced peri-implantitis model was used. In previous publications, the number of ligature replacements varied between experiments depending on whether the aim was to evaluate disease progression or to perform surgical therapy (Table 1). Recently, Carcuac et al. (2020) introduced a modified short term (one month) use of liga-

ture without replacement to evaluate the progression of peri-implant disease around implants with different surface characteristics placed in augmented and pristine sites. It was demonstrated that following the short-term disruption of the soft tissue barrier (one month), spontaneous progression and bone loss occurred after the removal of ligatures. The design of the study by Carcuac et al. (2020) did not include sites where no ligatures were used. Hence, by the design of the 1<sup>st</sup> experiment of this thesis (Study I) the aim was to evaluate the validity of the model with short-term use of ligature-induced experimental peri-implantitis. Thus, in Study I, the model with short-term disruption of the barrier tissue around the implants in one side of the mandible, was used. The other side of the mandible served as control during the plaque formation period. After six months of plaque formation, more bone loss and a larger inflammatory response was detected in the peri-implant tissues of the ligature group than the non-ligature group. This finding validates that the single use of ligatures for a short period may initiate a spontaneously progressing peri-implantitis lesion.

## **Prevention of peri-implant diseases**

Peri-implant diseases include peri-implant mucositis and peri-implantitis. Peri-implant mucositis is an inflammatory lesion in the soft tissues surrounding a dental implant without loss of supporting bone, while peri-implantitis is a more advanced condition that is characterized by inflammation in the peri-implant mucosa and in addition subsequent progressive loss of peri-implant bone ( Berglundh et al., 2018a; Heitz-Mayfield & Salvi, 2018; Schwarz et al., 2018). Clinical data have shown that patients with peri-implant mucositis may develop peri-implantitis, especially in the absence of maintenance care (Costa et al., 2012). Thus, providing maintenance care may prevent the occurrence and progression of peri-implantitis. In addition, mechanical self-performed plaque control would promote maintenance of healthy peri-implant tissues (Costa et al., 2012; Heitz-Mayfield et al., 2018; Salvi & Ramseier, 2015; Salvi & Zitzmann, 2014).

As previously discussed, peri-implant diseases are initiated by an accumulation of biofilm around the dental implant. Thus, producing dental implant units that contain anti-bacterial properties might be beneficial in peri-implant disease prevention. The concept of producing implant units that carry anti-bacterial proper-

ties has previously been investigated (Cochis et al., 2015; 2016; Lin et al., 2013; Zeller et al., 2020). The idea started by using either physical or chemical coatings with materials that have anti-bacterial effects. Physical coatings can be achieved by using the Physical Vapor Deposition (PVD) technique. By vaporizing inorganic materials in a high-vacuum chamber dental implants can be provided with coatings intended to prevent bacterial adhesion and colonization (Brohede et al., 2009).

Provided that bacterial accumulation around dental implant units can be prevented or delayed, biological complications might subsequently be prevented. The concept of a dental implant material with antibacterial properties was first evaluated in *in-vitro* (Cochis et al., 2015; Nagay et al., 2019; Zeller et al., 2020). Zeller et al. (2020) studied plaque formation on discs of metal alloys (gold or silver), zirconia (Zr) and polyetherketoneketone (PEKK). The discs were mounted in customized appliances that were worn intra-orally by volunteers for 24 hours. Less plaque formation on discs made of either gold- or silver-based alloys than discs produced from Zr, PEKK or titanium-zirconium alloy was reported (Zeller et al., 2020). Moreover, antibacterial effects of silver were evaluated in different experimental settings. Silver-containing alloys and coatings consisting of titanium together with either gallium or bismuth showed antibacterial effects (Cochis et al., 2015; 2016; Lin et al., 2013; Nagay et al., 2019). Cochis et al. (2015) investigated the anti-bacterial properties of c.p. titanium discs coated with gallium. Using a dental splint, the discs were kept in the mouth for 24 hours. The discs were then incubated for 72 hours. A reduction of the bacterial viability was detected when compared to uncoated c.p. titanium discs.

The possibility of producing dental implant materials that to some extent might prevent bacterial growth seems to be valid (Cochis et al., 2016; Lin et al., 2013; Nagay et al., 2019). In the aforementioned investigations, however, the antibacterial effect was evaluated in models that did not mimic the challenging conditions that dental implants are exposed to in clinical use. Although the model showed a short-term antibacterial effect, the relatively long-term effect was not investigated (Zeller et al., 2020). Moreover, the dynamic condition of the bacterial challenges in the oral environment was not investigated. Thus, the animal model can be used to evaluate effects over a relatively longer time. In this context, several *in-vivo* investigations have evaluated the antibacterial effect of dental implant materials (Godoy-Gallardo et al., 2016; López-Piriz et al., 2015; Martinez et al., 2014). Martinez et al. (2014) evaluated the influence of implant abutments coated with soda-lime glass containing silver nanoparticles in a dog model with ligature-induced experimental peri-implantitis. From the histological

evaluation, the authors reported less bone loss around implants with the antibacterial coating than control implants. In a similar model, López-Píriz et al. (2015) used zirconia implant abutments with three different antibacterial glassy coatings and one uncoated zirconia abutment as control. Based on radiological evaluation, bone level changes indicated that implants with coated abutments showed less bone loss than uncoated (control) abutments. Moreover, the evaluation of bone level changes at the different abutment types was limited to active disease induction periods i.e. no spontaneous progression period was allowed. Godoy-Gallardo et al. (2016) also used a similar ligature-induced experimental peri-implantitis model, but with two additional months of spontaneous progression. Radiological analysis demonstrated that the majority of bone loss occurred during the “active” period of ligature induced peri-implantitis. The antibacterial effect of implant abutments, however, was not evaluated without the use of ligatures. In Study I of this thesis, the design of the model comprised one group of implants with a short-term ligature induced peri-implantitis period followed by a spontaneous progression period and one implant group without ligatures but with plaque formation. The radiological bone level assessments in Study I revealed a significant difference between the ligature and non-ligature groups, while no such difference was detected between test and control abutments.

In Study I, qualitative and quantitative microbiological evaluations were reported from test and control abutment sites at baseline (abutment connection), 6 months and 7.5 months. The longitudinal assessments of the microbiological samples did not reveal any significant differences between test and control sites at any time point. The coated abutments failed to demonstrate any antimicrobial effect on bacterial growth during the course of the experiment. This finding is in contrast with aforementioned reports from *in-vitro* studies. The relatively long follow up time in Study I may be the main difference to explain why no sustained antimicrobial effect was demonstrated. The antimicrobial effect of the coated abutment might have faded-away with time, or the biofilm accumulation may by time have covered the abutment surface and blocked the antimicrobial effect.

Up to present, however, we know that the prevention of peri-implant diseases can be achieved by providing self-performed oral hygiene measures around dental implants with a personalized professional supportive therapy (Costa et al., 2012; Heitz-Mayfield et al., 2018; Salvi & Ramseier, 2015; Salvi & Zitzmann, 2014). Nevertheless, implant units exhibiting antimicrobial effects may be considered if their antimicrobial properties stays over time and prevents the occurrence of peri-implant diseases.

## **Implant surface decontamination**

In the literature, different decontamination procedures have been evaluated for treatment of experimental peri-implantitis in different *in-vivo* settings (Table 2.). No single surface decontamination procedure has shown superior outcomes in terms of disease resolution compared to control treatments (gauze soaked in saline). Thus, it was suggested that the simplest treatment (control) should be applied (Carcuac et al., 2015; Htet et al., 2016; Persson et al., 1999; Schou, Holmstrup, Jørgensen, Skovgaard, Stoltze, Hjørting-Hansen, & Wenzel, 2003b). Carcuac et al. (2015) evaluated surgical treatment of experimental peri-implantitis using different anti-infective procedures (chlorhexidine vs. saline). It was found that chlorhexidine provided a limited additional effect compared to saline as a local decontamination agent. On the other hand, Htet et al. (2016) in a pre-clinical study used four local decontamination procedures. Erbium doped:yttrium, aluminum (Er:YAG) laser, gallium aluminum arsenide diode laser, titanium brush alone or titanium brush in combination with citric acid solution soaked in a cotton pellet were used for local decontamination. Based on bone histometric findings it was concluded that the combination of local decontamination using titanium brush with citric acid solution was the most effective treatment procedure. Htet et al. (2016), however, did not include any control treatment as a reference. The data from Study II and III in the present series revealed that disease resolution and re-osseointegration can be achieved following surgical treatment using only gauze soaked in saline for surface decontamination. Moreover, different mechanical, chemical or combination procedures did not demonstrate better results regarding resolution of peri-implantitis lesions compared to the control (saline) group.

## **Impact of implant surface on healing following treatment of peri-implantitis**

Healing following surgical treatment of experimental peri-implantitis around implants with different surface characteristics was investigated in several experiments (Albouy et al., 2011; Carcuac et al., 2015; Persson, Berglundh, Lindhe, & Sennerby, 2001a; Wetzel et al., 1999). The earlier studies focused mainly on bone healing and re-osseointegration (Wetzel et al., 1999; Persson et al., 2001).

It was demonstrated that the re-osseointegration following surgical therapy was possible. Studies by Wetzel et al. (1999) and Persson et al. (2001) did not report on disease resolution following surgical treatment. Albouy et al. (2011), however, assessed disease resolution following surgical treatment of experimental peri-implantitis at implants with different surface characteristics. The data by Albouy et al. (2011) revealed that the size of a remaining ICT differed between implants with different surface characteristics, favoring implants with smooth surfaces. In the same context, Carcuac et al. (2015) investigated healing around implants with different surface characteristics. It was again concluded that resolution of inflammation was influenced by implant surface characteristics (Carcuac et al., 2015).

In Study II and III, healing and re-osseointegration was investigated following surgical treatment of experimental peri-implantitis around implants with different surface characteristics. While re-osseointegration was found to be more frequent around implants with a smooth surface than at implants with a modified surface, the amount of newly formed bone, when occurring, was not significantly different between implant types. The healing was, however, significantly superior around smooth surface implants than moderately rough surface implants. This finding confirmed the previous observations by Albouy et al. (2011) and Carcuac et al. (2015). In a randomized, controlled clinical study by Carcuac et al. (2016) aiming at treatment of severe peri-implantitis, the proportion of successful treatment outcome after one year was higher at implants with a turned surface compared to implants with a modified surface. The inferior outcomes in terms of disease resolution (health) around modified surfaces following surgical treatment of peri-implantitis was also reported in a long-term follow-up study by Berglundh et al. (2018b). In addition, Carcuac et al. (2020) when reporting on 5-year data following surgical therapy of peri-implantitis, concluded that implants with modified surfaces have a higher risk for disease recurrence/progression. The reason why implants with a modified surface consistently are showing inferior outcomes following treatment of peri-implantitis is not fully investigated. The surface topography may inhibit access for decontamination and/or facilitate new biofilm formation following treatment of peri-implantitis.



## Reconstructive treatment protocols

The reconstructive approach using different augmentation materials in conjunction with surgical therapy of peri-implantitis has been investigated in pre-clinical and clinical settings (K. Jepsen et al., 2016; Persson et al., 1996; Ramos et al., 2017; Renvert et al., 2018; Schou, Holmstrup, Jørgensen, Skovgaard, Stoltze, Hjørtning-Hansen, & Wenzel, 2003a; Schou, Holmstrup, Jørgensen, Stoltze, et al., 2003c; Wohlfahrt et al., 2012). The aim of such protocols was to restore missing hard tissues and to increase the amount of re-osseointegration that subsequently may provide increased support to the implant and the peri-implant soft tissue. While re-osseointegration following reconstructive surgical therapy on a previously exposed implant surface was demonstrated in the experiments by Persson et al. (1996) and Wetzel et al. (1999), such a benefit of using bone filling biomaterials, however, was not confirmed by results from another experimental study (Ramos et al., 2017). On clinical trials, significant superior outcomes of radiological defect fill was demonstrated following surgical treatment of peri-implantitis with bone augmentation compared to control (K. Jepsen et al., 2016; Renvert et al., 2018; Wohlfahrt et al., 2012). Such improvement in the augmented sites, however, was not seen on clinical measures (probing pocket depth and soft tissue level).

In Study III, soft tissue level alterations, histological and radiological findings following reconstructive treatment of experimental peri-implantitis were reported. Although re-osseointegration was demonstrated with and without the use of augmentation biomaterials, the amount of newly formed bone was not superior using any of the different approaches.

## Accuracy of radiological assessments

Intra-oral periapical radiographs are essential clinical tools for evaluation of peri-implant bone levels, presence of peri-implant disease and disease progression (Berglundh et al., 2018a; Berglundh, Jepsen, Stadlinger, & Terheyden, 2019; Derks & Tomasi, 2015). Specifically, intraoral radiography is an important tool for follow-up and evaluation of healing after peri-implantitis treatment (Berglundh et al., 2018b; Carcuac et al., 2017; Renvert et al., 2018). In the context of implant dentistry, intra-oral periapical radiographs give information about the marginal bone level (Sicilia et al., 2020), mainly at mesial and distal aspects of the dental implant (Corpas et al., 2011; Ritter et al., 2014). However, the bucco-lingual aspects of the marginal bone level around dental implants cannot be assessed using intra-oral radiography. In contrast, cone beam computed tomography (CBCT) can provide circumferential images of all aspects around dental implants (Corpas et al., 2011; Raes, Renckens, Aps, Cosyn, & De Bruyn, 2013; Ritter et al., 2014; Veltri, Ekstubbbe, Abrahamsson, & Wennström, 2016). The use of CBCT, however, results in exposure with higher radiation levels to the patient than that of intra-oral periapical radiographs (Kadesjö, Lynds, Nilsson, & Shi, 2018).

Thus, the remaining question is if the additional information from CBCT may justify the increased radiological biohazard. In this context, in an *in-vivo* study, Corpas et al. (2011) compared bone level assessment around implants using periapical radiographs, CBCT images and histological sections. It was concluded that the bone level was overestimated on both types of radiological assessments compared to the corresponding measurements on histology (Corpas et al., 2011). Similarly, Stokholm et al. (2016) in a study in monkeys found an overestimation when bone levels were assessed on radiographs compared to corresponding assessments on histological sections. Such findings were in agreement with the results from Study IV. It is, however, important to realize that the design of Study IV targeted bone level assessments following reconstructive surgical therapy of experimental peri-implantitis. Thus, the interpretation of the findings should be made with care. Another critical point that should be pointed out is the novel design of Study IV, i.e. that the comparison between CBCT and histology was limited to matched and corresponding sections that were identified by a small mesio-distal cut made at the top of each implant abutment prior to the CBCT examination (Fig. 7). This cut was used to identify the position of the intended histological sections and the CBCT images.

In Study IV, the level of correlation and agreement of bone level assessment between radiological and histological evaluations were higher compared to the results by Corpas et al. (2011) and Stokholm et al. (2016). In contrast to our finding in Study IV, Raes et al. (2013) evaluated bone level measurements assessed on PA radiographs and CBCT images in a clinical methodological study and reported that the bone levels were overestimated on CBCT images as opposed to those on PA radiographs. Here, the resolution of the CBCT scanner is another point that should be considered during the interpretation of bone level assessment on CBCT images. CBCT scanners with a small voxel size provide images with a higher resolution than scanners with a higher voxel size (Razavi, Palmer, Davies, Wilson, & Palmer, 2010). In Study IV, the voxel size was 0.08 mm, whereas in the study by Raes et al. (2013) the voxel size was 0.2 mm. The bone level overestimation in Study IV, however, was about 0.3 - 0.4 mm.

In addition, in Study IV the difference in MBL assessments made on CBCT between interproximal and bucco-lingual sites were not statistically significant. Thus, the bone level assessments made on PA radiographs, which are limited to interproximal sites may, therefore, be considered to provide a sufficient estimation of the entire circumferential bone level around the dental implant. Therefore, bone level assessments obtained from PA radiographs can be considered a reliable technique for peri-implant bone level evaluations following reconstructive surgical therapy of experimental peri-implantitis.



# Acknowledgements

Grants were received from Dentsply Implants IH AB, Mölndal, Sweden, the Swedish Research Council (Vetenskapsrådet) and TUA research funding Gothenburg, Sweden. Many thanks also to the Saudi Ministry of Higher Education, Um Al-Qura University for the kind care and support.



# References

- Albouy, J.-P., Abrahamsson, I., Persson, L. G., & Berglundh, T. (2008). Spontaneous progression of peri-implantitis at different types of implants. An experimental study in dogs. I: Clinical and radiographic observations. *Clinical Oral Implants Research*, *19*(10), 997–1002. <http://doi.org/10.1111/j.1600-0501.2008.01589.x>
- Albouy, J.-P., Abrahamsson, I., Persson, L. G., & Berglundh, T. (2011). Implant surface characteristics influence the outcome of treatment of peri-implantitis: An experimental study in dogs. *Journal of Clinical Periodontology*, *38*(1), 58–64. <http://doi.org/10.1111/j.1600-051X.2010.01631.x>
- Albrektsson, T., & Wennerberg, A. (2004). Oral implant surfaces: Part 1-review focusing on topographic and chemical properties of different surfaces and in vivo responses to them. *International Journal of Prosthodontics*, *17*(5), 536–543.
- Alhag, M., Renvert, S., Polyzois, I., & Claffey, N. (2008). Re-osseointegration on rough implant surfaces previously coated with bacterial biofilm: An experimental study in the dog. *Clinical Oral Implants Research*, *19*(2), 182–187. <http://doi.org/10.1111/j.1600-0501.2007.01429.x>
- Berglundh, T., Armitage, G., Araújo, M. G., Avila-Ortiz, G., Blanco, J., Camargo, P. M., Chen, S., Cochran, D., Derks, J., Figuero, E., Hämmerle, C. H. F., Heitz-Mayfield, L. J. A., Huynh-Ba, G., Iacono, V., Koo, K.-T., Lambert, F., McCauley, L., Quirynen, M., Renvert, S., Salvi, G. E., Schwarz, F., Tarnow, D., Tomasi, C., Wang, H.-L., & Zitzmann, N. (2018a). Peri-implant diseases and conditions: Consensus report of workgroup 4 of the 2017 World Workshop on the Classification of Periodontal and Peri-Implant Diseases and Conditions (Vol. 45, pp. S286–S291). Presented at the Journal of clinical periodontology. <http://doi.org/10.1111/jcpe.12957>
- Berglundh, T., Gotfredsen, K., Zitzmann, N. U., Lang, N. P., & Lindhe, J. (2007). Spontaneous progression of ligature induced peri-implantitis at implants with different surface roughness: an experimental study in dogs. *Clinical Oral Implants Research*, *18*(5), 655–661. <http://doi.org/10.1111/j.1600-0501.2007.01397.x>
- Berglundh, T., Jepsen, S., Stadlinger, B., & Terheyden, H. (2019). Peri-implantitis and its prevention. *Clinical Oral Implants Research*, *30*(2), 150–155. <http://doi.org/10.1111/clr.13401>
- Berglundh, T., Lindhe, J., Jonsson, K., & Ericsson, I. (1994). The topography of the vascular systems in the periodontal and peri-implant tissues in the dog. *Journal of Clinical Periodontology*, *21*(3), 189–193. <http://doi.org/10.1111/j.1600-051X.1994.tb00302.x>
- Berglundh, T., Wennström, J. L., & Lindhe, J. (2018b). Long-term outcome of surgical treatment of peri-implantitis. A 2-11-year retrospective study. *Clin-*

- ical Oral Implants Research*, 29(4), 404–410.  
<http://doi.org/10.1111/clar.13138>
- Brohede, U., Forsgren, J., Roos, S., Mhryanyan, A., Engqvist, H., & Strømme, M. (2009). Multifunctional implant coatings providing possibilities for fast antibiotics loading with subsequent slow release. *Journal of Materials Science: Materials in Medicine*, 20(9), 1859–1867.  
<http://doi.org/10.1007/s10856-009-3749-6>
- Carcuac, O., Abrahamsson, I., Albouy, J.-P., Linder, E., Larsson, L., & Berglundh, T. (2013). Experimental periodontitis and peri-implantitis in dogs. *Clinical Oral Implants Research*, 24(4), 363–371.  
<http://doi.org/10.1111/clar.12067>
- Carcuac, O., Abrahamsson, I., Charalampakis, G., & Berglundh, T. (2015). The effect of the local use of chlorhexidine in surgical treatment of experimental peri-implantitis in dogs. *Journal of Clinical Periodontology*, 42(2), 196–203. <http://doi.org/10.1111/jcpe.12332>
- Carcuac, O., Abrahamsson, I., Derks, J., Petzold, M., & Berglundh, T. (2020). Spontaneous progression of experimental peri-implantitis in augmented and pristine bone: A pre-clinical in vivo study. *Clinical Oral Implants Research*, 31(2), 192–200. <http://doi.org/10.1111/clar.13564>
- Carcuac, O., Derks, J., Abrahamsson, I., Wennström, J. L., Petzold, M., & Berglundh, T. (2017). Surgical treatment of peri-implantitis: 3-year results from a randomized controlled clinical trial. *Journal of Clinical Periodontology*, 44(12), 1294–1303. <http://doi.org/10.1111/jcpe.12813>
- Carcuac, O., Derks, J., Charalampakis, G., Abrahamsson, I., Wennström, J., & Berglundh, T. (2016). Adjunctive Systemic and Local Antimicrobial Therapy in the Surgical Treatment of Peri-implantitis: A Randomized Controlled Clinical Trial. *Journal of Dental Research*, 95(1), 50–57. <http://doi.org/10.1177/0022034515601961>
- Carinci, F., Lauritano, D., Bignozzi, C. A., Pazzi, D., Candotto, V., de Oliveira, P. S., & Scarano, A. (2019). A new strategy against peri-implantitis: Antibacterial internal coating. *International Journal of Molecular Sciences*, 20(16), 3897. <http://doi.org/10.3390/ijms20163897>
- Cochis, A., Azzimonti, B., Valle, Della, C., Chiesa, R., Arciola, C. R., & Rimondini, L. (2015). Biofilm formation on titanium implants counteracted by grafting gallium and silver ions. *Journal of Biomedical Materials Research Part A*, 103(3), 1176–1187. <http://doi.org/10.1002/jbm.a.35270>
- Cochis, A., Azzimonti, B., Valle, Della, C., De Giglio, E., Bloise, N., Visai, L., et al. (2016). The effect of silver or gallium doped titanium against the multidrug resistant *Acinetobacter baumannii*. *Biomaterials*, 80(1), 80–95. <http://doi.org/10.1016/j.biomaterials.2015.11.042>
- Corpas, L. D. S., Jacobs, R., Quirynen, M., Huang, Y., Naert, I., & Duyck, J. (2011). Peri-implant bone tissue assessment by comparing the outcome of intra-oral radiograph and cone beam computed tomography analyses to the histological standard. *Clinical Oral Implants Research*, 22(5), 492–499. <http://doi.org/10.1111/j.1600-0501.2010.02029.x>



- Costa, F. O., Takenaka-Martinez, S., Cota, L. O. M., Ferreira, S. D., Silva, G. L. M., & Costa, J. E. (2012). Peri-implant disease in subjects with and without preventive maintenance: A 5-year follow-up. *Journal of Clinical Periodontology*, *39*(2), 173–181. <http://doi.org/10.1111/j.1600-051X.2011.01819.x>
- Deppe, H., Wagenpfeil, S., & Donath, K. (2004). Comparative value of attachment measurements in implant dentistry. *The International Journal of Oral & Maxillofacial Implants*, *19*(2), 208–215.
- Derks, J., & Tomasi, C. (2015). Peri-implant health and disease. A systematic review of current epidemiology. *Journal of Clinical Periodontology*, *42*(S16), S158–S171. <http://doi.org/10.1111/jcpe.12334>
- Derks, J., Schaller, D., Håkansson, J., Wennström, J. L., Tomasi, C., & Berglundh, T. (2016). Effectiveness of Implant Therapy Analyzed in a Swedish Population: Prevalence of Peri-implantitis. *Journal of Dental Research*, *95*(1), 43–49. <http://doi.org/10.1177/0022034515608832>
- Donath, K., & Breuner, G. (1982). A method for the study of undecalcified bones and teeth with attached soft tissues: The Säge-Schliff (sawing and grinding) Technique. *Journal of Oral Pathology & Medicine*, *11*(4), 318–326. <http://doi.org/10.1111/j.1600-0714.1982.tb00172.x>
- Ericsson, I., Persson, L. G., Berglundh, T., Edlund, T., & Lindhe, J. (1996). The effect of antimicrobial therapy on periimplantitis lesions. An experimental study in the dog. *Clinical Oral Implants Research*, *7*(4), 320–328.
- Fickl, S., Kerschull, M., Calvo-Guirado, J. L., Hürzeler, M., & Zuhr, O. (2015). Experimental Peri-Implantitis around Different Types of Implants - A Clinical and Radiographic Study in Dogs. *Clinical Implant Dentistry and Related Research*, *17*, e661–e669. <http://doi.org/10.1111/cid.12303>
- Ghensi, P., Bettio, E., Maniglio, D., Bonomi, E., Piccoli, F., Gross, S., et al. (2019). Dental implants with anti-biofilm properties: A pilot study for developing a new sericin-based coating. *Materials*, *12*(15), 2429. <http://doi.org/10.3390/ma12152429>
- Godoy-Gallardo, M., Manzanares-Céspedes, M. C., Sevilla, P., Nart, J., Manzanares, N., Manero, J. M., et al. (2016). Evaluation of bone loss in antibacterial coated dental implants: An experimental study in dogs. *Materials Science & Engineering C*, *69*, 538–545. <http://doi.org/10.1016/j.msec.2016.07.020>
- Grunder, U., Hürzeler, M. B., Schupbach, P., & Strub, J. R. (1993). Treatment of ligature-induced peri-implantitis using guided tissue regeneration: A clinical and histologic study in the beagle dog. *International Journal of Oral and Maxillofacial Implants*, *8*(3), 282–293.
- Hayek, R. R. A., Araújo, N. S., Gioso, M. A., Ferreira, J., Baptista-Sobrinho, C. A., Yamada, A. M., & Ribeiro, M. S. (2005). Comparative study between the effects of photodynamic therapy and conventional therapy on microbial reduction in ligature-induced peri-implantitis in dogs. *Journal of Periodontology*, *76*(8), 1275–1281. <http://doi.org/10.1902/jop.2005.76.8.1275>

- Heitz-Mayfield, L. J. A., & Salvi, G. E. (2018). Peri-implant mucositis. *Journal of Clinical Periodontology*, 45 Suppl 20, S237–S245. <http://doi.org/10.1111/jcpe.12953>
- Heitz-Mayfield, L. J., Aaboe, M., Araujo, M., Carrión, J. B., Cavalcanti, R., Cionca, N., et al. (2018). Group 4 ITI Consensus Report: Risks and biologic complications associated with implant dentistry. *Clinical Oral Implants Research*, 29, 351–358. <http://doi.org/10.1111/clar.13307>
- Htet, M., Madi, M., Zakaria, O., Miyahara, T., Xin, W., Lin, Z., et al. (2016). Decontamination of anodized implant surface with different modalities for peri-implantitis treatment: Lasers and mechanical debridement with citric acid. *Journal of Periodontology*, 87(8), 953–961. <http://doi.org/10.1902/jop.2016.150615>
- Hürzeler, M. B., Quiñones, C. R., Morrison, E. C., & Caffesse, R. G. (1995). Treatment of peri-implantitis using guided bone regeneration and bone grafts, alone or in combination, in beagle dogs. Part 1: Clinical findings and histologic observations. *International Journal of Oral and Maxillofacial Implants*, 10(4), 474–484.
- Jepsen, K., Jepsen, S., Laine, M. L., Anssari Moin, D., Piloni, A., Zeza, B., et al. (2016). Reconstruction of Peri-implant Osseous Defects: A Multicenter Randomized Trial. *Journal of Dental Research*, 95(1), 58–66. <http://doi.org/10.1177/0022034515610056>
- Jepsen, S., Berglundh, T., Genco, R., Aass, A. M., Demirel, K., Derks, J., et al. (2015). Primary prevention of peri-implantitis: Managing peri-implant mucositis. *Journal of Clinical Periodontology*, 42(S16), S152–S157. <http://doi.org/10.1111/jcpe.12369>
- Kadesjö, N., Lynds, R., Nilsson, M., & Shi, X.-Q. (2018). Radiation dose from X-ray examinations of impacted canines: Cone beam CT vs two-dimensional imaging. *Dentomaxillofacial Radiology*, 47(3), 20170305. <http://doi.org/10.1259/dmfr.20170305>
- Kolonidis, S. G., Renvert, S., Hämmerle, C. H. F., Lang, N. P., Harris, D., & Claffey, N. (2003). Osseointegration on implant surfaces previously contaminated with plaque: An experimental study in the dog. *Clinical Oral Implants Research*, 14(4), 373–380. <http://doi.org/10.1034/j.1600-0501.2003.01871.x>
- Lin, D.-J., Tsai, M.-T., Shieh, T.-M., Huang, H.-L., Hsu, J.-T., Ko, Y.-C., & Fuh, L.-J. (2013). In vitro antibacterial activity and cytocompatibility of bismuth doped micro-arc oxidized titanium. *Journal of Biomaterials Applications*, 27(5), 553–563. <http://doi.org/10.1177/0885328211414942>
- Lindhe, J., & Ericsson, I. (1978). Effect of ligature placement and dental plaque on periodontal tissue breakdown in the dog. *Journal of Periodontology*, 49(7), 343–350. <http://doi.org/10.1902/jop.1978.49.7.343>
- Lindhe, J., Berglundh, T., Ericsson, I., Liljenberg, B., & Marinello, C. (1992). Experimental breakdown of peri-implant and periodontal tissues. A study in the beagle dog. *Clinical Oral Implants Research*, 3(1), 9–16. <http://doi.org/10.1034/j.1600-0501.1992.030102.x>

- López-Píriz, R., Solá-Linares, E., Rodríguez-Portugal, M., Malpica, B., Díaz-Güemes, I., Enciso, S., et al. (2015). Evaluation in a dog model of three antimicrobial glassy coatings: Prevention of bone loss around implants and microbial assessments. *Plos One*, *10*(10), e0140374. <http://doi.org/10.1371/journal.pone.0140374>
- Machado, M. A., Stefani, C. M., Sallum, E. A., Sallum, A. W., Tramontina, V. A., & Nociti Júnior, F. H. (1999). Treatment of ligature-induced peri-implantitis defects by regenerative procedures: a clinical study in dogs. *Journal of Oral Science*, *41*(4), 181–185. <http://doi.org/10.2334/josnusd.41.181>
- Madi, M., Zakaria, O., Noritake, K., Fujii, M., & Kasugai, S. (2013). Peri-implantitis progression around thin sputtered hydroxyapatite-coated implants: Clinical and radiographic evaluation in dogs. *International Journal of Oral and Maxillofacial Implants*, *28*(3), 701–709. <http://doi.org/10.11607/jomi.2891>
- Marinello, C. P., Berglundh, T., Ericsson, I., Klinge, B., Glantz, P. O., & Lindhe, J. (1995). Resolution of ligature-induced peri-implantitis lesions in the dog. *Journal of Clinical Periodontology*, *22*(6), 475–479. <http://doi.org/10.1111/j.1600-051X.1995.tb00180.x>
- Martinez, A., Guitián, F., López-Píriz, R., Bartolomé, J. F., Cabal, B., Esteban-Tejeda, L., et al. (2014). Bone loss at implant with titanium abutments coated by soda lime glass containing silver nanoparticles: a histological study in the dog. *Plos One*, *9*(1), e86926. <http://doi.org/10.1371/journal.pone.0086926>
- Meyer, S., Giannopoulou, C., Courvoisier, D., Schimmel, M., Müller, F., & Mombelli, A. (2017). Experimental mucositis and experimental gingivitis in persons aged 70 or over. Clinical and biological responses. *Clinical Oral Implants Research*, *28*(8), 1005–1012. <http://doi.org/10.1111/clr.12912>
- Mir-Mari, J., Mir-Orfila, P., Figueiredo, R., Valmaseda-Castellón, E., & Gay-Escoda, C. (2012). Prevalence of peri-implant diseases. A cross-sectional study based on a private practice environment. *Journal of Clinical Periodontology*, *39*(5), 490–494. <http://doi.org/10.1111/j.1600-051X.2012.01872.x>
- Nagay, B. E., Dini, C., Cordeiro, J. M., Ricomini-Filho, A. P., De Avila, E. D., Rangel, E. C., et al. (2019). Visible-Light-Induced Photocatalytic and Antibacterial Activity of TiO<sub>2</sub> Codoped with Nitrogen and Bismuth: New Perspectives to Control Implant-Biofilm-Related Diseases. *ACS Applied Materials & Interfaces*, *11*(20), 18186–18202. <http://doi.org/10.1021/acsami.9b03311>
- Namgoong, H., Kim, M.-D., Ku, Y., Rhyu, I.-C., Lee, Y.-M., Seol, Y.-J., et al. (2015). Bone reconstruction after surgical treatment of experimental peri-implantitis defects at a sandblasted/acid-etched hydroxyapatite-coated implant: an experimental study in the dog. *Journal of Clinical Periodontology*, *42*(10), 960–966. <http://doi.org/10.1111/jcpe.12457>

- Park, S.-Y., Kim, K.-H., Shin, S.-Y., Koo, K.-T., Lee, Y.-M., Chung, C.-P., & Seol, Y.-J. (2015). Decontamination methods using a dental water jet and dental floss for microthreaded implant fixtures in regenerative periimplantitis treatment. *Implant Dentistry*, 24(3), 307–316. <http://doi.org/10.1097/ID.0000000000000208>
- Persson, L. G., Araújo, M. G., Berglundh, T., Gröndahl, K., & Lindhe, J. (1999). Resolution of peri-implantitis following treatment - An experimental study in the dog. *Clinical Oral Implants Research*, 10(3), 195–203. <http://doi.org/10.1034/j.1600-0501.1999.100302.x>
- Persson, L. G., Berglundh, T., Lindhe, J., & Sennerby, L. (2001a). Reosseointegration after treatment of peri-implantitis at different implant surfaces. An experimental study in the dog. *Clinical Oral Implants Research*, 12(6), 595–603. <http://doi.org/10.1034/j.1600-0501.2001.120607.x>
- Persson, L. G., Ericsson, I., Berglundh, T., & Lindhe, J. (1996). Guided bone regeneration in the treatment of periimplantitis. *Clinical Oral Implants Research*, 7(4), 366–372. <http://doi.org/10.1034/j.1600-0501.1996.070410.x>
- Persson, L. G., Ericsson, I., Berglundh, T., & Lindhe, J. (2001b). Osseointegration following treatment of peri-implantitis and replacement of implant components: An experimental study in the dog. *Journal of Clinical Periodontology*, 28(3), 258–263. <http://doi.org/10.1034/j.1600-051x.2001.028003258.x>
- Persson, L. G., Mouhyi, J., Berglundh, T., Sennerby, L., & Lindhe, J. (2004). Carbon dioxide laser and hydrogen peroxide conditioning in the treatment of periimplantitis: an experimental study in the dog. *Clinical Implant Dentistry and Related Research*, 6(4), 230–238. <http://doi.org/10.1111/j.1708-8208.2004.tb00039.x>
- Raes, F., Renckens, L., Aps, J., Cosyn, J., & De Bruyn, H. (2013). Reliability of circumferential bone level assessment around single implants in healed ridges and extraction sockets using cone beam CT. *Clinical Implant Dentistry and Related Research*, 15(5), 661–672. <http://doi.org/10.1111/j.1708-8208.2011.00393.x>
- Ramos, U. D., Suaid, F. A., Wikesjö, U. M. E., Susin, C., Taba, M., & Novaes, A. B. (2017). Comparison between two antimicrobial protocols with or without guided bone regeneration in the treatment of peri-implantitis. A histomorphometric study in dogs. *Clinical Oral Implants Research*, 28(11), 1388–1395. <http://doi.org/10.1111/clr.12998>
- Razavi, T., Palmer, R. M., Davies, J., Wilson, R., & Palmer, P. J. (2010). Accuracy of measuring the cortical bone thickness adjacent to dental implants using cone beam computed tomography. *Clinical Oral Implants Research*, 21(7), 718–725. <http://doi.org/10.1111/j.1600-0501.2009.01905.x>
- Renvert, S., Roos-Jansåker, A. M., & Persson, G. R. (2018). Surgical treatment of peri-implantitis lesions with or without the use of a bone substitute—a randomized clinical trial. *Journal of Clinical Periodontology*, 45(10), 1266–1274. <http://doi.org/10.1111/jcpe.12986>
- Ritter, L., Elger, M. C., Rothamel, D., Fienitz, T., Zinser, M., Schwarz, F., & Zöller, J. E. (2014). Accuracy of peri-implant bone evaluation using cone

- beam CT, digital intra-oral radiographs and histology. *Dentomaxillofacial Radiology*, 43(6), 20130088. <http://doi.org/10.1259/dmfr.20130088>
- Roos-Jansåker, A. M., Renvert, S., & Egelberg, J. (2003). Treatment of peri-implant infections: A literature review. *Journal of Clinical Periodontology*, 30(6), 467–485. <http://doi.org/10.1034/j.1600-051X.2003.00296.x>
- Rovin, S., Costich, E. R., & Gordon, H. A. (1966). The influence of bacteria and irritation in the initiation of periodontal disease in germfree and conventional rats. *Journal of Periodontal Research*, 1(3), 193–204. <http://doi.org/10.1111/j.1600-0765.1966.tb01860.x>
- Salvi, G. E., & Ramseier, C. A. (2015). Efficacy of patient-administered mechanical and/or chemical plaque control protocols in the management of peri-implant mucositis. A systematic review. *Journal of Clinical Periodontology*, 42(S16), S187–S201. <http://doi.org/10.1111/jcpe.12321>
- Salvi, G. E., & Zitzmann, N. U. (2014). The effects of anti-infective preventive measures on the occurrence of biologic implant complications and implant loss: a systematic review. *The International Journal of Oral & Maxillofacial Implants*, 29 Suppl(Supplement), 292–307. <http://doi.org/10.11607/jomi.2014suppl.g5.1>
- Salvi, G. E., Aglietta, M., Eick, S., Sculean, A., Lang, N. P., & Ramseier, C. A. (2012). Reversibility of experimental peri-implant mucositis compared with experimental gingivitis in humans. *Clinical Oral Implants Research*, 23(2), 182–190. <http://doi.org/10.1111/j.1600-0501.2011.02220.x>
- Schou, S., Holmstrup, P., Jørgensen, T., Skovgaard, L. T., Stoltze, K., Hjørting-Hansen, E., & Wenzel, A. (2003a). Anorganic porous bovine-derived bone mineral (Bio-Oss) and ePTFE membrane in the treatment of peri-implantitis in cynomolgus monkeys. *Clinical Oral Implants Research*, 14(5), 535–547. <http://doi.org/10.1034/j.1600-0501.2003.00911.x>
- Schou, S., Holmstrup, P., Jørgensen, T., Skovgaard, L. T., Stoltze, K., Hjørting-Hansen, E., & Wenzel, A. (2003b). Implant surface preparation in the surgical treatment of experimental peri-implantitis with autogenous bone graft and ePTFE membrane in cynomolgus monkeys. *Clinical Oral Implants Research*, 14(4), 412–422. <http://doi.org/10.1034/j.1600-0501.2003.00912.x>
- Schou, S., Holmstrup, P., Jørgensen, T., Stoltze, K., Hjørting-Hansen, E., & Wenzel, A. (2003c). Autogenous bone graft and ePTFE membrane in the treatment of peri-implantitis. I. Clinical and radiographic observations in cynomolgus monkeys. *Clinical Oral Implants Research*, 14(4), 391–403. <http://doi.org/10.1034/j.1600-0501.2003.120909.x>
- Schou, S., Holmstrup, P., Skovgaard, L. T., Stoltze, K., Hjørting-Hansen, E., & Gundersen, H. J. G. (2003d). Autogenous bone graft and ePTFE membrane in the treatment of peri-implantitis. II. Stereologic and histologic observations in cynomolgus monkeys. *Clinical Oral Implants Research*, 14(4), 404–411. <http://doi.org/10.1034/j.1600-0501.2003.120910.x>
- Schüpbach, P., Hürzeler, M., & Grunder, U. (1994). Implant-tissue interfaces following treatment of peri-implantitis using guided tissue regeneration: a light and electron microscopic study. *Clinical Oral Implants Research*, 5(2), 55–65. <http://doi.org/10.1034/j.1600-0501.1994.050201.x>

- Schwarz, F., Derks, J., Monje, A., & Wang, H.-L. (2018). Peri-implantitis. *Journal of Periodontology*, *89*(6), S267–S290. <http://doi.org/10.1002/JPER.16-0350>
- Schwarz, F., Jepsen, S., Herten, M., Sager, M., Rothamel, D., & Becker, J. (2006). Influence of different treatment approaches on non-submerged and submerged healing of ligature induced peri-implantitis lesions: an experimental study in dogs. *Journal of Clinical Periodontology*, *33*(8), 584–595. <http://doi.org/10.1111/j.1600-051X.2006.00956.x>
- Shibli, J. A., Martins, M. C., Ribeiro, F. S., Garcia, V. G., Nociti, F. H., & Marcantonio, E. (2006). Lethal photosensitization and guided bone regeneration in treatment of peri-implantitis: an experimental study in dogs. *Clinical Oral Implants Research*, *17*(3), 273–281. <http://doi.org/10.1111/j.1600-0501.2005.01167.x>
- Sicilia, A., Gallego, L., Sicilia, P., Mallo, C., Cuesta, S., & Sanz, M. (2020). Crestal bone loss associated with different implant surfaces in the posterior mandible in patients with a history of periodontitis. A retrospective study. *Clinical Oral Implants Research*, *clr.13682*. <http://doi.org/10.1111/clr.13682>
- Sobolev, A., Valkov, A., Kossenko, A., Wolicki, I., Zinigrad, M., & Borodianskiy, K. (2019). Bioactive Coating on Ti Alloy with High Osseointegration and Antibacterial Ag Nanoparticles. *ACS Applied Materials & Interfaces*, *11*(43), 39534–39544. <http://doi.org/10.1021/acsami.9b13849>
- Socransky, S. S., Smith, C., Martin, L., Paster, B. J., Dewhirst, F. E., & Levin, A. E. (1994). “Checkerboard” DNA-DNA hybridization. *BioTechniques*, *17*(4), 788–792.
- Stokholm, R., Spin-Neto, R., Nyengaard, J. R., & Isidor, F. (2016). Comparison of radiographic and histological assessment of peri-implant bone around oral implants. *Clinical Oral Implants Research*, *27*(7), 782–786. <http://doi.org/10.1111/clr.12683>
- Stübinger, S., Henke, J., Donath, K., & Deppe, H. (2005). Bone regeneration after peri-implant care with the CO<sub>2</sub> laser: a fluorescence microscopy study. *The International Journal of Oral & Maxillofacial Implants*, *20*(2), 203–210.
- Takasaki, A. A., AOKI, A., MIZUTANI, K., Kikuchi, S., Oda, S., & ISHIKAWA, I. (2007). Er:YAG laser therapy for peri-implant infection: a histological study. *Lasers in Medical Science*, *22*(3), 143–157. <http://doi.org/10.1007/s10103-006-0430-x>
- Tillmanns, H. W. S., Hermann, J. S., Cagna, D. R., Burgess, A. V., & Meffert, R. M. (1997). Evaluation of three different dental implants in ligature-induced peri-implantitis in the beagle dog. part i. clinical evaluation. *International Journal of Oral and Maxillofacial Implants*, *12*(5), 611–620.
- Veltri, M., Ekestubbe, A., Abrahamsson, I., & Wennström, J. L. (2016). Three-Dimensional buccal bone anatomy and aesthetic outcome of single dental implants replacing maxillary incisors. *Clinical Oral Implants Research*, *27*(8), 956–963. <http://doi.org/10.1111/clr.12664>

- Viganò, P., Apaza Alccayhuaman, K. A., Sakuma, S., Amari, Y., Bengazi, F., & Botticelli, D. (2019). Use of TiBrush for surface decontamination at peri-implantitis sites in dogs: Radiographic and histological outcomes. *Journal of Investigative and Clinical Dentistry*, *10*(1), e12378. <http://doi.org/10.1111/jicd.12378>
- Wetzel, A. C., Vlassis, J., Caffesse, R. G., Hämmerle, C. H., & Lang, N. P. (1999). Attempts to obtain re-osseointegration following experimental peri-implantitis in dogs. *Clinical Oral Implants Research*, *10*(2), 111–119. <http://doi.org/10.1034/j.1600-0501.1999.100205.x>
- Wohlfahrt, J. C., Lyngstadaas, S. P., Rønold, H. J., Saxegaard, E., Ellingsen, J. E., Karlsson, S., & Aass, A. M. (2012). Porous titanium granules in the surgical treatment of peri-implant osseous defects: A randomized clinical trial. *International Journal of Oral and Maxillofacial Implants*, *27*(2), 401–410.
- Xing, R., Witsø, I. L., Jugowiec, D., Tiainen, H., Shabestari, M., Lyngstadaas, S. P., et al. (2015). Antibacterial effect of doxycycline-coated dental abutment surfaces. *Biomedical Materials (Bristol, England)*, *10*(5), 055003. <http://doi.org/10.1088/1748-6041/10/5/055003>
- Zeller, B., Stöckli, S., Zaugg, L. K., Astasov Frauenhoffer, M., Hauser Gerspach, I., Waltimo, T., & Zitzmann, N. U. (2020). Biofilm formation on metal alloys, zirconia and polyetherketoneketone as implant materials in vivo. *Clinical Oral Implants Research*, *31*(11), 1078–1086. <http://doi.org/10.1111/clr.13654>
- Zitzmann, N. U., Berglundh, T., Ericsson, I., & Lindhe, J. (2004). Spontaneous progression of experimentally induced periimplantitis. *Journal of Clinical Periodontology*, *31*(10), 845–849. <http://doi.org/10.1111/j.1600-051X.2004.00567.x>





# Appendix

- I. Almohandes, A., Abrahamsson, I., Dahlén, G., & Berglundh, T. (2021). Effect of biofilm formation on implant abutments with an anti-bacterial coating: A pre-clinical in vivo study. *Clinical Oral Implants Research*, 32(6), 756-766.
  
- II. Almohandes, A., Abrahamsson, I., Dionigi, C., & Berglundh, T. (2021) Surgical treatment of experimental peri-implantitis using mechanical and chemical procedures. A pre-clinical in vivo study. *Submitted for publication*.
  
- III. Almohandes, A., Carcuac, O., Abrahamsson, I., Lund, H., & Berglundh, T. (2019). Re-osseointegration following reconstructive surgical therapy of experimental peri-implantitis. A pre-clinical in vivo study. *Clinical Oral Implants Research*, 30(5), 447-456.
  
- IV. Almohandes, A., Lund, H., Carcuac, O., Petzold, M., Berglundh, T., & Abrahamsson, I. (2021) Accuracy of bone level assessments following reconstructive surgical treatment of experimental peri-implantitis. *Submitted for publication*.