SPINAL NERVE ROOT COMPRESSION

Experimental studies on effects of acute, graded compression on nerve root nutrition and function, with an *in vivo* compression model of the porcine cauda equina.

By

KJELL OLMARKER

GÖTEBORG 1990

SPINAL NERVE ROOT COMPRESSION

Experimental studies on effects of acute, graded compression on nerve root nutrition and function, with an *in vivo* compression model of the porcine cauda equina.

AKADEMISK AVHANDLING

som för avläggande av doktorsexamen i medicinsk vetenskap vid Göteborgs Universitet kommer att offentligen försvaras i Anatomiska Institutionens stora föreläsningssal fredagen den 11 maj 1990 kl. 9.00

Av

KJELL OLMARKER
Exam Läk

Avhandlingen baseras på följande delarbeten:

I Olmarker K, Holm S, Rosenqvist A-L & Rydevik B. 1990.
Experimental nerve root compression. Presentation of a model for acute, graded compression of the porcine cauda equina, with analyses of neural and vascular anatomy. *Spine (In press)*

II Olmarker K, Rydevik B, Holm S & Bagge U. 1989.
Effects of experimental, graded compression on blood flow in spinal nerve roots. A vital microscopic study on the porcine cauda equina. *J Orthop Res 7:817-823*

III Olmarker K, Rydevik B, Hansson T & Holm S. 1990.
Compression-induced changes of the nutritional supply to the porcine cauda equina. *J Spinal Dis 3:25-29*

IV Olmarker K, Rydevik B & Holm S. 1989.
Edema formation in spinal nerve roots induced by experimental, graded compression. An experimental study on the pig cauda equina with special reference to differences in effects between rapid and slow onset of compression. *Spine.14:569-573*

V Olmarker K, Holm S & Rydevik B. 1990.
Importance of compression onset rate for the degree of impairment of impulse propagation in experimental compression of the porcine cauda equina. *Spine (In press)*

Göteborg 1990

ABSTRACT

OLMARKER K., SPINAL NERVE ROOT COMPRESSION. Experimental studies on effects of acute, graded compression on nerve root nutrition and function, with an *in vivo* compression model of the porcine cauda equina. Page 1-70. Department of Anatomy, University of Göteborg, Box 33 031, S-400 33 GÖTEBORG, and Department of Orthopaedics, Sahlgren Hospital, University of Göteborg, S-413 45 GÖTEBORG, Sweden. Thesis May 11, 1990.

Compression of spinal nerve roots is a common clinical condition. Critical pressure levels for compression-induced impairment of basic physiologic processes have not been determined in previous experimental studies of this topic. The present investigation was performed in order to develop a model for experimental nerve root compression, and to investigate the effects of such compression on nerve root nutrition and function.

1 Model: An inflatable plastic balloon was placed over the exposed cauda equina and was fixed to the spine by two L-shaped pins. When inflated, the nerve roots were compressed towards the anterior aspect of the spinal canal. The normal neural and vascular anatomy of the pig cauda equina was studied with light microscopy and ink angiography. *2 Intraneural blood flow:* The blood vessels of the nerve roots were observed with vital microscopy. During stepwize increments of balloon pressure, the critical pressures required to stop the blood flow were studied. The recirculation after compression was also analysed. *3 Transport of nutrients:* Radioactive labelled methyl glucose was allowed to circulate systemically during compression. The entire preparation was frozen with liquid nitrogen, and biopsies of the cauda equina were analysed regarding methyl glucose concentration. *4 Vascular permeability:* Microvascular permeability was analysed using a dye-tracing technique, (fluorescence microscopy and Evans Blue albumin). After compression, the cauda equina was frozen with liquid nitrogen. Frozen sections were analysed regarding distribution of the injected tracer. *5 Impulse propagation:* The cauda equina was stimulated cranial to the compression zone and a muscle action potential was recorded in the tail muscles. Registrations were performed during 2 hours of compression and 1.5 hours of recovery. In addition, the effects of two compression onset rates (0.05-0.1 seconds and 20 seconds) were studied in experiments 3, 4 and 5.

1 Model: The neural and vascular anatomy of the pig cauda equina were found to be close to that of the human cauda equina. *2 Intraneural blood flow:* Arteriolar blood flow was stopped at a pressure close to the mean arterial blood pressure. Capillary blood flow was dependant on a flow in connected venules. Venular blood flow could be stopped at low pressures, (5-10 mm Hg). Compression for 2 hours at both 50 and 200 mm Hg induced intraneural edema. *3 Transport of nutrients:* Impairment of methyl glucose transport was seen even at low pressure leves, (10 mm Hg). *4 Vascular permeability:* Increased vascular permeability, (*ie.*, intraneural edema formation), was seen after compression at 50 mm Hg for 2 minutes. *5 Impulse propagation:* Impaired impulse propagation was observed as a decrease in recorded MAP-amplitude after compression at 100 mm Hg for 2 hours. The rapid compression onset rate was found to induce more pronounced effects than the slow onset rate in experiments 3, 4 and 5.

In conclusion, a model for experimental studies of nerve root compression has been developed and defined regarding normal neural and vascular anatomy. Changes in nerve root nutrition and function were induced at low pressure levels. The compression onset rate was found to be of importance for the degree of observed effects.

Key Words: Nerve root, cauda equina, pig, compression, onset rate, blood flow, nutrition, vascular permeability, EMG, nerve function.

ISBN 91-7900-963-8 Correspondence to Kjell Olmarker, Lab Experimental Biology, Department of Anatomy, University of Göteborg, Box 33 031, S-400 33 GÖTEBORG, Sweden.

From the Laboratory of Experimental Biology, Department of Anatomy
and the Department of Orthopaedics, Sahlgren Hospital;
University of Göteborg, Sweden.

SPINAL NERVE ROOT COMPRESSION

Experimental studies on effects of acute, graded compression on nerve root nutrition and function, with an *in vivo* compression model of the porcine cauda equina.

By

KJELL OLMARKER

GÖTEBORG 1990

ABSTRACT

OLMARKER K., SPINAL NERVE ROOT COMPRESSION. Experimental studies on effects of acute, graded compression on nerve root nutrition and function, with an *in vivo* compression model of the porcine cauda equina. Page 1-70. Department of Anatomy, University of Göteborg, Box 33 031, S-400 33 GÖTEBORG, and Department of Orthopaedics, Sahlgren Hospital, University of Göteborg, S-413 45 GÖTEBORG, Sweden. Thesis May 11, 1990.

Compression of spinal nerve roots is a common clinical condition. Critical pressure levels for compression-induced impairment of basic physiologic processes have not been determined in previous experimental studies of this topic. The present investigation was performed in order to develop a model for experimental nerve root compression, and to investigate the effects of such compression on nerve root nutrition and function.

1 Model: An inflatable plastic balloon was placed over the exposed cauda equina and was fixed to the spine by two L-shaped pins. When inflated, the nerve roots were compressed towards the anterior aspect of the spinal canal. The normal neural and vascular anatomy of the pig cauda equina was studied with light microscopy and ink angiography. *2 Intraneural blood flow:* The blood vessels of the nerve roots were observed with vital microscopy. During stepwize increments of balloon pressure, the critical pressures required to stop the blood flow were studied. The recirculation after compression was also analysed. *3 Transport of nutrients:* Radioactive labelled methyl glucose was allowed to circulate systemically during compression. The entire preparation was frozen with liquid nitrogen, and biopsies of the cauda equina were analysed regarding methyl glucose concentration. *4 Vascular permeability:* Microvascular permeability was analysed using a dye-tracing technique, (fluorescence microscopy and Evans Blue albumin). After compression, the cauda equina was frozen with liquid nitrogen. Frozen sections were analysed regarding distribution of the injected tracer. *5 Impulse propagation:* The cauda equina was stimulated cranial to the compression zone and a muscle action potential was recorded in the tail muscles. Registrations were performed during 2 hours of compression and 1.5 hours of recovery. In addition, the effects of two compression onset rates (0.05-0.1 seconds and 20 seconds) were studied in experiments 3, 4 and 5.

1 Model: The neural and vascular anatomy of the pig cauda equina were found to be close to that of the human cauda equina. *2 Intraneural blood flow:* Arteriolar blood flow was stopped at a pressure close to the mean arterial blood pressure. Capillary blood flow was dependant on a flow in connected venules. Venular blood flow could be stopped at low pressures, (5-10 mm Hg). Compression for 2 hours at both 50 and 200 mm Hg induced intraneural edema. *3 Transport of nutrients:* Impairment of methyl glucose transport was seen even at low pressure leves, (10 mm Hg). *4 Vascular permeability:* Increased vascular permeability, (*ie.*, intraneural edema formation), was seen after compression at 50 mm Hg for 2 minutes. *5 Impulse propagation:* Impaired impulse propagation was observed as a decrease in recorded MAP-amplitude after compression at 100 mm Hg for 2 hours. The rapid compression onset rate was found to induce more pronounced effects than the slow onset rate in experiments 3, 4 and 5.

In conclusion, a model for experimental studies of nerve root compression has been developed and defined regarding normal neural and vascular anatomy. Changes in nerve root nutrition and function were induced at low pressure levels. The compression onset rate was found to be of importance for the degree of observed effects.

Key Words: Nerve root, cauda equina, pig, compression, onset rate, blood flow, nutrition, vascular permeability, EMG, nerve function.

ISBN 91-7900-963-8

Correspondence to Kjell Olmarker, Lab Experimental Biology, Department of Anatomy, University of Göteborg, Box 33 031, S-400 33 GÖTEBORG, Sweden.

This thesis is based on the following papers, which will be referred to in the text by their Roman numerals:

I Olmarker K, Holm S, Rosenqvist A-L & Rydevik B. 1990.
Experimental nerve root compression. Presentation of a model for acute, graded compression of the porcine cauda equina, with analyses of neural and vascular anatomy. *Spine (In press)*

II Olmarker K, Rydevik B, Holm S & Bagge U. 1989.
Effects of experimental, graded compression on blood flow in spinal nerve roots. A vital microscopic study on the porcine cauda equina. *J Orthop Res 7:817-823*

III Olmarker K, Rydevik B, Hansson T & Holm S. 1990.
Compression-induced changes of the nutritional supply to the porcine cauda equina. *J Spinal Dis 3:25-29*

IV Olmarker K, Rydevik B & Holm S. 1989.
Edema formation in spinal nerve roots induced by experimental, graded compression. An experimental study on the pig cauda equina with special reference to differences in effects between rapid and slow onset of compression. *Spine 14:569-573*

V Olmarker K, Holm S & Rydevik B. 1990.
Importance of compression onset rate for the degree of impairment of impulse propagation in experimental compression of the porcine cauda equina. *Spine (In press)*

CONTENTS

RESULTS AND COMMENTS

GENERAL DISCUSSION

LABORATORY OF EXPERIMENTAL BIOLOGY · GÖTEBORG ·

INTRODUCTION

Spinal nerve roots are often subjected to mechanical deformation in various disorders of the spine, ranging from acute spine trauma to degenerative conditions. Nerve root deformation can be related to clinical symptoms such as pain and neurological deficit in back and legs, and is therefore usually referred to the Low-back pain syndrome (LBP). Low-back pain, (*ie.*, pain in the lumbar back with or without pain in the lower extremities), is a condition that has been reported to affect as much as 80% of the population to the extent that they are unable to work at their original occupation (Nachemson 1985). However, approximately 60% of the patients are back to work within one week and only about 10% suffer disabling back pain after six weeks (Nachemson 1985). The high incidence of low-back pain, combined with absence from work for weeks to months, has made low-back pain one of the most expensive disorders for society (Weinstein *et al* 1989). If we could increase our knowledge of the basic mechanisms behind the symptoms of low-back pain we might be able to design better treatment modalities that, in a wider perspective, may be beneficial for a considerable number of patients, as well as accomplish great savings in health care expenses.

The pain of the low-back pain syndrome is located mainly in the lumbar spine or in the lower extremities (Nachemson & Andersson 1982). If the lumbar type of pain is present only with certain movements or positions of the back it is called *insufficientia dorsi*. If such pain is persistent, however, it is called *lumbago*. Pain radiating out into the hip or to the lower extremities is termed *sciatica*. It may coincide with *lumbago* and is then called *lumbago-sciatica*. Sciatica is often accompanied by neurological symptoms such as muscle weakness and impaired reflexes or sensibility. If the the distribution of the pain and the neurological symptoms can be referred to a derma-, or myotome of a specific spinal nerve, it may also be called a *rhizopathy* (Nachemson & Andersson 1982).

As suggested by the name "sciatica", this complex of symptoms was first considered to be the result of a local affection in the region of *os ischii*. However, in the beginning of the century there were a number of independent clinical observations that suggested that the pathogenetical mechanisms of sciatica instead might be located to the lumbosacral spine (Sachs & Fraenkel 1900, Bailey & Casamajor 1911, Goldthwait 1911). In 1926, Schmorl reported the existence of nodules, originating from the disc tissue, which protruded into the adjacent vertebrae, the abdominal cavity, or the spinal canal (Schmorl 1926). The author assumed that the nodules that protruded into the vertebrae was the only type that could cause pain. These intravertebral nodules, which now are called "Schmorl's nodes", can often be seen with X-ray examination of the spine. It is, however, not known if they can cause spinal pain. The nodules that involved the content of the spinal canal was not considered being a clinical problem at that time. It was not until 1934 that Mixter and Barr realized that there was a correlation between these "intraspinal nodules" and sciatica (Mixter & Barr 1934). Light microscopy showed that these nodules, which earlier also had been considered to be cartilage tumors, in fact comprised disc tissue. The authors suggested that the disc had "slipped" out into the spinal canal and that the disc material in this way was able to compress the nerve roots towards the bone structures of the spine. It has later been noted that this "slipped disc" instead rather is a protrusion or herniation of disc material, and that it is more correct to talk about a disc protrusion or a disc herniation instead of a "slipped disc".

Since Mixter & Barr's paper, the main research efforts in the field of low-back pain have been focused on the intervertebral disc (Holm *et al* 1981, Holm & Urban 1987, Maroudas 1982, Nachemson & Elfström 1970, Nachemson 1976, Urban *et al* 1977, 1982), thus leading to substantial knowledge about the physiology and the pathology of

the intervertebral discs. The basic mechanisms for the development of symptoms in sciatica is, however, still incompletely known.

One important pathogenic factor for the symptoms in sciatica is probably mechanical deformation, particularly compression, of the spinal nerve roots. The nerve roots may be compressed as the result of i) spine trauma, ii) protrusion or herniation of disc material, iii) inflammatory changes, iv) intraspinal tumors, and v) stenosis of the spinal canal (Arnoldi *et al* 1976). The latter, which is also referred to as " central spinal stenosis" may be congenital-developmental or acquired (Verbiest 1954, Arnoldi *et al* 1976). The congenital-developmental spinal stenosis may either be idiopathic or achondroplastic. The acquired form of spinal stenosis may have a number of different causes, for instance degenerative changes including facet-joint arthritis, (pseudo)-spondylolysis, spondylolisthesis and spondylosis. It may also be the result of miscellaneous disorders such as Paget's disease and fluorosis (Arnoldi *et al* 1976). The degenerative changes underlying spinal stenosis mainly comprise enlargement of facet-joints (Ghormley 1933, Mooney & Robertson 1976, Burton 1984) and ossification of spinal ligaments (Hasue *et al* 1983). If the narrowing of the spinal canal only involves the lateral parts it may also be called a lateral recess syndrome or a root entrapment (Ciric *et al* 1980, Crock 1981, Burton 1984, Porter *et al* 1984).

Since compression injury of the spinal nerve roots may be an important pathogenic factor for the development of symptoms in sciatica, it is surprising that there have been only a few experimental studies on nerve root compression. This might be due partly to the fact that the spinal nerve roots are enclosed by bone and ligaments. Therefore they require a more complex surgical exposure than do most peripheral nerves, in experimental as well as clinical situations.

There are at least three criteria that should be fulfilled by a suitable experimental model of nerve root compression; 1) the nerve roots should be of an adequate length to allow experimental analyses of various parameters, 2) the spinal cord should be absent in the preparation to facilitate neurophysiologic recordings, and 3) it would be preferable to have the site of compression at as low a segmental level as possible to limit any neurologic deficit in a chronic situation. These criteria thus suggest that the cauda equina would be suitable for nerve root studies. However, most of the readily available experimental animals do not have a cauda equina. The complex surgical approach combined with this shortage of experimental animals with a cauda equina might explain why there is an almost complete absence of information on the reaction of spinal nerve roots to compression trauma in the literature. The results of the few previous experimental studies on nerve root compression indicate that spinal nerve roots might be more susceptible to compression injury than the peripheral nerves (Gelfan & Tarlov 1956, Sharpless 1975). However, no critical pressure levels for negative influence of compression on nerve root nutrition or function have been determined. Information on the effects of compression on spinal nerve roots can not be directly extrapolated from studies on peripheral nerves, due to anatomical differences (Murphy 1977, Rydevik *et al* 1984).

LITERATURE REVIEW

MACROSCOPIC ANATOMY OF SPINAL NERVE ROOTS

The nerve roots are the link between the central and the peripheral nervous systems. The nerve fibers leave the spinal cord as small rootlets or *fila radicularia*, which caudally converge into common nerve root trunks. These nerve roots run within the spinal canal and leave it through one of the intervertebral foramina, which are formed by pedicles, articular processes and vertebral bodies of two adjacent vertebrae, including the intervertebral disc, (Figure 1). By definition, the dorsal nerve roots end at the dorsal root ganglion. The ventral nerve roots end at a corresponding level.

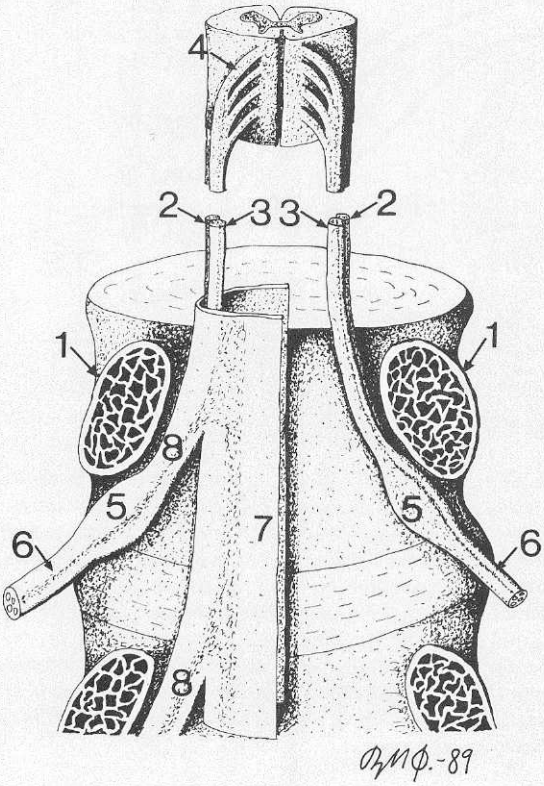

Figure 1. *Drawing of the intraspinal course of a human lumbar spinal nerve root segment. The vertebral arches have been removed, by cutting the pedicles (1), and the opened spinal canal can be viewed from behind. The ventral (2) and dorsal (3) nerve roots leave the spinal cord as small rootlets (4) that caudally converge into a common nerve root trunk. Just prior to leaving the spinal canal, there is a swelling of the dorsal nerve root called the dorsal root ganglion (5). Caudal to the dorsal root ganglion, the ventral and the dorsal nerve roots mix and form the spinal nerve (6). The spinal dura encloses the nerve roots both as a central cylindrical sac (7), and as separate extensions called root sleeves (8).*

In the early embryologic states, the part of the spinal cord from which the nerve root emerges, is located near its corresponding intervertebral foramen. However, the spinal cord will not grow as much as the spinal column, and in the fully grown human the spinal cord ends, as the *conus medullaris*, approximately at the level of the 1st lumbar vertebra. Due to this relative elevation of the spinal cord, called *ascencis spinalis*, the sacral and lumbar nerve roots have to be much longer to reach their respective intervertebral foramina than for instance the nerve roots in the cervical spine. Below the level of the *conus medullaris*, there is thus no spinal cord present. Instead there are lumbar, sacral and coccygeal nerve roots that run in a common bundle. Due to its apparent resemblance to a tail of a horse, this formation of the nerve roots in the lumbar and sacral spinal canal has been named *cauda equina* (*ie.*, horse tail).

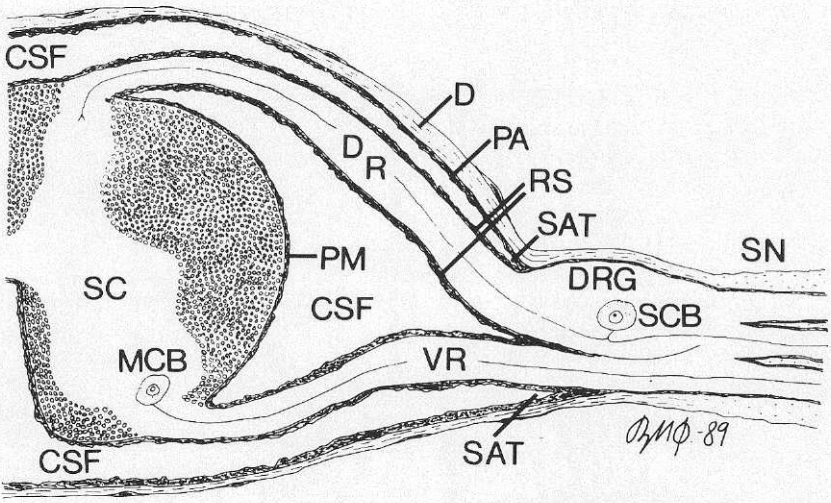

Figure 2. *Cross-section of a segment of the spinal cord (SC), a ventral (VR) and a dorsal (DR) spinal nerve root. The cell bodies (MCB) of the motor axons, which run in the ventral nerve root, are located in the anterior horn of the gray matter of the spinal cord. The cell bodies (SCB) of the sensory axons, which run in the dorsal nerve root, are located in the dorsal root ganglion (DRG). The ventral and dorsal nerve roots blend just caudal to the dorsal root ganglion, and form the spinal nerve (SN). The spinal cord is covered with the pia mater (PM). This sheath continues out on the spinal nerve roots as the root sheath (RS). The root sheath reflects to the pia-arachnoid (PA) at the subarachnoid triangle (SAT). Together with the dura (D), the pia-arachnoid forms the spinal dura. The spinal cord and nerve roots are floating freely in the cerebrospinal fluid (CSF) in the subarachnoid space.*

At each spinal level, on both the right and the left side, there are ventral and dorsal nerve roots (*radix ventralis et radix dorsalis*), (Figure 2). Information from the body to the central nervous system is transmitted by afferent axons that run in the dorsal nerve root. The dorsal nerve root is therefore also referred to as the "sensory root". Conversely, information from the central nervous system to the body is transmitted by efferent axons that run in the ventral nerve root, or "motor root". This anatomic arrangement has been called the "law of Magendie" (Hildebrand *et al* 1989). Recently, this arrangement was questioned due to the fact that unmyelinated afferents were found in the ventral root (Coggeshall *et al* 1974). However, these axons have been found to innervate the leptomeninges and vessels of the ventral nerve root and the ventral parts of the spi-

nal cord, and that they in fact enter the spinal cord through the dorsal nerve roots (Hildebrand *et al* 1989).

The sensory cell bodies, or neurons, are located in the dorsal root ganglion (DRG) close to the intervertebral foramen (Hasue *et al* 1989), (Figure 2). The smallest dorsal root neurons (less than 20 µm diameter) have been suggested to transmit pain impulses, the medium-sized neurons to transmit impulses from the viscera, and the largest neurons (over 100 µm diameter) to transmit temperature, tactile, and proprioceptive impulses (Tennyson & Gershon 1984). These neurons also produce substance "P" and "VIP", substances which have been suggested to be possible mediators of pain (Weinstein *et al* 1987, -88). Each dorsal root neuron has two axons. One approach the neuron via the spinal nerve, and one runs from the neuron towards the spinal cord in the dorsal nerve root. Just caudal to the DRG, the axons of the motor and sensory nerve root blend and form a mixed nerve of both afferent and efferent axons, called the spinal nerve *(n spinalis)*, (Figures 1 & 2).

MEMBRANOUS COVERINGS OF SPINAL NERVE ROOTS

The spinal dura encloses the spinal cord, the cerebrospinal fluid and the spinal nerve roots, (Figure 2). It is partly derived from the cranial *dura mater*. Upon entering the spinal canal, the two layers of the cranial *dura mater* are separated. The inner layer joins the arachnoid, to become the spinal dura (Waggener & Beggs 1967, McCabe & Low 1969). The general opinion of the fate of the outer layer is that it blends with the periosteum of the vertebrae facing the spinal canal. However, an "epidural" or "extradural membrane", which is a membranous structure between the spinal dura and the periosteum of the parts of the vertebrae facing the spinal canal, was recently found in the lumbar spinal canal in man (Dommisse 1975, Hasue *et al* 1983). This suggests that there actually might be a free continuation of the outer layer of the cranial dura down through the spinal canal.

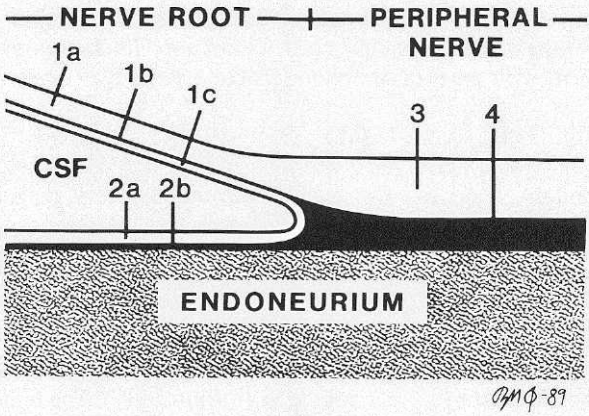

Figure 3. *The relation of the different structures at the "subarachnoid triangle", the location where the nerve root becomes a peripheral nerve. The spinal dura (1) and the root sheath (2) join and form the epineurium (3) and the perineurium (4) of the peripheral nerve. The spinal dura (1) comprises the dura (1a), the "inner subdural neurothelium" (1b), and the pia-arachnoid (1c). The dura (1a) continues directly as the epineurium (3). The pia-arachnoid (1c) reflects down to the nerve root and forms the outer layer of the root sheath (2a). Together with the inner layer of the nerve root (2b), the "inner subdural neurothelium" (1b) forms the perineurium (4).*

The spinal dura forms a cylindrical sac that encloses the nerve roots of the cauda equina (Cohen *et al* 1990, Rauschning 1983, -87). When located within this cylinder, the nerve roots may be referred to as "intrathecal" (Wall *et al* 1990). At a certain level of the spinal canal, the nerve root pair (*ie.*, a ventral and a dorsal nerve root from the same spinal segment), leave this central dural sac. As their course continues through the spinal canal, they are instead enclosed by a separate extension of the spinal dura, called a root sleeve, (Figures 1 & 2). This location of the nerve root is generally referred to as "extrathecal" (Wall *et al* 1990).

Between the endoneurium of the nerve roots and the cerebrospinal fluid there is a structural analogue to the pia of the spinal cord called the root sheath, (Figures 2 & 3). This root sheath is usually formed by 3-4 layers of cells (Haller & Low 1971, Steer 1971). However, as many as 12 layers of cells have been observed in some species (Haller & Low 1971). The outer layers comprise loosely arranged cells which are similar to pia cells in the cranial half, and to arachnoid cells in the caudal half of the nerve roots (McCabe & Low 1969). The cells are joined by intermittent junctions and thus constitute a poor diffusion barrier (Haller & Low 1971). The cells of the inner layers, however, are more similar to the perineurial cells of peripheral nerves. They are joined by desmosomes and are tightly packed together. The cells are enclosed by basal membranes. However, unlike the basal membranes in the perineurium of peripheral nerves, their occurrence is irregular in the root sheath. There is also a scarcity of collagen (Steer 1971). Although the origin of the inner cells of the root sheath is debated, there is a general agreement that the barrier function of the root sheath is delegated to these cells and their basal membranes.

The arterioles and venules of the nerve roots are located in the outer layers of the root sheath where they are enclosed by root sheath cells, also called "epi-pial tissue" (Waggener & Beggs 1967). The root sheath also forms "pial investments" which enclose the separate fascicles of the nerve roots.

The root sleeve, and its contents (ventral and a dorsal nerve root, cerebrospinal fluid and at a certain level the dorsal root ganglion) are usually referred to as the "nerve root" in the clinical situation. The term "nerve root" should, however, strictly be used for the nerve tissue that runs from the spinal cord within the subarachnoid space. Thus, it would be better to refer to the root sleeve and its contents as the "nerve root complex".

MICROSCOPIC ANATOMY OF SPINAL NERVE ROOTS

The axons of the spinal nerve roots are located in the endoneurial space, in which they are surrounded by connective tissue called the endoneurium, (Figure 3 & 4). There are unmyelinated and myelinated axons in both ventral and dorsal nerve roots. The diameters of the myelinated axons of the human nerve roots range between 1.5 and 16 µm, and the unmyelinated axons range between 0.4 and 1.6 µm (Gamble & Eames 1966).

In 1887, Thomsen observed that the organisation of the nerve root endoneurium is separated into a "central glial segment" and a "peripheral non-glial segment" (Thomsen 1887). The glial-segment has a microscopic anatomy that resembles that of the brain, with astrocytes, oligodendrocytes and microglia (Tarlov 1937). The non-glial segment is more similar to a peripheral nerve, but has small islets of neuroglia. The two segments have a "dome-shaped" junction 1-3 mm after the rootlets leave the spinal cord (Tarlov 1937, Berthold *et al* 1984).

The endoneurium also contains longitudinally oriented collagen fibrils (550 Å maximum diameter), fibroblasts and blood vessels (Gamble & Eames 1966). However, unlike peripheral nerves, the endoneurium of a nerve root does not contain mast cells (Gamble 1964). The total amount of protein in nerve roots is only a fifth of peripheral nerves, but six times more than the spinal cord (Stodieck *et al* 1986).

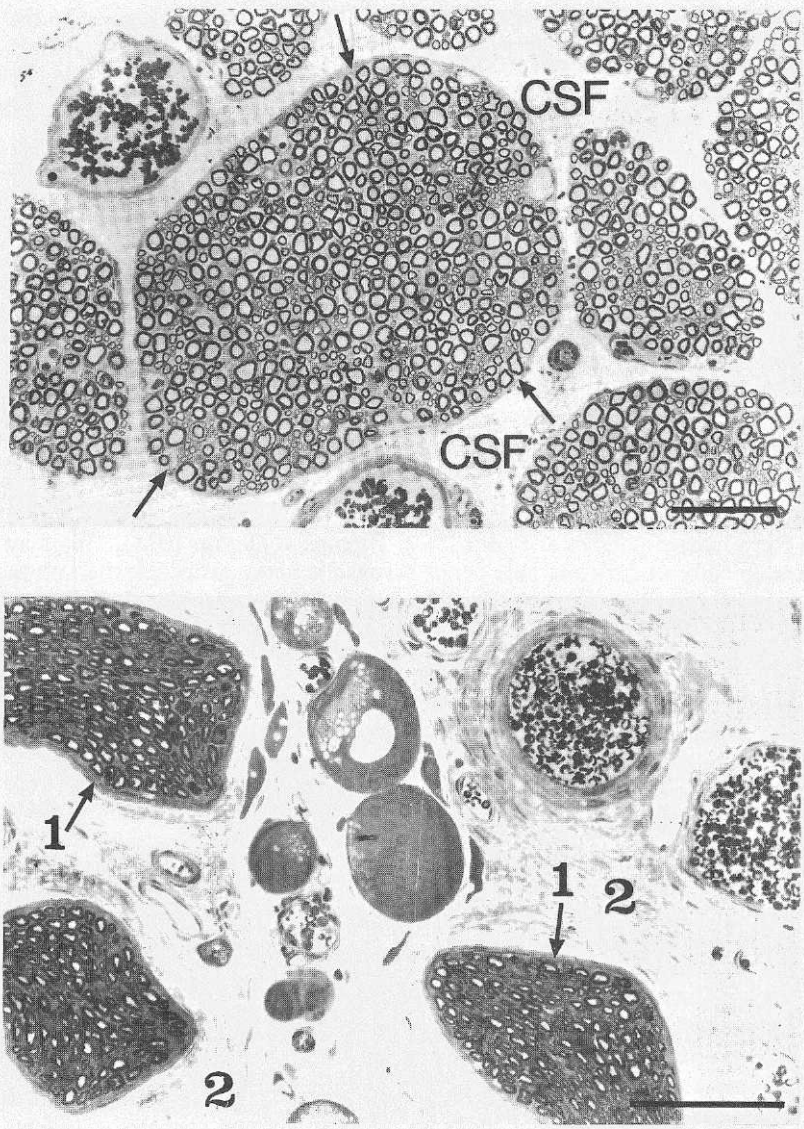

Figure 4. (Top) *The axons of the spinal nerve roots are located in the endoneurium, which is enclosed only by the thin root sheath (arrows) and cerebrospinal fluid (CSF), (Cauda equina from pig, Stain: Richardsson, Bar = 100 μm).* (Bottom) *The endoneurium of the peripheral nerves is similar to that of the nerve roots. In the peripheral nerve, however, the axons are enclosed by the perineurium (1) and the epineurium (2). Blood vessels are located between the different nerve fascicles in the epineurium, (N tibialis from rabbit, Stain: Richardsson, Bar = 100 μm).*

MICROSCOPIC ANATOMY OF PERIPHERAL NERVES

Peripheral nerves have morphological features which differ from those of spinal nerve roots, (Figure 4). The epineurium, which encloses the different fascicles, is comprised of loose connective tissue, collagen fibrils (60-110 nm diameter), fibroblasts, mast cells, and blood vessels (Thomas & Olsson 1984). Unlike spinal nerve roots and other parts of the peripheral nerve, a network of lymphatic vessels is present in the epineurium (Sunderland 1965). The epineurium probably also protects the axons from mechanical injury since it is more developed at locations where the nerves may be subjected to mechanical irritation, for instance at joints or where the nerves run superficially (Sunderland 1965).

The axons of the peripheral nerves are enclosed by a mechanically strong structure called the perineurium (Thomas & Olsson 1984), (Figure 4). The perineurium may protect the axons in the peripheral nerve from both injury due to elongation and to compression (Sunderland 1978). The perineurim is formed by up to 15 lamellated cellular layers of flattened polygonal cells that are joined by tight junctions (Thomas & Jones 1967, Shanta & Bourne 1969). The perineurium has been shown to serve as a diffusion barrier that prevents substances from penetrating into the endoneurial space towards the axons (Olsson & Reese 1969, -71b, Klemm 1970, Lundborg *et al* 1973, Rydevik & Lundborg 1977).

The axons are located in the endoneurial space, which is similar to that of the nerve root (Thomas & Olsson 1984). The content of an endoneurial space, together with its surrounding perineurium, is called a nerve fascicle. The endoneurial space is comprised of fibroblasts and collagen fibrils. To compensate for elongation, the axons run in a wave-form pattern (Clarke & Bearn 1972, Thomas & Olsson 1984). This may be seen macroscopically as dark and pale bands across the nerve fascicles when observing the nerve trunk in incident light, and have been named "the spiral bands of Fontana". This anatomical feature has not been observed in spinal nerve roots (Sunderland 1978).

DIFFUSION BARRIERS OF IMPORTANCE FOR THE SPINAL NERVE ROOTS

There are three diffusion barriers within the cauda equina that may be of importance for the nerve roots, A) between the epidural and the subarachnoid space, B) between the subarachnoid and the endoneurial space, and C) between the endoneurial space and the lumen of the endoneurial capillaries, (Figure 5).

In the cauda equina, the spinal dura encloses the cerebrospinal fluid and the nerve roots. To prevent leakage of cerebrospinal fluid out into the epidural space, the spinal dura has to have certain barrier properties. This barrier function has been attributed to cells that are similar to the cells of the perineurium of peripheral nerves, and which have been called "the inner subdural neurothelium" (Andres 1967) or "perineurial cells" (McCabe & Low 1969). This layer of cells has been found to be continuous with the perineurium of the spinal nerve caudally (Andres 1967, McCabe & Low 1969), (Figure 3). The cells are located between the dura and the arachnoid, and the thickness of this cellular layer is most pronounced in the parts of the spinal dura that covers the dorsal root ganglion. Between the cells there are desmosomes and *zonulae occludentes*, which suggests that this layer may act as a diffusion barrier (Arvidson 1979a). Horseradish peroxidase and ferritin, locally applied to cervical root ganglions in rats, do not penetrate to the endoneurium (Arvidson 1979a). There are only few experimental studies on the permeability of the parts of the spinal dura not covering the root ganglion (Moore *et al* 1982). However, in connection with epidural morphine treatment it has been suggested that morphine may reach the subarachnoid space by passing directly through the spinal dura (Bromage 1978, Yaksh & Reddy 1981), via archnoid villi that penetrate the dura

(Welch & Pollay 1963, Hammerstad *et al* 1969), or via blood vessels that penetrate the dura (Yaksh 1981).

As discussed previously, the inner cells of the root sheath probably form a barrier between the subarachnoid space and the endoneurium of the spinal nerve roots. The electron microscopic appearance, however, indicates that this is a poor diffusion barrier as compared to the barrier of the spinal dura (Haller & Low 1971, Steer 1971). There are no experimental studies on the barrier function of the root sheath. However, there is evidence that fluorescein labelled serum proteins do not pass through the pia of the spinal cord, which is a structure that has certain similarities to the root sheath (Klatzo *et al* 1964). The blood vessels that run in the outer layers of the root sheath may be able to exchange molecules with the cerebrospinal fluid relatively freely, since they are located outside this potential diffusion barrier.

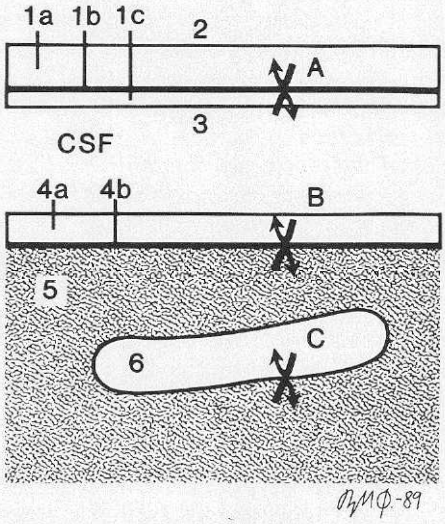

Figure 5. *There are three important diffusion barriers within the cauda equina. A) The "inner subdural neurothelium" (1b), between the dura (1a) and the pia-arachnoid (1c) of the spinal dura, is a barrier between the epidural space (2) and the cerebrospinal fluid (CSF) in the subarachnoid space (3). B) The inner layers of the root sheath (4b) is a barrier between the subarachnoid space (3) and the endoneurial space of the nerve root (5). C) Between the endoneurial space (5) and the lumen of the endoneurial capillaries (6), there is a barrier similar to the blood-nerve barrier of peripheral nerves. (4a is the outer cell layers of the root sheath).*

Similar to the blood-brain barrier, there is a blood-nerve barrier in peripheral nerves (Waksman 1961, Olsson 1966). The presence of such a barrier within the nerve roots has been questioned. Olsson (1968) showed that serum albumin leaked normally from the endoneurial capillaries into the endoneurium within 2-24 hours after injection, although not as much as in the dorsal root ganglion or in the epineurium of peripheral nerves. This phenomenon was found to be present in most experimental animals, including rhesus monkeys and chimpanzees (Olsson 1971a). The endoneurial capillaries are fenestrated in the dorsal root ganglion (Olsson 1971a, Jacobs 1976, Arvidson 1979b). This results in a relatively free passage of macromolecules between the capillaries and the endoneurial space. Noxious agents, for instance diphtheria toxin, may therefore easily reach the sensory cell bodies. However, the question still remains whether the diffe-

rence in permeability between nerve root capillaries and ganglion capillaries is based solely on the fenestration of the latter, or if there is a blood-nerve barrier present in the nerve root endoneurium. If such barrier should exist, it is not as well developed as the corresponding barrier of peripheral nerves, which implies that intraneural edema may be formed more easily in nerve roots than in peripheral nerves.

NUTRITION OF SPINAL NERVE ROOTS

Nerve tissue needs a continuous supply of nutrients to function properly. Although the metabolic processes of the neuron are located mainly in the soma, the axon itself is dependant on a local nutritional supply along its course (Lundborg 1970, -88). Similar to the peripheral nerves, the spinal nerve roots are provided with a system of intrinsic, nutritive blood vessels. However, the arteriolar and venular networks of spinal nerve roots are not as well developed as in the peripheral nerves (Parke *et al* 1981, Petterson & Olsson 1989). The spinal nerve roots also receive nutritional contribution via diffusion from the cerebrospinal fluid (Rydevik *et al* 1990a).

VASCULAR ANATOMY OF SPINAL NERVE ROOTS

The vascular anatomy of the nervous structures of the spinal canal was originally described in the last decades of the nineteenth century (Duret 1873ab, Adamkiewicz 1881, -82, Kadyi 1886). Adamkiewicz' works were particularly important for the general concept of the vascularisation of these structures, and his findings were to be predominant for the coming six to seven decades (Adamkiewicz 1882). Adamkiewicz found that, instead of being a continuous vessel, the *a spinalis anterior* was formed by fusions of segmental arteries. These segmental arteries were of different sizes and often supplied more than one segment of the spinal cord. The most important of these arteries was found in the thoracic spine and has been named after the author, (see below). These observations were also confirmed by Tanon in 1908.

Except for some occasional reports (Suh & Alexander 1939, Herren & Alexander 1939) there was no particular interest in the blood supply of the spinal cord and roots during the first half of this century. However, a rising interest in the capability of the spinal cord to recover from vascular lesions and its reaction to vascular surgery initiated a number of investigations on the collateral circulation of the spinal cord arteries (Adams & van Geertruyden 1956, Fried & Doppman 1958, Gillian 1958, Corbin 1961, Lazorthes *et al* 1966, -71, Crock & Yoshizawa 1976, Dommisse 1976).

Knowledge of the vascularisation of the spinal nerve roots is mainly derived from studies on spinal cord vascularisation. However, there have been at least two theses on spinal nerve root vascularisation (Desproges-Gotteron 1955, Viraswami 1963). The anatomy of the nerve root vessels has been described based upon the cord vasculature, and the nomenclature of the nerve roots vessels is inconsistent in the literature. Parke and collaborators recently proposed a new terminology for the different vessels of the lumbo-sacral spinal nerve roots (Parke *et al* 1981, Parke & Watanabe 1985). The following presentation will try to provide a summary of the current concept of the vascularisation of the spinal nerve roots of the cauda equina.

The segmental arteries from the *aorta* and the *a. iliaca communis* divide into three major branches; i) an anterior branch, which supplies the posterior abdominal wall and the lumbar plexus, ii) a posterior branch, which supplies the paraspinal muscles and facet-joints, and iii) an intermediate branch. The intermediate branch in turn generally divides into three subdivisions; i) anterior spinal branches, which supply the posterior aspects of the vertebral bodies and discs, ii) posterior spinal branches, which supply the vertebral arches, the epidural fat and the spinal dura, and iii) nervous system branches (Crock & Yoshizawa 1976), (Figure 6).

The nervous system branches into i) medullary feeder arteries (extrinsic system), which supply the arteries of the spinal cord without giving any branches to the nerve roots they are following along their course through the subarachnoid space, and ii) vessels that incorporate with either of the two nerve roots (intrinsic system), (Parke *et al* 1981). Thus, the vessels of the extrinsic system do not directly take part in the nutrition of the nerve roots. Embryologically, there are 124 medullary feeder arteries at 31 segmental levels. These arteries are soon reduced in number, and at birth there are only about 8 remaining (Parke *et al* 1981). Thus, medullary arteries each supply more than one segment of the spinal cord each (Lazorthes *et al* 1971).

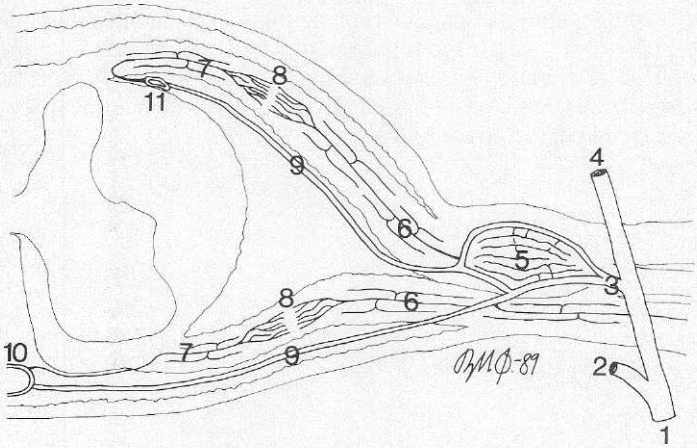

Figure 6. Schematic drawing of vascular supply to the spinal cord and nerve roots. *When the intermediate branch of the segmental artery (1) enters the spinal canal it divides into an anterior spinal canal branch (2), a nervous system branch (3), and a posterior spinal canal branch (4). The nervous system branch joins the nerve root and forms a ganglionic plexus (5) and caudal nerve root arteries running in cranial direction (6). From the vaso corona of the spinal cord there are cranial nerve root arteries (7) running in caudal direction. The caudal and the cranial nerve root arteries anastomoze within the cranial half of the nerve root (8). From the nervous system branch there are also medullary feeder arteries (9). These vessels run in cranial direction through the subarachnoid space, without any connections to the nerve root arteries, to the vasa corona of the spinal cord, where 10) is the anterior spinal artery and 11) is one of the two dorsolateral spinal arteries. (Adapted from Parke et al 1981).*

Anatomically and functionally the vascularisation of the spinal cord may be divided into three vascular domains; i) the cervicothoracic area, ii) the midthoracic area, and iii) the thoracolumbar area (Lazorthes *et al* 1971). The main medullary artery of the thoracolumbar area is usually derived from one of the segmental arteries of the 12th thoracic segment and was first described by Adamkiewicz in 1882. Although he called it the *"magnus ramus radicularis anterior"* it is now generally known as the "artery of Adamkiewicz".

The vessels that supply the ventral roots form 1-3 caudal radicular arteries that are located within the root sheath and run cranially, towards the spinal cord, and are part of the "intrinsic system". In the dorsal root, however, the corresponding vessels first form a "ganglionic plexus" around the dorsal root ganglion before they continue cranially as caudal radicular arteries. The caudal radicular arteries of both the ventral and the dorsal

roots anastomose with the cranial radicular arteries, which are derived from the vascular network of the spinal cord, at the cranial half of the nerve roots. Thus, blood flow is supplied from both cranial and caudal directions. At the location where these two vascular networks anastomose, the vasculature of the nerve roots is less developed. It has therefore been suggested that this region of a relative "hypo-vascularisation" may be a particularly vulnerable site of the nerve roots (Parke *et al* 1981, Parke & Watanabe 1985), (Figure 6).

The arteries of the intrinsic vessels are located mainly in the outer layers of the root sheath. Occasionally they are also found deeper in the nerve root tissue between, or even within the fascicles (Parke & Watanabe 1985). By "T"-like branchings, the arteries provide each fascicle with a number of parallel running interfascicular arterioles, (Figure 7). There are arterial coils and vascular loops present that will compensate for elongation of the vessels in both axial direction and between the fascicles (Parke & Watanabe 1985, Petterson & Olsson 1989). Within the fascicles, (*ie.*, in the endoneurial space), the endoneurial capillaries run parallel to the axons.

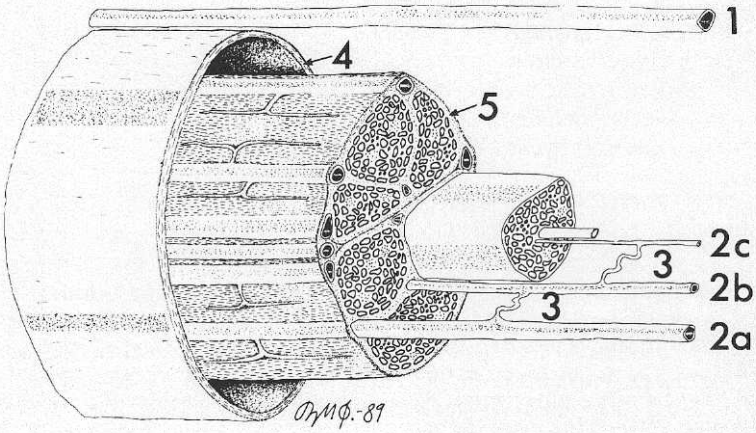

Figure 7. Schematic presentation of some anatomical features of the intrinsic arteries of the spinal nerve roots. *The arterioles within the cauda equina may be referred to either the extrinsic (1) or the intrinsic (2) vascular system. From the superficial intrinsic arterioles there are branches that continue almost at right angle down between the fascicles. These vessels often run in a spiraling course, thus forming vascular "coils" (3). When reaching a specific fascicle they branch in a T-like manner, with one branch running cranially and one caudally, forming interfascicular arterioles (2b). From these interfascicular arterioles there are small branches that enter the fascicles where they supply the endoneurial capillary networks (2c). Arterioles of the extrinsic vascular system run outside the spinal dura (4) and have no connections with the intrinsic system by local vascular branches. The superficial intrinsic arterioles (2a) are located within the root sheath (5). (Adapted from Parke & Watanabe 1985).*

The venous system has an organisation similar to the arteries. The largest veins, however, do not only course together with the corresponding arteries as in peripheral nerves (Lundborg 1970). Instead they also have a "spiraling" course deeper in the nerve roots (Parke & Watanabe 1985). The veins of the nerve roots also differ from the arteries as they occasionally drain through the spinal dura, out into the epidural venous plexus.

VASCULAR ANATOMY OF PERIPHERAL NERVES

The separation of the neural vascular systems into an extrinsic and an intrinsic system was originally suggested for peripheral nerves (Lundborg & Brånemark 1968, Lundborg 1970, -75). However, the definitions for peripheral nerves are not consistent with those for spinal nerve roots. In peripheral nerves, the extrinsic system is comprised of the vessels that join the nerve trunk from adjacent tissues along the course of the nerve. These vessels supply the intrinsic vessels of the peripheral nerves, and participate directly in the nutrition of the nerve tissue. This is different from the situation for the nerve roots, (see above). Hence, the peripheral nerves receive a continuous regional supply of blood along their course. This is one important difference from the vascular anatomy of spinal nerve roots which may be particularly important with compression at multiple levels.

Generally, the arteriolar and venular intrinsic networks are better developed in peripheral nerves than in spinal nerve roots (Parke & Watanabe 1985, Petterson & Olsson 1989). However, there is evidence that the capillary density is similar between peripheral nerves and nerve roots in rats (Nukada *et al* 1985, Petterson & Olsson 1989). In peripheral nerves, the vessels are often located between the fascicles, (Figure 4, page 13). They will therefore be relatively well protected from mechanical deformation. Both extrinsic and intrinsic vessels show a coiling course and frequent vascular loops (Lundborg 1975, -88). These two structural features, which probably allow adaptation to mild elongation, may also be found in the intrinsic vessels of the spinal nerve roots (Parke & Watanabe 1985, Petterson & Olsson 1989).

MORPHOLOGIC AND VASCULAR DIFFERENCES BETWEEN SPINAL NERVE ROOTS AND PERIPHERAL NERVES

Based on the description above one may summarize some of the morphologic and vascular differences between peripheral nerves and spinal nerve roots as follows:

* The axons of the nerve roots are enclosed by the thin root sheath, cerebrospinal fluid and meninges. The axons of the peripheral nerves are enclosed by the epineurium and the perineurium.
* There is less endoneurial collagen in spinal nerve roots than in peripheral nerves.
* The axons of a peripheral nerve are arranged as the "spiral bands of Fontana". This is not the case for spinal nerve roots.
* There is no fascicular branching in spinal nerve roots, as opposed to in peripheral nerves.
* The arteriolar and venular networks are less developed in spinal nerve roots than in peripheral nerves.
* There is no regional supply to the intrinsic vasculature of spinal nerve roots, unlike in peripheral nerves.
* The intrinsic vessels of the spinal nerve roots are mainly located superficially. In peripheral nerves, the vessels are often found deep in the epineurium, between the fascicles.
* The intrinsic vasculature of spinal nerve roots is formed by two separate networks. One coming from the *vasa corona* of the spinal cord and one from vessels at the intervertebral foramen. At the region where they anastomose there is an area of "hypovascularity" that may be particularly susceptible to mechanical deformation.

These anatomical characteristics of spinal nerve roots have been suggested to make the spinal nerve roots more susceptible to compression trauma than the peripheral nerves (Murphy 1977, Rydevik *et al* 1984, Parke & Watanabe 1985).

EFFECTS OF ACUTE COMPRESSION ON NERVE TISSUE

When a nerve is compressed there are both direct mechanical effects and effects upon the transport of nutrients to the nerve that might affect both nerve structure and function. The mechanical effects include deformation of nerve fibers, displacement of the nodes of Ranvier and invagination of the paranodal myelin-sheath (Edwards & Cattell 1928, Ochoa *et al* 1972, Rydevik & Nordborg 1980a). These effects are rarely seen at pressure levels below 200 mm Hg. Small diameter myelinated fibers are less affected than large diameter myelinated fibers, and unmyelinated fibers are less affected than myelinated fibers (Gasser & Erlanger 1929, Fowler & Ochoa 1975, Ochoa *et al* 1972, Dahlin *et al* 1989). Since the unmyelinated fibers are smaller than the myelinated fibers, the fiber-size seems to be crucial for the susceptibility to compression trauma of the individual axon. This also corresponds to *in vitro* studies on pressure-vessel models of nerve compression, which have shown that large diameter fibers are deformed more than small diameter fibers (MacGregor *et al* 1975).

At low pressure levels it is more likely that the effects on the normal function of the nerve tissue is due to an impairment of its nutritional supply than direct mechanical effects on the axons (Dahlin *et al* 1986a). In peripheral nerves, the blood flow in the intraneural venules is impaired already at compression at pressure levels of 20-30 mm Hg (Rydevik *et al* 1981). At slightly higher pressure levels there is an impairment of the blood flow in the endoneurial capillaries. The nerve is completely ischemic when exposed to a pressure close to the mean arterial blood pressure. An *in vivo* experimental study on *n medianus* in the carpal tunnel in human volunteers has shown that pressures of about 30 mm Hg produces slight sensory changes and pressures of 60-90 mm Hg produce complete sensory and motor block (Lundborg *et al* 1982).

Compression may also affect the normal barrier function of the endoneurial capillaries. The permeability of vessel walls for macromolecules may drastically increase, with subsequent intraneural edema formation. Such edema has been observed in peripheral nerves following compression at 50 mm Hg for 4-6 hours (Rydevik & Lundborg 1977). The barrier function of the epineurial vessels is less developed and edema may be seen following compression at 50 mm Hg for 2 hours (Rydevik & Lundborg 1977). Endoneurial edema may increase the endoneurial fluid pressure (Low & Dyck 1977, Myers & Powell 1981, Lundborg *et al* 1983). In this way edema formation may impair the blood flow in nerve fascicles (Myers *et al* 1982, Myers & Powell 1984, Low *et al* 1982, -85). A longstanding edema may also be related to the formation of an intraneural fibrotic scar (Lundborg 1975, Rydevik *et al* 1976). Intraneural edema formation may therefore affect the nutrition and function of the spinal nerve roots even after the compression has been ended.

The effects of local compression seems to be most pronounced at the edges of the compression zone (Bentley & Schlapp 1943, Edwards & Cattell 1928, Ochoa *et al* 1972, Rydevik & Lundborg 1977). This is probably based on the displacement of nerve tissue from the compressed to the uncompressed parts of the nerve (Rydevik *et al* 1984, -89b). The superficial parts of the nerve are have been suggested to be displaced more than the deeper parts. Shearing may thus occur between the different layers of the nerve, that is most pronounced at the edges of the compressed nerve segment (Rydevik *et al* 1984, -89b).

Compression at 20-30 mm Hg may induce changes in axonal transport in both anterograde and retrograde directions (Rydevik *et al* 1980b, Dahlin *et al* 1984, -86b, Dahlin & McLean 1986c). If compression at this pressure level is prolonged, there will be an impaired transport of proteins within the axons, which might result in a higher sensitivity for compression-induced efects in the caudal axonal segment, the so-called "double-crush syndrome" (Upton & McComas 1973).

EFFECTS OF COMPRESSION ON SPINAL NERVE ROOTS

The effects of compression on nerve tissue have mainly been investigated on peripheral nerves. However, there are some studies that have specifically concentrated on the effects on spinal nerve roots.

In 1956, Gelfan and Tarlov studied the effects of compression on spinal cord, nerve roots and peripheral nerves (Gelfan & Tarlov 1956). The authors used a compression device that was made of a syringe that, when inflated by a compressed-air system, compressed the nerve tissue between two foam-rubber surfaced metal plates. The study showed that the spinal cord and nerve roots seemed to be less resistant to compression than peripheral nerves. However, the compression device for peripheral nerves was never calibrated and therefore no exact comparison could be made between the effects on spinal nerve roots and peripheral nerves.

Using a fluid-filled balloon with connected pressure transducer, Sharpless compared the effects of compression on conduction properties of peripheral nerves and spinal nerve roots (Sharpless 1975). The study indicated that spinal nerve roots where more sensitive to compression than peripheral nerves and that very low pressures might interfere with the normal conduction of spinal nerve roots.

Recently, Yoshizawa and collaborators developed a model for experimental studies on blood flow in single lumbar nerve roots in dogs (Yoshizawa *et al* 1989a). Using a microvascular suture clip, the 6th lumbar nerve root was compressed. The compression force of the clamp was estimated to approximately 60 gram, a measurement that is difficult to translate to those of the present investigation. The blood flow of the nerve root was measured using an electrochemically generated hydrogen washout technique. The study indicated that the blood flow was more impaired on the cranial side than the caudal side during compression. When ending the compression, the blood flow was almost completely restored on the cranial side of the clip. However, the blood flow on the caudal side stayed at the reduced level. In another study, the authors found that the blood flow in the dorsal root ganglion, which was approximately 56 ml/100g/min, was twice as much as the blood flow in the corresponding nerve roots (Yoshizawa *et al* 1989b).

Delamarter and collaborators have studied the effects of prolonged compression of the cauda equina in dogs (Delamarter *et al* 1990). The cauda equina was acutely constricted by 25%, 50% or 75% of its initial circumference using a nylon band. The constriction was maintained for 3 months. There were no or only initial neurologic deficits in the 25% or 50% constriction series. However, the series with 75% constriction demonstrated paraplegia. Changes in cortical evoked potentials were seen in the 50% and in the 75% constriction series. Vascular congestion and histologic changes were mild in the 25%, moderate in the 50%, and severe in the 75% constriction series.

In conclusion, previous experimental studies indicate that spinal nerve roots seem to be more sensitive to compression than peripheral nerves. However, no critical pressure levels for compression-induced impairment of function or nutrition of the spinal nerve roots have been determined.

PRESSURE LEVELS IN NERVE ROOT COMPRESSION SYNDROMES

There is no knowledge of the exact pressure levels that are exerted on spinal nerve roots in various nerve root compression conditions. There are, however, some experimental findings that may indicate which pressure levels could be expected.

Spencer and co-workers have studied the force that acts on a nerve root, with a simulated disc protrusion, when the nerve roots are under tension in a cadaveric model (Spencer *et al* 1984). A probe, inserted through an emptied disc space, was allowed to contact on a nerve root. Due to the fact that the nerve root, or rather the spinal dura, is

fixed to the spinal canal, a contact force between the nerve root and the probe was recorded when the probe was moved in dorsal direction. The pressure on the nerve roots was calculated to be 400 mm Hg or more. However, since the nerve root itself is not fixed in the same manner as the meninges, this pressure probably reflects the tension in the dura rather than the compression on the nerve root.

In vitro studies have shown that the swelling pressure of disc tissue, when exposed to water in a confined space, may exceed several hundred millimeters of mercury (Charnley 1952, Hendry 1958). However, this pressure reflects rather an internal quality of the nucleus pulposus than the pressure that might act on the spinal nerve roots in case of disc herniation.

Magnaes found that a pressure of 30 - 170 mm Hg or more was required to move fluid from the caudal to the cranial part of the subarachnoid space during compression by spinal stenosis *in vivo* (Magnaes 1982). However, since the compressive agent was a rigid structure, (*ie.*, bone), these pressure recordings might have reflected the elastic properties of the nerve tissue rather than the pressure acting upon it.

Schönström and collaborators found that the critical size of the cross-sectional area of the dura sac, (*ie.*, the size where there is a increase of tissue pressure if constricted by a hose clamp *in vitro*), was 65-75 mm^2 in the lumbar spine (Schönström *et al* 1984). When the hose clamp was further tightened, there was an increase of the cerebrospinal fluid to about 100 mm Hg. The pressure, however, declined to 0 mm Hg. When the pressure did not normalize for 10 minutes, the sustained size was registered. This size was found to be 45-55 mm^2. In another study, the mean cross-sectional area of the dural sac was measured by means of CT-scan (Schönström *et al* 1985). This area was found to be about 90 mm^2 in symptomatic spinal stenosis patients, as opposed to 180 mm^2 in healthy subjects.

Watanabe and Parke performed a post-mortem study on a patient with spinal stenosis, regarding neural and vascular pathology (Watanabe & Parke 1986). They found that, although the nerve roots were clearly flattened, there was a continuity of the arteries through the compressed segment. However, the venules showed signs of congestion and were reduced in number.

Ooi and collaborators have studied the cauda equina vasculature *in vivo* in man using myeloscopy (Ooi *et al* 1980, Mita *et al* 1989). They observed that there is venular congestion in patients with spinal stenosis.

In conclusion, the pressure levels present in clinical cases of nerve root compression are not known. There is, however, evidence that the resting pressure in spinal stenosis is sufficient to induce venular, but not arteriolar congestion.

AIMS OF THE INVESTIGATION

In the present investigation, a model for experimental, graded compression of the nerve roots of the pig cauda equina is presented (I). The model permits various analyses of changes in physiologic parameters of the nerve roots during or after experimental compression. The aims of the investigation were to study the effects of compression on;

- the blood flow in the intrinsic vessels of the nerve roots (II).
- the transport of nutrients to the nerve roots (III).
- microvascular permeability in the nerve roots (IV).
- impulse propagation of the nerve roots (V).

In addition, Papers III-V also included analyses of differences in effects between a rapid onset rate (0.05-0.1 seconds) and a slow onset rate (the pressure was gradually increased during 20 seconds) of compression.

MATERIAL AND METHODS

ANIMALS AND ANAESTHESIA

The present investigation comprised 151 pigs (Swedish landbreed/ Swedish Yorkshire). The bodyweight of the pigs used for the compression studies, papers II-V, ranged from 25 kg to 60 kg, and the age from 2 months to 6 months. In Paper I, bigger animals were also included for comparative reasons. These animals weighed up to 150 kg and were up to 18 months old.

Anaesthesia was induced by an intramuscular injection of 15-20 mg/kg bodyweight of Ketalar® (ketamine 50 mg/ml, Parke-Davis, Morris Plains, New Jersey). After 10 minutes, the pigs received an intravenous injection of 3-5 mg/kg bodyweight of Hypnodil® (methomidate chloride 50 mg/ml, AB Leo, Helsingborg, Sweden). In papers I, III and V, they also received 0.05-0.1 mg/kg bodyweight of intravenous Stresnil® (azaperon 2 mg/ml, Janssen Pharmaceutica, Beerse, Belgium). The pigs were then tracheotomized, intubated and ventilated on respirator with room air. Through the same incision, *v jugularis externa*, and in Paper II *a carotis communis*, were catheterized.

In papers I, III and V, the anaesthesia was maintained by additional injections of 2-3 mg/kg bodyweight of Hypnodil® and 0.05-0.1 mg/kg bodyweight of Stresnil® each 20 - 30 minutes. In papers II and IV, the anaesthesia was maintained only by additional injections of 2-3 mg/kg bodyweight of Hypnodil®. To induce muscular relaxation, repeated intravenous injections of 2-3 mg/kg bodyweight of Celocurin® (suxamethonium chloride 50 mg/ml, ACO Läkemedel AB, Solna, Sweden) were administered in papers II, III and IV.

After each experiment, the pigs were killed with an intravenously administered overdose of potassium chloride.

SURGICAL EXPOSURE OF THE CAUDA EQUINA

The pigs were placed prone on an operating table with the hind part of the pig slightly elevated to reduce surgical bleeding. A 10-15 cm long midline incision was made over the sacrum and coccyx. The spinal muscles covering the laminae from the 5th sacral to the 3rd coccygeal vertebrae were removed. In addition, the two dorsal sacrocaudal muscles, which run lateral to the spine, were excised to facilitate the experimental procedures. Laminectomies of the 1st and 2nd coccygeal vertebrae were performed using a rongeur. The exposure also included removal of facet-joints and pedicles. Unlike the human spine, the epidural membrane (Dommisse 1975, Hasue *et al* 1983) is well developed in the pig, and it encloses the cauda equina and epidural fat as a continuous sac. To expose the cauda equina, the posterior parts of this membranous sac were excised and the epidural fat was carefully removed. The neural and vascular anatomy of the porcine cauda equina at this level were analysed in Paper I, and will therefore be presented under "Results and comments", (pages 32-36).

COMPRESSION MODEL

The nerve roots were compressed towards the ventral aspect of the spinal canal by an inflatable plastic balloon (diameter 10 mm), (Figure 8). The shape of the the spinal canal, including the intervertebral disc, is relatively flat at this level, which thus provides a suitable surface for the nerve root compression.

The balloons were made by welding thin and pliable polyethylene sheets into cylinders. One end of these cylinders was sealed with a silk ligature and the other was connected to a polyethylene tube (diameter 1 mm). The balloons were positioned between the nerve roots and a transparent plexiglass plate which was held by two L-shaped pins, (Figure 8). The pins were driven so far into the vertebral bone that the ballon should

still be relatively flat after inflation. This procedure was important for achieving an adequate pressure transmission from the balloon to the nerve roots. The balloons were inflated by a compressed-air system (Stille-Werner, Stockholm, Sweden), which automatically compensates for any leakage of air, thereby maintaining the pressure at a constant level troughout the experiments. When the balloons were inflated they compressed the nerve roots towards the underlying discs and vertebral bodies. The compressed-air system could be set at any pressure level in the range of 0-600 mm Hg. During compression, the cauda equina could be observed through the plexiglass plate. It was thus possible to obtain a visual confirmation that the entire cauda equina was compressed by the balloon.

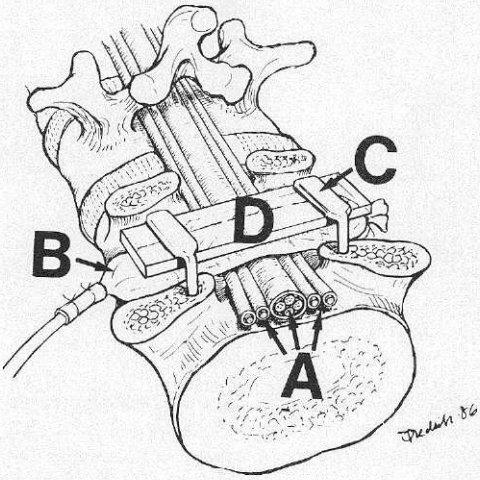

Figure 8: *Schematic drawing of experimental model. The cauda equina (A) is compressed by an inflatable balloon (B) that is fixed to the spine by two L-shaped pins (C) and a plexiglass plate (D). (Reproduced with permission from Spine, Olmarker et al 1989, Paper IV).*

The compressed-air system was fed by air (Papers I-IV) or nitrogen (Paper V). To ensure that the balloons were not compressing parts of bone instead of the nerve roots in the spinal canal, great care was taken in the preparation of the compression site to remove any parts of the pedicles in contact with the balloon.

ACCURACY OF PRESSURE TRANSMISSION

The accuracy of pressure transmission from the balloon to the nerve roots was analysed in Paper I, and will therefore be presented under "Results and comments", (page 32).

RATE OF ONSET OF THE COMPRESSION

In papers III, IV and V, the effects on the cauda equina of compression at two different rates of compression onset were investigated. The balloon was inflated either by starting the compression by flipping the switch with a preset pressure level in the compressed-air system, or by slowly increasing the pressure in the balloon to the desired level during approximately 20 seconds. The first mode of compression onset resulted in a rapid inflation of the balloon, and thus rapid compression of the cauda equina. To determine the rate of this rapid onset of compression, the following experiment was performed.

The uninflated and flattened balloon was held between a tracing pen of a Grass 7B Polygraph recorder (Grass Instrument Co., Quincy, Mass.) and a piece of wood, (Figure 9). When the balloon was inflated, it thus affected the tracing pen. The movement of the pen was registered on the recording paper, which was running with a known speed. The time from the start of inflation to the point of complete inflation could thus be measured directly on the paper, (Figure 9). After 0.05 seconds, there was an inflation to approximately 90% of the intended value. Complete inflation, (*ie.*, 100% of the intended value), was obtained after approximately 0.1 seconds. The onset time for the rapid onset rate was therefore determined to 0.05 - 0.1 seconds. This onset rate was found to be constant in the range of 10 - 200 mm Hg.

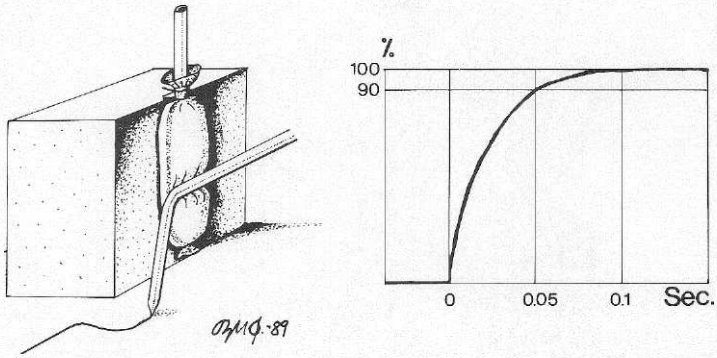

Figure 9: (Left) *Drawing of experimental set-up for measuring the rate of rapid onset of compression employed in the present investigation.* (Right) *The graph on the registration paper shows that 0.05 seconds after initiating the inflation of the balloon, the balloon had been inflated to approximately 90 % of the finial value. Full inflation was not achieved until 0.1 seconds after start of inflation.*

EXPERIMENTAL PROCEDURES AND ANALYSES

I Compression model, including neural and vascular anatomy of the porcine cauda equina.

Series I - Accuracy of pressure transmission from the balloon to the cauda equina. To evaluate the accuracy of pressure transmission from the balloon to the cauda equina, the following experiment was performed. One pig, killed for other purposes, was used. The spinal canal was opened and the compression model was set up. However, the cauda equina was exchanged with a rabbit abdominal vein with approximately the same diameter as the removed cauda equina. The vein was connected to a compressed-fluid system with an attached manometer, (Figure 10). The manometer of this compressed-fluid system was calibrated against the manometer of the compressed-air system which was used to inflate the balloon. The pressure level of the compressed-fluid system was slowly increased, with a known pressure in the balloon. When the first signs of leakage of saline through the vein in the compression zone was observed, the pressure level of the compressed-fluid system was noted. The difference between this pressure and the pressure in the balloon could thus be calculated (Rydevik *et al* 1981). In this way, balloon pressure levels in the range of 0-200 mm Hg were tested systematically, twice at each pressure level.

Series II - Gross anatomy of the porcine cauda equina. A total of 5 pigs, (25-40 kg n=2, 60-80 kg n=2, 100-150 kg n=1), were used. The spinal canal was opened from the 1st sacral to the 4th coccygeal vertebrae. The dural sac was opened and the content of the

spinal canal was examined with respect to gross anatomy of the cauda equina, both macroscopically and with the use of an operating microscope. Observations were also performed, when possible, on the pigs of series III, IV and V.

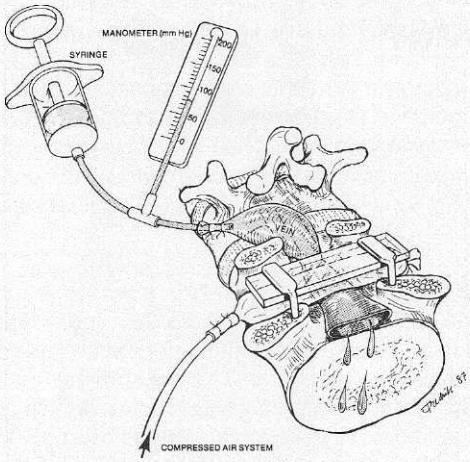

Figure 10: *Experimental set-up for testing the accuracy of pressure transmission from the balloon to the nerve roots. For further details, see text. (Reproduced with permission from Spine, Olmarker et al 1989, Paper IV).*

Series III - Extension of the subarachnoid space of the porcine cauda equina. Five pigs, (25-40 kg n=2, 60-80 kg n=2, 100-150 kg n=1), were used. The spinal canal was opened from the 6th lumbar to the 4th coccygeal vertebrae. Through a small incision in the dura, a polyethylene catheter was placed into the subarachnoid space with the tip at the level of the 1st sacral vertebrae. The catheter was secured with a ligature around the entire dural sac, including catheter, just caudal to the incision. A volume of 3-5 ml of India Ink (Pelikan, Hannover, FRG) was injected into the subarachnoid space. This procedure enabled macroscopic studies of the extension of the subarachnoid space out into the root sleeves.

Series IV - Microscopic anatomy of the porcine cauda equina. Five pigs, (25-40 kg n=2, 60-80 kg n=2, 100-150 kg n=1), were used. The spinal canal was opened from the 1st sacral to the 4th coccygeal vertebrae. The dural sac was opened, and specimens of nerve tissue at various levels were obtained and fixed by immersion in a mixture of 4% paraformaldehyde and 5% glutaraldehyde (Karnovsky 1965). The specimens were rinsed in 0.15 M Na-cacodylate buffer (pH 7.15), post-fixed for 2 hours in 1% osmium tetroxide, dehydrated in a series of ethanols and propylene oxide, and embedded in Epon 812 (Polaron, Stockholm, Sweden). Sections 1 µm thick were prepared and stained with methylene blue and Azur II (Richardsson *et al* 1960).

Series V - Vascular anatomy of the porcine cauda equina. Five pigs, (25-40 kg n=2, 60-80 kg n=2, 100-150 n=1), were used. The pigs received a single intravenous injection of 400-600 IE/kg bodyweight of Heparin®, (heparin 5.000 IE/ml, KabiVitrum, Stockholm, Sweden).

The abdomen was incised and the aorta clamped just caudal to the diaphragm. An aortic perfusion cannula (Argyle, St Louis, USA), was placed in the aorta through a small incision at the level of *aa. renales*. The cannula was secured by ligating the aorta caudal to the incision. Three to five liters of saline at 37°C were infused at a rate of 1 to

2 liters/minute using a heart-lung machine (Gambro, Dreissen, Netherlands). Intermittent injections of 0.5-1 ml of Xylocain® (lidocain 50 mg/ml, Astra, Södertälje, Sweden) were administered via the infusion catheter to induce vasodilatation. *V cava inferior* was cut in the lower part of the abdomen to drain the infused volumes (Lundskog *et al* 1968). Immediately after the saline infusion, 2-3 liters of a filtered India ink solution (50% India ink in saline, Pelikan, Hannover, FRG) at 37°C, was infused at a rate of 1-2 liters/minute.

The sacrum and upper four coccygeal vertebrae were removed en-bloc. The spinal canal was opened and the preparation was fixed by immersion in 2.5% glutaraldehyde for 7 days. The cauda equina was then removed and clarified with methyl salicylate and benzyl benzoate with a modified Spalteholz technique. For comparative reasons, a part of the sciatic nerve at the level of the hip joint was collected from all animals and processed in a similar manner.

II Effects of compression on blood flow in the porcine cauda equina.

In this paper, the compression balloon was placed under the cauda equina. The cauda equina was thus compressed dorsally, between the plexiglass plate and the balloon, instead of ventrally, between the disc and the balloon. This experimental set-up was found to be necessary for optimising the microscopic observations, which were obtained through the plexiglass plate from above. A Leitz large vital microscope (Leitz, Wetzlar, FRG) and incident light illumination were used for the observations. The experiments were recorded on video tape to allow subsequent detailed analyses later.

The mean arterial pressure was continuously registered by a catheter in the thoracic aorta connected to Gould-Statham P23 pressure transducer (Gould-Statham Instruments Co., Hato Rey, Puerto Rico) and A Grass 7B polygraph recorder (Grass Instrument Co., Quincy, MA, USA).

Series I - Occlusion pressures for the various components of the cauda equina vasculature. In twelve pigs, bodyweight 25-40 kg, the pressure in the balloon was increased stepwise, 5 mm Hg every 20 seconds up to 50 mm Hg and then 10 mm Hg every 20 seconds until there was no blood flow observed in the compressed segment of the cauda equina. By observing the cauda equina through the microscope, the pressure required to stop the blood flow for each specific vessel could thus determined. This procedure was performed twice in each animal.

Series II - Recirculation of the cauda equina vasculature following compression for various times and at various levels. After series I was completed, the nerve roots were exposed to compression at 50 mm Hg for 10 minutes or 2 hours, or at 200 mm Hg for 10 minutes or 2 hours. The recirculation of the cauda equina was analysed regarding: initial flow (*ie.*, immediate versus delayed recirculation), hyperemia (*ie.*, normal versus increased blood flow) and intraneural edema formation (*ie.*, normal versus increasing opacity of nerve root tissue with increasing difficulties to focus on vessels).

III Effects of compression on the nutritional supply to the porcine cauda equina.

The effects of surgical exposure (control), sham-compression and compression at three different pressure levels were studied in 48 pigs, bodyweight 25-40 kg.

Control, (n=6). The spinal canal was opened but the compression device was not applied, (*ie.*, no nerve compression).

Sham-compression, (n=6). The compression device was applied but with no inflation of the balloon.

Compression, (n=36). The nerve roots were exposed to either rapid or slow onset of compression at 10 mm Hg, 50 mm Hg, or 200 mm Hg, (n=6 for each of the six subseries).

The spinal nerve roots were exposed to control conditions, sham-compression, or compression for a total of 30 minutes. After 25 of these 30 minutes, 0.5 mCi/kg bodyweight of 3-0-methyl-D-glucose-1-^{3}H (Radiochemical Centre, Amersham, England) was injected into a central vein *(v cava superior).* The methyl glucose was thus allowed to circulate for the last 5 minutes of the compression period. After the 30 minutes of compression, the entire preparation was frozen with liquid nitrogen, without releasing the compression.

The nerve roots of the cauda equina were cleaned of epidural fat and blood vessels. The cauda equina was then cut transversely into approximately 1 mm sections, from 7 mm cranial to 7 mm caudal to the compression zone. Each specimen was weighed and digested by Soluene (Packard Instruments, Stockholm, Sweden) in a test tube. The digest, and samples of blood obtained from each animal, were analysed in a ß-scintillation counter (Packard Instruments, Stockholm, Sweden). This procedure allowed calculation of the ratio (R/Rco) between nerve concentration (R) of methyl glucose and blood concentration (Rco) of methyl glusoce in each specimen.

IV Intraneural edema formation following compression of the porcine cauda equina.

The effects of sham-compression (n=3) and compression at two different pressure levels and at two different onset rates were studied in 39 pigs, boyweight 25-60 kg.

Series I - Rapid onset of compression. The effects of compression at 50 mm Hg for 2 minutes, 10 minutes and 2 hours, and at 200 mm Hg for 2 minutes, 10 minutes and 2 hours, using the rapid onset rate, were analysed, (n=18, n=3 for each subseries).

Series II - Slow onset of compression. The effects of compression at the same time/pressure relations as for series I were analysed. However, in this series, the slow compression onset rate was employed, (n=18, n=3 for each subseries).

After the compression was released, the pigs received an intravenous injection of 5 ml/kg bodyweight of a filtered preparation of Evans Blue labelled albumin (EBA). The EBA was prepared by mixing 5% bovine albumin (fraction V) with Evans Blue. When the EBA complex had been circulating for 30 minutes, the nerve roots were ligated to a wooden stick at *in vivo* length and frozen with liquid nitrogen. The location of the compression zone was marked on the stick.

Frozen longitudinal sections of the nerve roots (10 µm thick) were mounted in 50 % aqueous glycerol. The sections were examined in a Nikon Optiphot microscope equipped with episcopic-fluorescene attachment EF-D using filter block B-2 A (Nikon, Tokyo, Japan). The distribution of the EBA complex could be determined as it emits a bright red fluorescence, which contrasts clearly to the green autofluorescence of the nerve tissue.

V Effects of compression on impulse propagation of the porcine cauda equina.

Two AO cortical screws (diameter 2.7 mm, AO, Davos, Switzerland) were fixed in the lamina of the 5th sacral vertebra, approximately 10 mm apart from each other, in 32 pigs, bodyweight 25-40 kg. When connected to a Grass SD9 stimulator (Grass Instrument Co., Quincy, Mass.), the two screws served as stimulating electrodes. The stimulus strength was always 2-3 times higher than the minimum voltage required to generate maximal amplitude of the MAP (muscle action potential), (see below), and was kept constant during the experiment. To ensure that any changes should be confined to

the compression zone, intermittent stimulations were also performed just caudal to the compression balloon by retractable electrodes, (Figure 11).

MAP's were recorded by two E2 subdermal platinum needle electrodes (Grass Instrument Co., Quincy, Mass.) that were placed into the muscles in the tail approximately 10 mm apart. This procedure is reproducible and represents a measurement of the function of the motor nerve fibers of the nerve roots. The MAP was visualized on a Tektronix 5103N Dual Beam Storage Oscilloscope (Tektronix, Guernsey Ltd, Guernsey, Channel Islands) using a Grass P18 preamplifier (Grass Instrument Co., Quincy, Mass.).

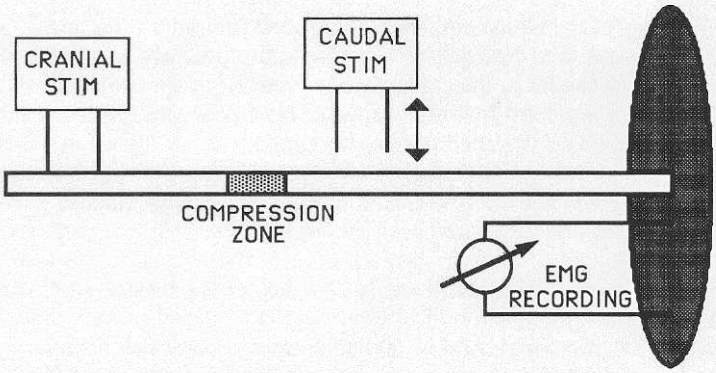

Figure 11: *Experimental set-up. The cauda equina is stimulated either via two AO cortical screws fixed in the sacral lamina (cranial stim) or intermittently via retractable electrodes (caudal stim), (see text for details). The impulse propagation of the cauda equina is registered as a MAP (EMG recording) by electrodes placed in the tail muscles. (Reproduced with permission from Spine, Olmarker et al 1990, Paper V).*

Nerve function was registered as the amplitude of the first peak of the MAP-recording, and was measured directly on the oscilloscope. This peak reflects the fastest conducting fibers, which also are the fibers with the largest diameter (Gasser & Erlanger 1929). Large diameter fibers are known to be more susceptible to compression (Gasser & Erlanger 1929) and may also be subjected to greater deformation than small diameter nerve fibers (MacGregor *et al* 1975). Therefore, analysis of the first peak of the MAP represents a sensitive method for studying changes in the motor fiber propagation in the nerve roots. It has been noted that changes in amplitude of the first peak of the MAP are seen earlier than changes in conduction velocity (Pedowitz *et al* 1988, 1989, Rydevik *et al* 1990b). The present study therefore focused only on changes in MAP-amplitude.

To ensure that only impulses from compressed nerve fibers were registered, all nerves that left the spinal canal between the stimulating electrodes and the compression balloon were cut. A confirmation of the outcome of this procedure was obtained after the experiment by studying the MAP after cutting the cauda equina at the compression site. Since there should be no remaining conducting axons, this should thus result in a flat MAP-recording.

The preparation was covered with a polyethylene sheath to maintain constant humidity and temperature. The temperature was controlled by means of a thermostat controlled heating lamp with the temperature probe close to the nerve roots and compression-balloon during the experiments. Intermittent recordings of MAP's were performed using supramaximal stimulation strength until temperature and amplitude of the MAP's had

been constant for 15 minutes. This value of the MAP-amplitude served as baseline (100%) and all recordings during the experiment were expressed in percent of this value.

The pressure levels used were; 0 mm Hg (sham, n=2), 50 mm Hg, 100 mm Hg and 200 mm Hg. Except for sham-compression, there were 5 animals with the rapid onset and 5 with the slow onset of compression for each pressure level. Unlike Papers II-IV, a compressed-nitrogen system was used to inflate the compression balloon (Stille-Werner, Stockholm, Sweden). The nerve roots were compressed for 2 hours and allowed to recover for 1.5 hours, with the compression balloon removed. MAP-recordings were performed 5, 10 and 15 minutes after compression onset, and then every 15 minutes.

STATISTICAL PROCEDURES AND ANALYSES

I Compression model, including neural and vascular anatomy of the porcine cauda equina.

No statistical methods were employed in this paper.

II Effects of compression on blood flow in the porcine cauda equina.

1) To obtain the average minimum pressure of the balloon required to stop the blood flow in the arterioles, the capillaries and the venules respectively (series I), the following calculations were made. The minimum pressure required to stop the blood flow was determined for each vessel separately as the mean between the two obtained values. The average for each type of vessel could thus be calculated for each separate pig. The average and the distribution of these obtained values were then calculated.

2) The correlation between the pressure required to stop the blood flow in different vessels and the mean arterial pressure was calculated, using linear regression analysis (series I).

3) The effects of compression on the recirculation in the nerve roots (series II) were graded on three grade scales where 0 = no changes, + = moderate changes and ++ = marked changes. No further statistical analyses were performed on these data.

III Effects of compression on the nutritional supply to the porcine cauda equina.

1) The average R/Rco-graphs (*ie.*, the ratio between the obtained radioactivity in the digested specimen (R) and the radioactivity in the normalized blood (Rco)) for each sub-series were plotted in a diagram with the length of the nerve roots on the X-axis and the R/Rco-ratio on the Y-axis, (Figure 18, page 46). These graphs were obtained by calculating the means for the six animals in each sub-series at 1 mm intervals.

2) The average R/Rco-ratio within the compression zone was obtained for each sub-series by first calculating the mean of the observations within the compression zone for each animal and then the average of these obtained mean R/Rco-ratios for the six animals in each sub-series.

3) Differences in R/Rco-ratio within the compression zone between control and sham-compression and between rapid and slow onset of compression at corresponding pressure levels were evaluated with Wilcoxon's rank sum test.

IV Intraneural edema formation following compression of the porcine cauda equina.

Microvascular permeability, (*ie.*, the distribution of EBA-complex within the endoneurial space), was studied at 5 different locations of the cauda equina, regarding i) degree of edema and ii) fraction of nerve roots involved (Figure 12). The degree of edema was determined according to a three grade scale, (Figure 12). If there were different degrees of edema present in the nerve roots at the same location, only the most pronoun-

ced reaction was registered. The gradings for the fraction of nerve roots involved were; - = no nerve roots involved, + = less than 50 % of the nerve roots involved and ++ = 50 % or more of the nerve roots involved.

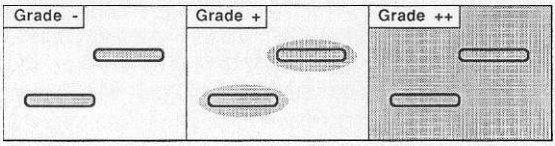

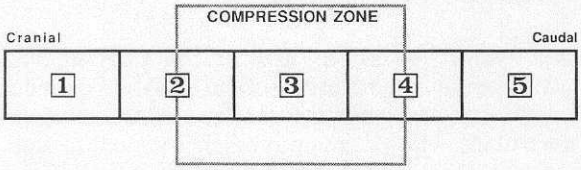

Figure 12: (Top) *Schematic drawing of longitudinal sections of three nerve root segments with different degrees of intraneural edema. Each nerve root contains two intraneural capillaries. The distribution of Evans Blue labelled albumin (EBA), within the nerve root in the microscopic sections was graded on a three grade scale; - = EBA only within the vessel lumen (no edema), + = EBA also between the axons in the endoneurial space but only adjacent to the vessels (slight edema), and ++ = EBA between the axons and reaching from one lateral border of the nerve root to the other (pronounced edema).* (Bottom) *The formation of intraneural edema was studied at 5 different locations of the cauda equina; 1) cranial to the cranial edge zone, 2) at the cranial edge zone, 3) at the center of compression zone, 4) at the caudal edge zone and 5) caudal to the caudal edge zone. (Reproduced with permission from Spine, Olmarker et al 1989, Paper IV).*

V Effects of compression on impulse propagation of the porcine cauda equina.

The mean percentage reduction of the MAP-amplitude during the 2 hours of compression, (*ie.*, at all MAP-recordings during the compression period), was calculated for each pig separately. Using these values the average percentage reduction could be calculated for each series. Wilcoxon's rank sum test was used to analyse the differences between the rapid and slow onset series at corresponding pressure levels.

RESULTS AND COMMENTS

I Compression model, including neural and vascular anatomy of the porcine cauda equina.

Series I Accuracy of pressure transmission from the balloon to the cauda equina. The difference between the pressure in the compressed-fluid system and the pressure in the balloon was found to be less than 5 mm Hg in the range of 0-200 mm Hg.

Series II Gross anatomy of the porcine cauda equina. Generally, there were no apparent differences in the gross anatomy of the cauda equina between the pigs of the different sizes studied in the present investigation.

The spinal cord terminated approximately at the level of the 2nd sacral vertebra, (Figure 13). Since the human spinal cord ends at the level of the 1st lumbar vertebra

(Rauschning 1983), the *conus medullaris* is thus located more caudal in the pig than in the human spine. The dorsal root gangliae (DRG) of the 1st sacral nerve roots were located close to their respective intervertebral foramina. For the lower nerve roots, however, the DRG's were successively more cranial to their respective intervertebral foramina. In fact, the DRG's of most coccygeal nerve roots were located within the sacrum, (Figure 13). However, the DRG's for the most caudal nerve roots (Co_6-Co_7) were found caudal to the 2nd coccygeal vertebra (*ie.*, caudal to the compression zone).

The motor and the sensory root joined at the level of the DRG, (Figure 14). No interconnection between the two nerve trunks could be detected macroscopically below this level. By definition, the nerve tissue caudal to the DRG should therefore be called spinal nerve instead of nerve root.

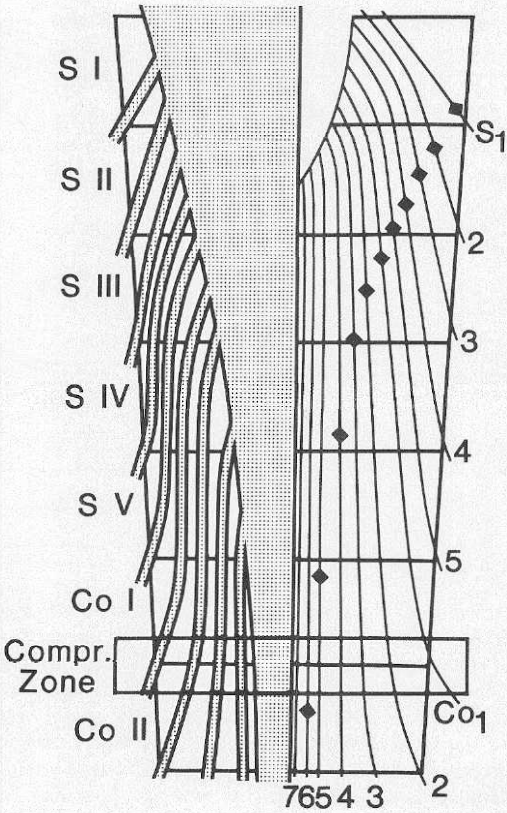

Figure 13: *Schematic presentation of the porcine cauda equina at the level of the sacrum and the two upper coccygeal vertebrae. The left half of the drawing demonstrates the spinal dura enclosing the cauda equina, both as a common central sac, and as separate extensions, called root sleeves. In the right half, the location of the dorsal root gangliae (squares), and the intraspinal course of the nerve tissue of the cauda equina are shown. The dorsal root gangliae are mainly located cranial to the compression zone. Roman numerals (left side) indicate vertebral levels, and arabic numerals (right side) indicate nerve root levels.*

At the compression site, (*ie.*, the area between the pedicles of the 1st and 2nd coccygeal vertebrae), the first coccygeal "nerve roots" (Co_1) left the spinal canal just cranial to the disc, and were therefore not compressed by the balloon in this model, (Figure 13). A common dural sac, which usually enclosed 3 pairs of "nerve roots" (Co_5-Co_7), was found in the center of the cauda equina. Lateral to the dural sac there were usually 3 pairs of "nerve roots" (Co_2-Co_4) in separate root sleeves. There are thus both "intrathecal" and "extrathecal" nerves (Wall *et al* 1990) represented at the compression site.

Occasionally, the spiral bands of Fontana (Clarke & Bearn 1972, Thomas & Olsson 1984) could be noted at the last 10-20 mm of the nerve roots before exit from the spinal canal.

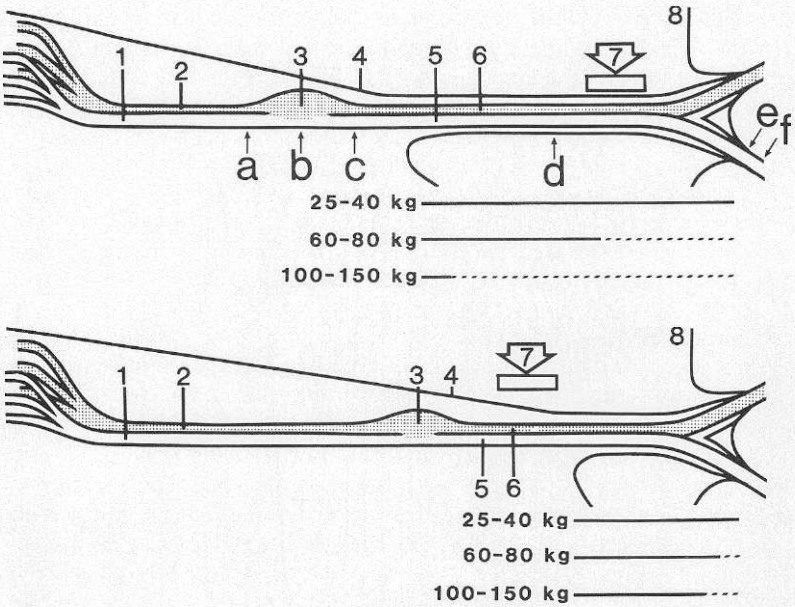

Figure 14: *Schematic drawings of the anatomy at the 2nd coccygeal (top) and at the 5th coccygeal nerve root (bottom) level. The ventral (1) and the dorsal (2) nerve roots leave the spinal cord and run in the subarachnoid space surrounded by the cerebrospinal fluid. At the level of the dorsal root ganglion (3) the fibers of the two nerve roots are mixed, and the ventral ramus (5) and dorsal ramus (6) of the spinal nerve is formed. The dura (4) encloses the nerve components until the point where they leave the spinal canal, and where also the epidural membrane (8) approaches the nerve tissue. The compression site (7) is located caudal to the dorsal root ganglion. The 2nd coccygeal nerve roots (top) are the largest nerve roots compressed at their extrathecal course, and the 5th coccygeal nerve roots (bottom) are the largest nerve roots compressed at their intrathecal course, in the presented model.*
The extension of the subarachnoid space for the three different sizes of pigs was investigated at both nerve root levels. The results are schematically shown under each drawing. The interrupted lines indicate nerve root segments where there was no intrathecally injected ink present immediately after the injection.
The letters a-f in the upper figure refer to the microscopic cross-sections presented in figure 15, pages 37-39.

Upon leaving the spinal canal, the nerves penetrated the surrounding sac, which is a continuation of the epidural membrane (Dommisse 1975, Hasue *et al* 1983), (Figure 14). Since the size of the nerve root increased caudal to this point, the epidural membrane thus seemed to incorporate with the nerves.

A number of "Hofmann" ligaments (Hofmann 1878, Spencer *et al* 1983, Rauschning 1987) were found to run mainly from the ventral aspect of the cauda equina in a caudal direction for several centimeters below, where they attached to the epidural membrane.

Series III Extension of the subarachnoid space of the porcine cauda equina. Unlike the consistent gross anatomy of the porcine cauda equina in series II, there were apparent differences in the extension of the subarachnoid space between the different sizes of animals investigated.

The cauda equina of the smallest animals (20-40 kg) had a subarachnoid space that was present in all nerves all the way down to the point of exit from the spinal canal. However, with increasing animal size, the subarachnoid space in the root sleeves of the most lateral nerves had become gradually sealed, (Figure 14). When the ink had been injected in these larger animals, there was an apparent border where the subarachnoid space ended in the root sleeve. However, already after some minutes there was ink detected macroscopically down into the "sealed" space. This "sealing off" phenomenon was not as apparent for more caudal segments of the cauda equina, (Figure 14).

It was recently observed that the nerve roots derive a major part of their nutrition as diffusion from the cerebrospinal fluid (Rydevik *et al* 1990a). To mimic the nutritional situation of human lumbosacral nerve roots as close as possible, it would therefore be advisable only to use pigs up to 40 kg bodyweight, particularly when using pigs of the same breed as in the present study.

Series IV Microscopic anatomy of the porcine cauda equina. There were no apparent differences observed in the microscopic anatomy between the different sizes of pigs examined.

The microscopic anatomy of the pig *cauda equina* was found to be similar to the human cauda equina (Gamble & Eames 1966, Cohen *et al* 1990). The endoneurial space was comprised of a mixture of myelinated and unmyelinated axons, and was separated from the cerebrospinal fluid only by the thin root sheath, (Figures 15 a-d). However, unlike the human lumbo-sacral dorsal root gangliae, the dorsal root gangliae of the compressed nerves were floating freely in the cerebrospinal fluid, (Figure 14 & 15 b). At the extrathecal parts of the cauda equina, the root sleeves gradually approached the nerve components, (Figure 15 d). This also resulted in a subsequent reduction of the subarachnoid space. At the last 5-10 mm cranial to the point of exit from the spinal canal, there was a gradual formation of fascicles within the endoneurial space, (Figure 15 e). Outside the spinal canal, the microscopic anatomy of the nerve tissue changed to that of a peripheral nerve, with an epineurium and a perineurium instead of a root sleeve, and with separate fascicles, (Figure 15 f).

The light microscopic examination also revealed that the major vessels of the intrinsic system of the cauda equina, (*ie.*, arterioles and venules), were found outside the endoneurial space, and were enclosed by the root sheath, (Figures 15 a). Within the endoneurial space, there were only capillaries present.

Series V Vascular anatomy of the porcine cauda equina. There were no observed differences in the vascular anatomy between the different sizes of pigs examined.

The main arteries of the spinal cord were supplied by vessels that were accompanying the nerve roots from the intervertebral foramina, (Figure 16 a). However, these vessels did not supply any branches to the nerve roots along the course in the spinal canal. Extrathecally, these vessels were located outside the root sleeve, (Figure 16 b). Upon entering the central dural sac, at a level below the entrance of the corresponding nerve

root pair, they supplied the meninges with small branches, (Figure 16 b & e). It was thus apparent that there were two different vascular systems of the cauda equina. There was one "extrinsic system", with vessels running between the segmental arteries outside the spinal canal and the *vasa corona* of the spinal cord, which did not directly participate in the nutrition of the nerve tissue. There was also one "intrinsic system" of vessels which were running within the root sheath, and which were supplying the capillary networks of the nerve tissue.

The intrinsic system of the cranial parts of the nerve roots was derived from the *vasa corona* of the spinal cord, (Figure 16 a).The vessels of the intrinsic system were found to run parallel to the nerve fibers in a straight course within the nerve roots. There were frequent vascular loops and also a "coiling" or "tortuous" course of these vessels, (Figure 16 c & d). From the venules and arterioles, the branches left at almost right angles. These branches either supplied superficially located and longitudinally running vessels of lesser caliber, or penetrated between the axons to supply the endoneurial capillary networks, (Figure 16 d).

It was not evident if the intrinsic vessels from the cranial part of the nerve roots also supplied the most caudal parts, or if there was a separate caudal intrinsic system of vessels. Indeed, there were connections between extraspinal vessels and the most caudal intrinsic vessels detected at the intervertebral foramen. However, a region of "relative hypovascularity" in an anastomosing region between the two vascular systems, similar to that described by Parke and collaborators, could not be deteced (Parke *et al* 1981). Generally, the arteriolar and venular vasculature of the cauda equina was less developed than that of the peripheral nerves, (Figure 16 f).

Although there was no regional supply of arteriolar blood to the intrinsic vascular system of the nerve roots, there were regional connections between the venules of the intrinsic system and venules in the surrounding epidural fat, (Figure 16 c). Within the central dural sac there were also interradicular vessels that connected the vascular networks of different nerve roots.

The vascular anatomy of the porcine cauda equina was thus found to have a close resemblance to the human cauda equina. There was an intrinsic system of vessels that was located within the root sheath and comprised arterioles and venules that supplied the endoneurial capillary networks. There was also an extrinsic vascular system. Unlike the intrinsic system these vessels did not directly participate in the nerve root nutrition by any vascular branches to the intrinsic arterioles along the course of the nerve roots. This observation was in agreement with previous studies on the vascularisation of the human cauda equina (Parke *et al* 1981, Parke & Watanabe 1985). However, unlike the findings of Parke and collaborators on the human cauda equina, Petterson and Olsson (1989) recently observed occasional direct branches between the extrinsic and the intrinsic systems in cervical spinal nerve roots of rats.

II Effects of compression on blood flow in the porcine cauda equina.

In some of the preparations there was a slight reduction of the blood flow when the observations were started. This seemed to be due to ridges in the uninflated balloon and could always be corrected before starting the experiment.

Series I Occlusion pressures for the various components of the cauda equina vasculature. The average minimum balloon pressures required to stop the blood flow in the arterioles, capillaries and venules are presented in table 1. When the pressure in the balloon was increased, a gradually diminishing diameter of the vessels could be observed through the microscope. This effect was first seen 10-50 mm Hg below the pressure level required to stop the blood flow in that specific vessel. As a further sign of an impaired flow, the arterioles started to pulsate at a pressure level ≈ 30 - 40 mm Hg below the

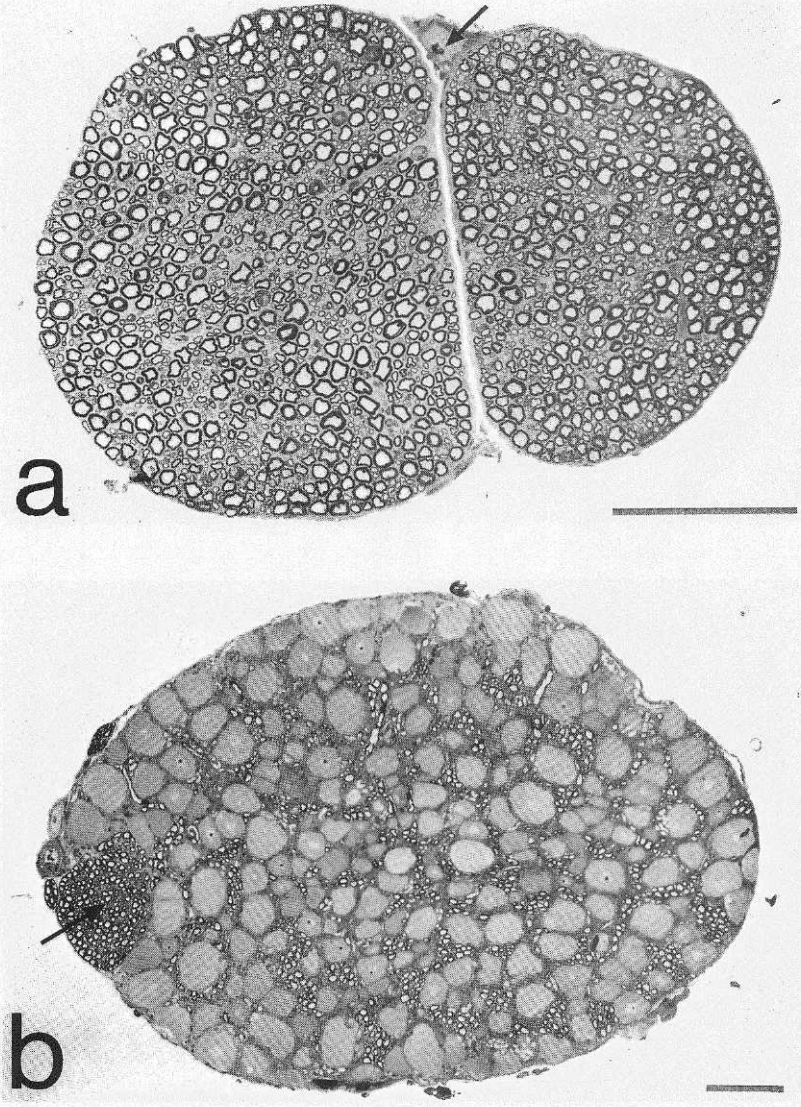

Figure 15: *Photographs of microscopic cross-sections from a 2nd coccygeal nerve root pair, (see figure 14 for orientation).*
a) *The ventral (right) and the dorsal nerve root just cranial to the dorsal root ganglion. An intrinsic vessel is seen within the root sheath, (arrow).*
b) *The nerve roots at the level of the dorsal root ganglion. A large number of ganglion cells may be seen in the picture. At this level, the axons of the roots are mixed and form the ventral and the dorsal ramus of the spinal nerve. There is only a minor part of the former ventral root that can be identified, (arrow).*
(Bar = 100 µm in both pictures).

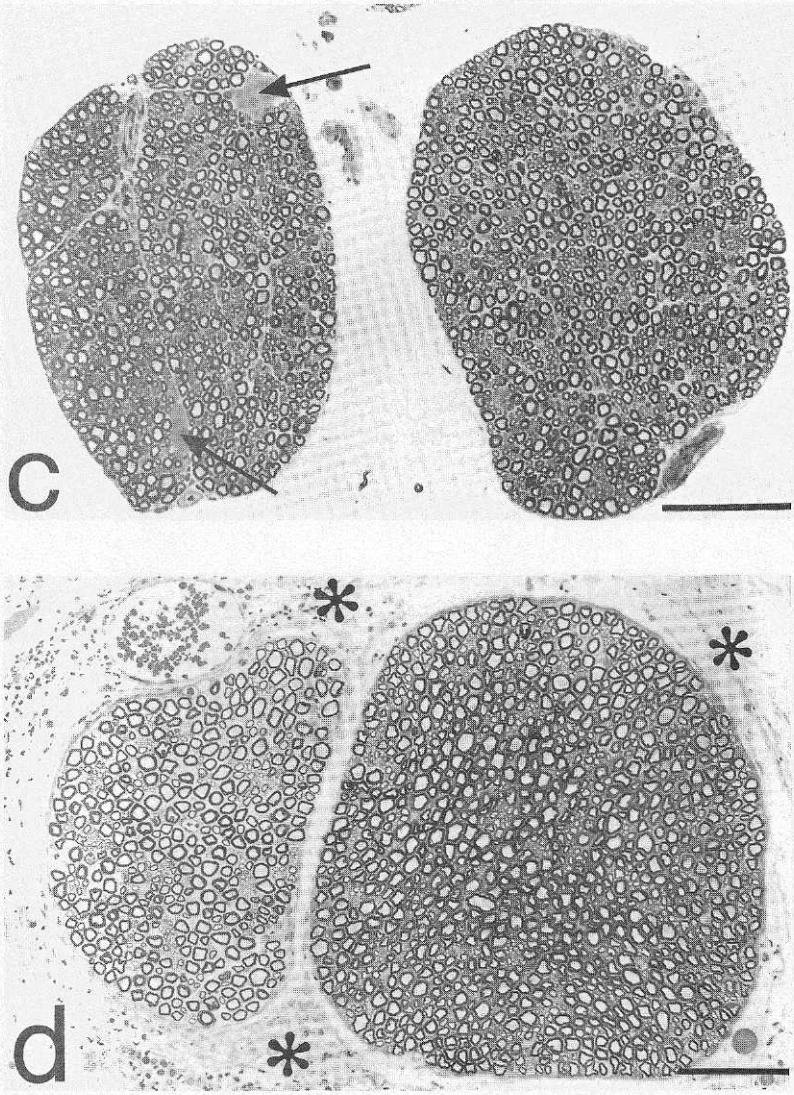

Figure 15 (cont.):
c) *The ventral (right) and dorsal ramus of the spinal nerve just caudal to the dorsal root ganglion. Some of the most caudal ganglion cells may be seen in the dorsal ramus, (arrows).*
d) *At the extrathecal course of the ventral ramus (left) and dorsal ramus of the spinal nerve, they are enclosed by an extension of the spinal dura called the root sleeve, (asterisks).*
(Bar = 100 µm in both pictures).

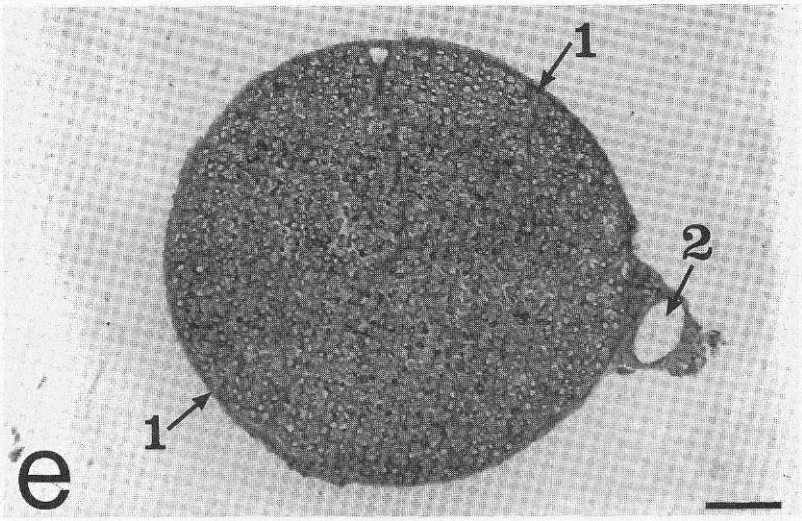

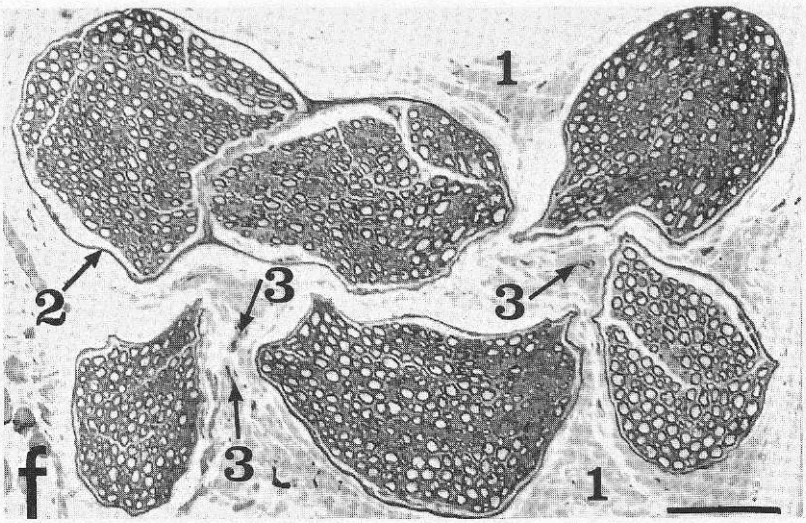

Figure 15 (cont.):
e) *The ventral ramus of the spinal nerve just prior to leaving the spinal canal. The root sleeve (1) has now approached the nerve tissue. There is no longer a subarachnoid space present between the nerve tissue and the root sleeve. Also note the formation of a fascicular pattern within the nerve tissue. Outside the root sleeve is a cross-cut extrinsic arteriole (2).*
f) *The ventral ramus of the spinal nerve just outside the spinal canal. The different fascicles have separated, and are enclosed by epineurial tissue (1), and by a perineurium (2). Extra-fascicular vessels (3) may be found between the fascicles in the epineurium.*
(Bar = 100 µm in both pictures).

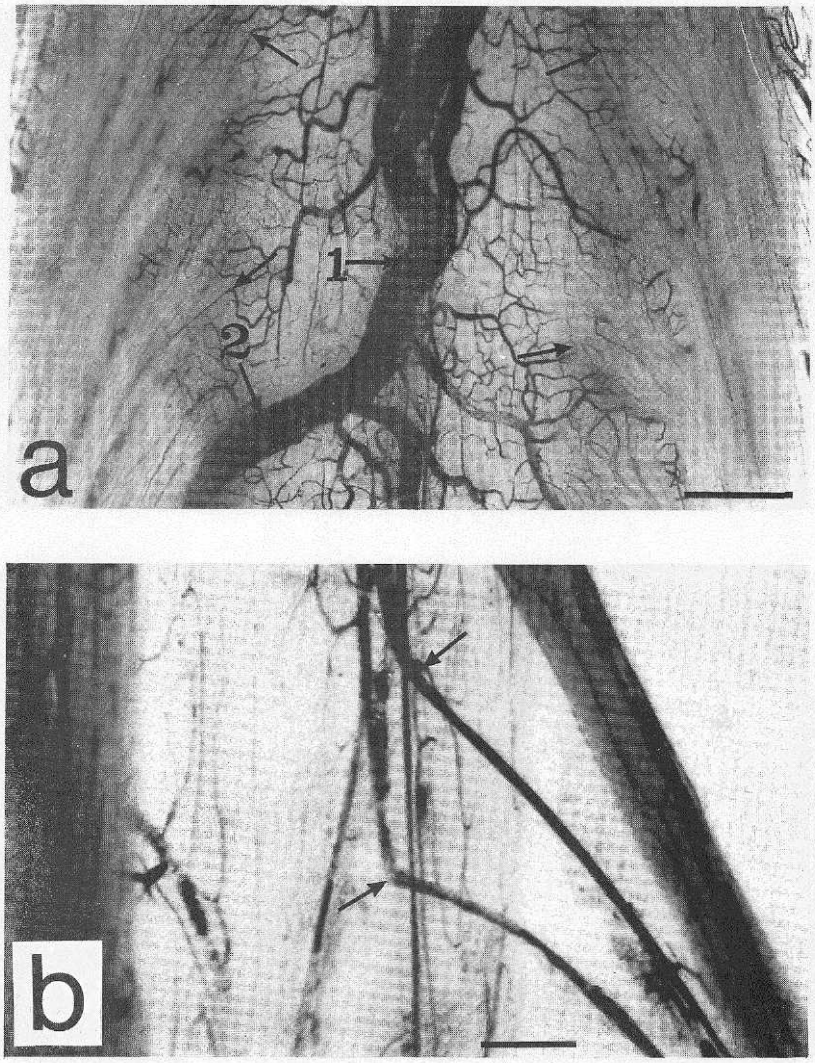

Figure 16: *Photographs of ink-injected and clarified specimens of the porcine cauda equina.*
a) *The dorsal aspect of the segment of the spinal cord from which the 2nd coccygeal nerve roots leave. The anterior spinal artery (1) is supplied with blood from an ascending medullary feeder artery (2). Vessels from the vasa corona of the spinal cord are joining the nerve roots when they leave the spinal cord (unnumberred arrows).*
b) *The picture shows the cauda equina in the central dural sac to the left and a nerve root pair that has passed through the dural sac and is now enclosed by its root sleeve to the right. Two extrinsic vessels that are running together with the nerve root pair are passing through the dural sac more caudal than the nerve roots (arrows). These vessels are also providing the meninges with small branches.*
(Bar = 1 mm in all pictures).

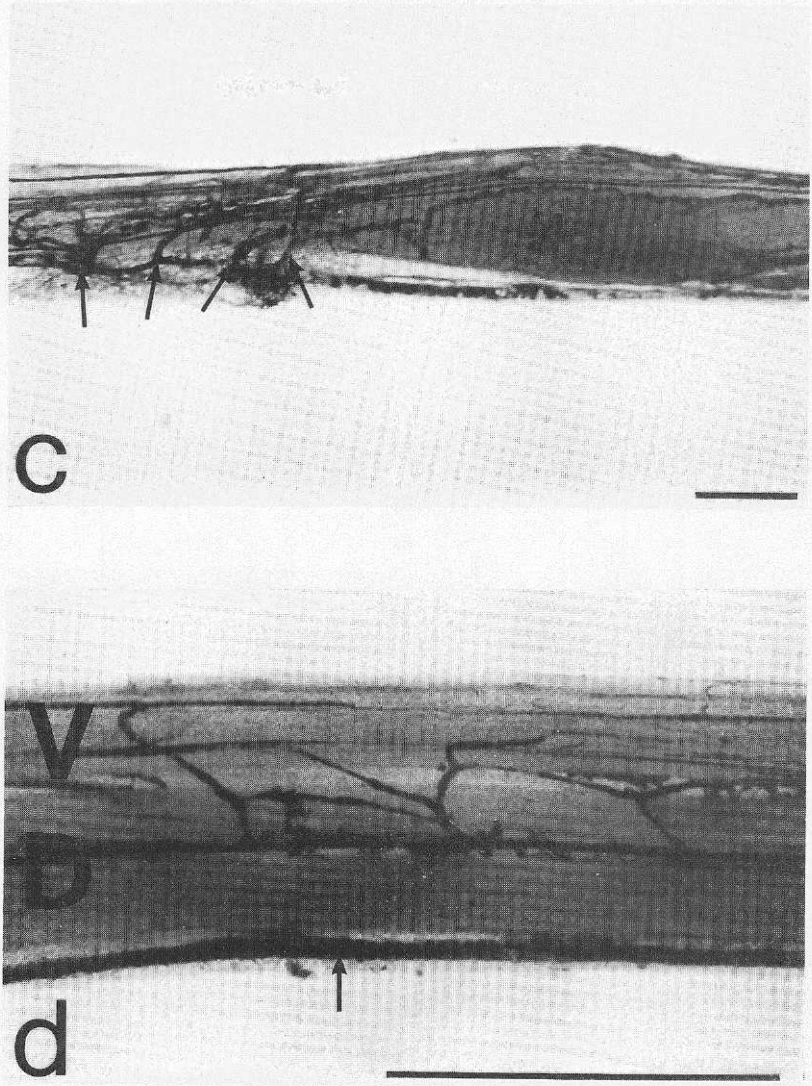

Figure 16 (cont.):
c) *The dorsal root ganglion (2nd coccygeal) demonstrates a capillary-dense area of the nerve roots, (asterisk). The intrinsic vessels demonstrate a coiling or tortuous course. There are branches from the intrinsic vessels out into the epidural fat, (arrows). (Cranial side to the right in the picture).*
d) *Vascularisation of the ventral (V) and dorsal (D) ramus of the right 2nd coccygeal spinal nerve. From a central intrinsic vessel of the dorsal ramus there are "T-like" branches that supply the ventral ramus as well. There is also an extrinsic vessel seen in the picture, with no visible branches to the intrinsic vasculature of the nerve tissue, (arrow).*
(Bar = 1 mm in both pictures).

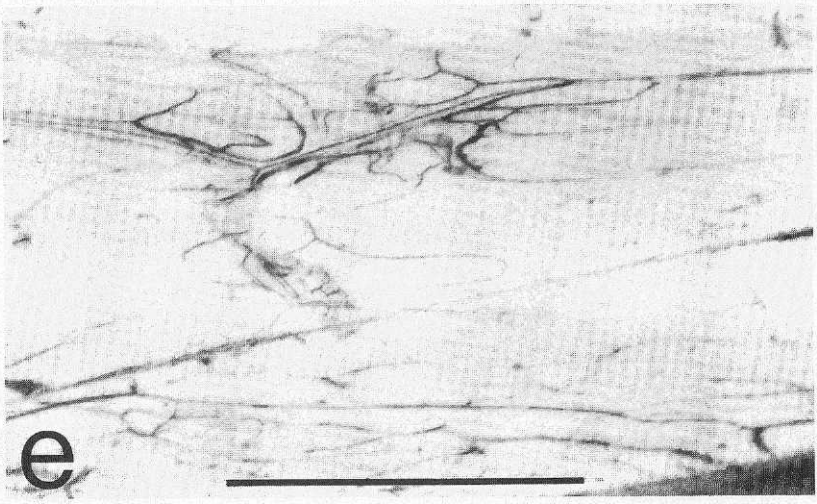



Figure 16 (cont.):
e) *Blood vessels within the spinal dura.*
f) *Vascularisation of a part of the right sciatic nerve at the level of the hip joint. Note the well developed vascular network, with numerous branches between fascicles and surrounding fat.*
(Bar = 1 mm in both pictures).
(Figures 15 & 16 reproduced with permission from Spine, Olmarker et al 1990, Paper I).

occlusion pressure. A corresponding phenomenon could not be observed for the capillaries or the venules. Generally, the capillary blood flow seemed to be dependent upon the flow in the connected venules. Thus, when the flow in an adjacent venule was impaired, there were often signs of an impaired flow in the connected capillary networks.

	x	SD	n
BPa	127	18	11
BPc	40	6	12
BPv	30	10	12

Table 1. *Average minimum balloon pressures (mm Hg) required to stop the flow in the arterioles (BPa), capillaries (BPc) and venules (BPv). The BPa is calculated from eleven pigs, as no arterioles could be identified in one of the pigs. (Reproduced with permission from J Orthop Res, Olmarker et al 1989, Paper II).*

The average mean arterial pressure, as registered by the aortic catheter, was 150 mm Hg (SD = 14, n = 12). The systolic blood pressure for pigs in the range of 1 to 400 kg may be predicted using the folowing formula (Hörnicke 1966);

Systolic blood pressure (mm Hg) = 49 + [46 x (log bodyweight in kg)]

The systolic blood pressures should therefore have been in the range of 113 mm Hg (25 kg) to 123 mm Hg (40 kg). Occasional registrations in papers III, IV and V showed that these pigs had a mean arterial pressure in the range of 100 - 120 mm Hg. The reason for the elevated mean arterial pressure in Paper II is largely unknown, but may have been based on certain pre-, and per-operative conditions.

When calculating the average minimum balloon pressures required to stop the blood flow in the arterioles, capillaries and venules it is statistically, and physiologically, less correct to look upon each vessel as a separate observation. Instead, the mean pressures for the arterioles, capillaries and venules should be calculated for each pig. The number of observations were thus equivalent to the number of pigs in the study (n=12), except for the arterioles, since no arterioles could be found in the preparation in one of the pigs (n=11).

Vital microscopy has earlier been employed to determine critical levels for compression-induced occlusion of blood vessels in tracheal mucosa (Stenqvist & Bagge 1979), and in *n tibialis* in rabbits (*ie.*, peripheral nerve), (Rydevik *et al* 1981). In both studies the pressure required to stop the arterial blood flow was close to the mean arterial blood pressure, which is in agreement with the findings in the present investigation. In the study on *n tibialis* in rabbits, however, the authors choose another form of evaluation than in Paper II of this thesis (Rydevik *et al* 1981). Instead of calculating occlusion pressures, they described the microcirculatory events at each pressure level examined. This showed that the blood flow was stopped at 60 - 80 mm Hg in the arterioles, at 50 - 80 mm Hg in the capillaries, and at 40 - 60 mm Hg in the venules. The mean arterial blood pressure in this study was 78 mm Hg. There was thus an apparent difference in the distribution of occlusion pressures on the venular side between the results on peripheral nerves and the results in Paper II. According to figure 17, the nerve root venules were occluded by pressures in the range of 5-60 mm Hg. There is thus a population of venules that was occluded at pressures much lower than were seen i peripheral nerves.

The correlation between the pressure required to stop the blood flow in the different vessels and the mean arterial pressure was statistically significant ($p<0.001$) for the arterioles ($r = 0.83$), but not for the capillaries ($r = 0.09$) or the venules ($r = -0.28$), (Figure 17). Unlike the calculation of the mean closing pressures, (Table 1), it was statistically more correct to regard results from each vessel as a separate observation in this series, since each pressure was linked to a value of the mean arterial blood pressure. Since the mean arterial pressures among normal healthy pigs were suspected to have a Gaussian distribution, it was statistically advisable to use linear regression instead of a non-parametric analysis, although a rather low number of observations were analysed (arterioles, n=14, capillaries, n=20, venules, n=34).

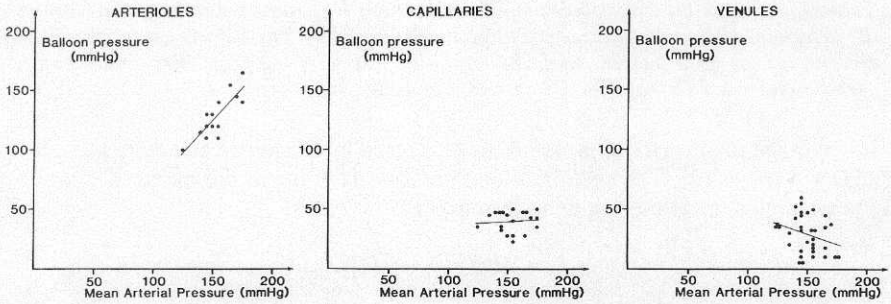

Figure 17. *Diagrams showing correlation between mean arterial pressure and the pressure required to stop blood flow in arterioles, capillaries, and venules. (Reproduced with permission from J Orthop Res, Olmarker et al 1989, Paper II).*

Series II Recirculation of the cauda equina vasculature following compression for various times and at various levels. There were no apparent changes in the blood flow in the nerve roots in any of the animals following 20 minutes of recovery from the manipulations of the first part of the experiment (series I). When the compression in series II was ended, initial flow, hyperemia and edema formation were estimated according to a three grade scale, (Table 2).

	50 mm Hg 10 min	50 mm Hg 2 h	200 mm Hg 10 min	200 mm Hg 2 hrs
Initial flow	0	(+)	0	0
	0	0	0	(+)
	0	0	0	0
Hyperemia	+	+	+	+
	+	+	+	+
	+	+	+	+
Edema	0	+	0	+
	0	+	0	+
	0	+	0	+

Table 2. *Effects of compression on recirculation. The results are graded on a three grade scale where 0 = no changes, (+) = moderate changes, and + = marked changes. Results are presented from twelve animals (n = 3 for each subseries). (Reproduced with permission from J Orthop Res, Olmarker et al 1989, Paper II).*

Recirculation was observed immediately except in two animals where there was initially a reduced flow in some of the venules. However, in these animals the flow was completely restored within 1 minute. In all animals there was evidence of a hyperemia, as compared to before beginning the compression in series II. The hyperemia was seen as a dilatation of the vessels, with an increase of the vessel diameter, that was most pronounced for the venules. Blood flow was also present in vessels that had not been previously seen in the preparation. The hyperemia developed within the first minute of circulation and gradually decreased after 5-10 minutes. Intraneural edema was seen as an increasing opacity of the nerve roots in the microscope and difficulties in getting a sharp image of the intrinsic vessels. The edema developed within the first 10 minutes of recirculation, but was only seen in nerve roots exposed to compression of either 50 or 200 mm Hg for 2 hours.

The results in series II where similar to those obtained with a vital microscopic model on *n tibialis* in rabbits (Rydevik *et al* 1981). These authors compressed the nerve at a pressure level that induced ischemia for 2 hours. Upon ending the compression the blood flow recovered within the first minute. There were also signs of intraneural edema formation.

III Effects of compression on the nutritional supply to the porcine cauda equina.

Methyl glucose is an uncharged and relatively small molecule. The transport mechanisms of methyl glucose are therefore similar to those of glucose and oxygen. Unlike these two nutrients, however, methyl glucose is a non-metabolizing solute, which makes it particularly suitable for studies on transport mechanisms of small solutes (Urban *et al* 1978).

Experimental series	Average R/Rco-ratio (%) ± SD	Reduction from control (%)
Control	79±3	---
Sham	68±5	14
S-10 mm Hg	65±2	18
S-50 mm Hg	40±2	49
S-200 mm Hg	27±5	66
R-10 mm Hg	56±4	29
R-50 mm Hg	27±10	66
R-200 mm Hg	4±2	95

Table 3. *The average R/Rco-ratio within the compression zone of the different subseries are presented, as well as the reduction of these average values as compared to the control series, (S = Slow onset of compression, R = Rapid onset of compression). (Reproduced with permission from J Spin Dis, Olmarker et al, Paper III).*

The R/Rco-ratio is a measurement of the concentration of methyl glucose in the tissue of the cauda equina. Since the circulation time was fixed at five minutes, the R/Rco-ratio reflects the equilibration of the nerve root tissue to the blood concentration of methyl glucose during these five minutes. It is therefore also a measurement of the rate of transport of methyl glucose to the nerve roots. If enough time had been allowed there

would have been an almost complete equilibration of the nerve root tissue, (*ie.*, a R/Rco-ratio close to 100%), even if the transport of methyl glucose to the nerve roots had been impaired. It was therefore important to choose a circulation time that would both allow a high R/Rco-ratio in control experiments and at the same time being short enough to reveal any impairment of the transport of methyl glucose. The current experimental set-up was found to fulfil these criteria.

Control and sham-compression. Sham-compression was found to induce a statistically significant reduction of the transport of methyl glucose to the compression-zone ($p<0.01$) as compared to control, (Figure 18, Table 3).

Compression. There was a reduction of the transport of methyl glucose to the compressed part of the nerve roots that was proportional to the applied pressure level, (Figure 18 & Table 3). However, the reduction was more pronounced with rapid onset of compression than with slow onset of compression at corresponding pressure levels. These differences were found to be statistically significant ($p<0.01$) at all three pressure levels tested (*ie.*, 10, 50 & 200 mm Hg). Outside the compression-zone the average R/Rco-ratio at the slow onset of compression generally approached the control levels more rapidly than with rapid onset of compression. The R/Rco-graphs at the slow onset rate also indicated that there was a reduction of the baselines outside the compression zone that was directly proportional to the compression pressure level.

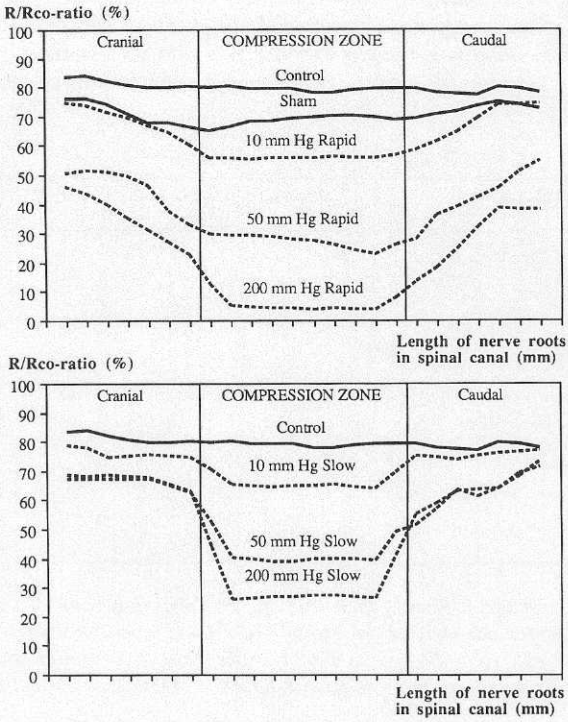

Figure 18: *Average R/Rco-ratio for control, sham-compression and compression at the rapid onset rate (top), and control and the slow onset rate (bottom). (Reproduced with permission from J Spin Dis, Olmarker et al 1990, Paper III).*

Similar to series I in Paper II, each pig was considered as one observation for the purpose of numeric evaluations. To calculate the mean R/Rco-graphs in figure 18, the average R/Rco-ratio for the six pigs in each subseries was therefore calculated for each millimeter separately. When calculating the average R/Rco-ratio within the compression zone, it was therefore also advisable to calculate the average for each pig first, and then the average for the sub-series.

The results in Paper III thus reflect the total nutritional contribution derived both from the intrinsic blood vessels and by diffusion from the cerebrospinal fluid. However, it was not possible to separate the contributions of these two nutritional pathways. Similar experiments have not been performed upon peripheral nerves, and therefore a comparison with spinal nerve roots can not be made in this regard.

IV Intraneural edema formation following compression of the porcine cauda equina.

Generally, 5-10 seconds after the EBA had been injected intravenously, this dye-complex could be seen macroscopically in the nerve root vessels in the preparation. In experiments with pronounced edema formation, one could also observe a gradually increasing blue staining of the nerve roots, particularly at the edges of the compression zone.

	Degree of intraneural edema					Fraction of nerve roots involved				
Compression	1	2	3	4	5	1	2	3	4	5
50 mm Hg - 2 min	-	+	-	++	-	-	+	-	+	-
	-	-	-	+	-	-	+	-	+	-
	-	-	-	++	-	-	-	-	++	-
50 mm Hg - 10 min	-	+	+	+	-	-	++	+	+	-
	-	++	++	+	-	-	+	+	++	-
	-	+	+	++	-	-	+	+	+	-
50 mm Hg - 2 hrs	-	++	+	++	-	-	+	+	+	-
	-	+	+	++	-	-	+	+	++	-
	-	++	+	++	-	-	+	+	++	-
200 mm Hg - 2 min	-	+	-	-	-	-	+	-	-	-
	-	++	-	+	-	-	+	-	+	-
	-	++	-	++	-	-	+	-	+	-
200 mm Hg - 10 min	-	++	++	++	-	-	++	+	+	-
	-	++	+	++	-	-	+	+	+	-
	-	+	+	+	-	-	+	+	+	-
200 mm Hg - 2 hrs	-	++	+	+	-	-	++	+	+	-
	-	+	+	++	-	-	+	+	++	-
	-	++	+	++	-	-	++	+	++	-

Table 4: *Intraneural edema formation following rapid onset of compression. The degree of edema and fraction of nerve roots involved were studied at 5 different locations of the nerve roots, and were determined according to a three grade scale, (see figure 12, page 32). There are 3 animals in each sub-series. (Reproduced with permission from Spine, Olmarker et al 1989, Paper IV).*

Sham-compression. In the sham-compression series there was no EBA detected outside the vessels in the microscopical sections.

Series I (rapid onset of compression). The edema was more pronounced following either 2 hours or 10 minutes of compression than after 2 minutes at both 50 mm Hg and 200 mm Hg compression, (Table 4). However, the magnitude and distribution of the edema at the five observation sites was similar for the two pressure levels at corresponding compression durations. The duration of compression thus seems to be more important than the pressure level for the degree of edema formation at compression up to 200 mm Hg. The edema was most pronounced at the edge-zones, but was also observed at the center of the compression zone following the two longer compression times at both compression levels.

Series II (slow onset of compression). Generally, the edema formation was not as pronounced as in series I for the corresponding compression times and pressure levels, (Table 5). There was no edema following compression at 50 mm Hg for 2 or 10 minutes. Compression at 50 mm Hg for 2 hours only induced edema at the edges of the compression zone and not at the center. Following compression at 200 mm Hg for 2 minutes there was edema only at the caudal edge of the compression zone. After 10 minutes of compression the edema was present at both edges. The results for compression at 200 mm Hg for 2 hours were, however, similar to the results for the corresponding pressure level and time for rapid onset of compression.

	Degree of intraneural edema					Fraction of nerve roots involved				
Compression	1	2	3	4	5	1	2	3	4	5
50 mm Hg - 2 min	-	-	-	-	-	-	-	-	-	-
	-	-	-	-	-	-	-	-	-	-
	-	-	-	-	-	-	-	-	-	-
50 mm Hg - 10 min	-	-	-	-	-	-	-	-	-	-
	-	-	-	-	-	-	-	-	-	-
	-	-	-	-	-	-	-	-	-	-
50 mm Hg - 2 hrs	-	+	-	+	-	-	+	-	+	-
	-	+	-	+	-	-	+	-	+	-
	-	+	-	++	-	-	+	-	+	-
200 mm Hg - 2 min	-	-	-	++	-	-	-	-	+	-
	-	-	-	+	-	-	-	-	+	-
	-	-	-	+	-	-	-	-	+	-
200 mm Hg - 10 min	-	+	-	++	-	-	+	-	+	-
	-	+	-	+	-	-	+	-	+	-
	-	+	-	+	-	-	+	-	+	-
200 mm Hg - 2 hrs	-	+	+	++	-	-	+	+	++	-
	-	++	++	++	-	-	++	++	++	-
	-	++	++	++	-	-	++	+	++	-

Table 5: *Intraneural edema formation following slow onset compression. See table 4 for further explanation. (Reproduced with permission from Spine, Olmarker et al 1989, Paper IV).*

The effects of experimental compression on intraneural edema formation in peripheral nerves have been studied previously, using similar techniques for compression and evaluation as those in the present study (Rydevik & Lundborg 1977). These authors found that an endoneurial edema was induced following compression at either 50 mm Hg for 4-6 hours or 200 mm Hg for 2 hours. The onset rate was not presented, but estimated to 3-5 seconds by the authors. It was thus somewhere between the two onset rates used in the present study. The results of the present study thus indicate that the endoneurial capillaries of nerve roots seem to be more susceptible to compression injury than the corresponding vessels of peripheral nerves.

In the same paper (Rydevik & Lundborg 1977), the effects of compression on the permeability of epineurial vessels was found to be similar to those in Paper IV. The epineurial vessels of the peripheral nerves are not protected by the perineurium. This may make them anatomically more comparable to the endoneurial capillaries in the nerve roots. These data suggest that the difference in susceptibility to compression injury between endoneurial capillaries in peripheral nerves and nerve roots may be based on the presence of the perineurium in the peripheral nerves.

V Effects of compression on impulse propagation of the porcine cauda equina.

The amplitude of the MAP-recordings obtained by intermittent stimulation caudal to the compression zone were always within 5% of the baseline value, which indicates stability of experimental conditions and caudal neuromuscular function.

There was no reduction of MAP-amplitudes for sham-compression or for compression at 50 mm Hg with the slow onset rate, (Figure 19 & Table 6). Compression at 50 mm Hg with the rapid onset rate induced a slight reduction of the MAP-amplitude, (Figure 19). This reduction was not significant as compared to slow onset rate or control, with the employed statistical method.

Compression at 100 and 200 mm Hg induced reductions in MAP-amplitude that were directly proportional to the applied pressure, (Figure 19 & Table 6). However, the reduction after rapid onset was generally more pronounced than after slow onset of compression. For these two pressure levels the differences between the two onset rates were found to be statistically significant ($p<0.01$), at corresponding compression levels.

	Pressure level	Reduction ± SD (%)
Sham-compression		0.3±0.7
Slow onset;	50 mm Hg	1±2
	100 mm Hg	25±13
	200 mm Hg	69±5
Rapid onset;	50 mm Hg	7±8
	100 mm Hg	79±6
	200 mm Hg	93±5

Table 6. *Average reduction of MAP-amplitude from initial value after 2 hours of compression. (Reproduced with permission from Spine, Olmarker et al 1990, Paper V).*

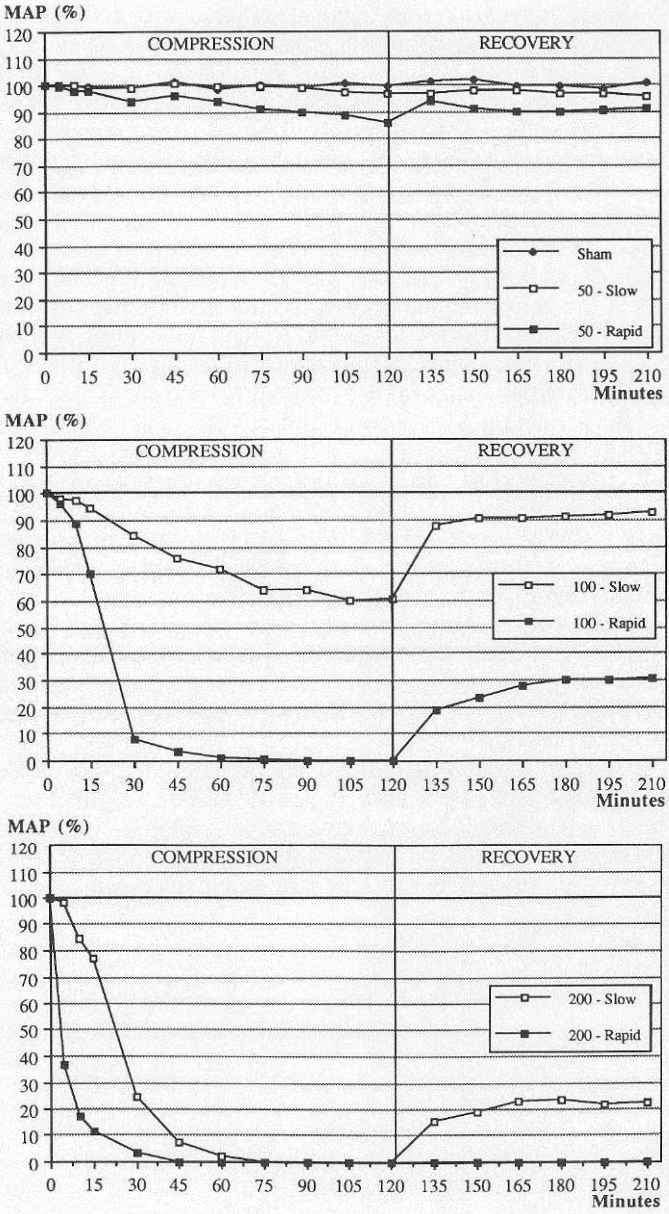

Figure 19. *Average amplitude of MAP (muscle action potential), representing conduction of the fastest conducting motor nerve fibers, expressed in percent of baseline value. The diagrams show the results of 2 hours of compression and 1.5 hours of recovery for sham-compression and for rapid and slow onset of compression at 50 mm Hg, 100 mm Hg and 200 mm Hg. (Reproduced with permission from Spine, Olmarker et al, Paper V).*

The MAP-amplitude recovered to close to baseline after compression at 100 mm Hg with the slow onset rate. However, after both 100 mm Hg with the rapid and 200 mm Hg with the slow onset rate of compression there was an incomplete recovery of the MAP-amplitude, (Figure 19). Following rapid onset of compression at 200 mm Hg there was no recovery in any of the experiments, (Figure 19).

Other experiments with cauda equina compression in the pig, using similar neurophysiologic analyses as in Paper V, gave results which were similar to those obtained with the slow onset rate (Pedowitz *et al* 1988, -89, Rydevik *et al* 1990b). The onset rate employed in those studies were 3-5 seconds, (*ie.*, between the two onset rates employed in Paper V).

Similar studies on a peripheral nerve, (*n tibialis*, rabbit), have demonstrated a 30 % decrease of the initial action potential after compression for 2 hours at 50 mm Hg (Rydevik & Nordborg 1980a). The onset rate was not presented, but estimated to 3-5 seconds by the authors. The effects on *n tibialis* were thus slightly more pronounced than the effects on the cauda equina seen in Paper V. Dahlin and collaborators recently reported that impulse propagation in *n peroneus communis* in rabbits, compressed with the same compression device as used by Rydevik and Nordborg for *n tibialis*, was more impaired than *n tibialis* at corresponding pressures (Dahlin *et al* 1989). Compression at 200 mm Hg in *n tibialis* resulted in a 85% decrease of the initial amplitude after 2 hours (Rydevik & Nordborg 1980a), and in *n peroneus communis* in a complete conduction block after 23 minutes (Dahlin *et al* 1989). It was suggested that this difference was based on differences in amounts of surrounding connective tissue sheaths between the two nerves (Dahlin *et al* 1989). These results thus indicate that there can be differences in compression susceptibility even between adjacent nerves in the same species. This also means that it may be difficult to make any general statements of differences in compression-induced impairment of impulse propagation between peripheral nerves and spinal nerve roots.

GENERAL DISCUSSION

ANIMALS AND ANAESTHESIA

The pig is a common experimental animal with certain similarities to the human anatomy (Mount & Ingram 1971). This includes the anatomy of the spine. However, to be able to interpret the results obtained from the presented compression model, the detailed normal neural and vascular anatomy of the pig cauda had to be established. This was performed in Paper I.

Anaesthesia was maintained and induced by a combination of four different anaesthetics. The anaesthesia was first induced by intramuscular injection of ketamine. This drug may elevate blood pressure and cerebrospinal fluid pressure. However, the duration of these effects is only 15-30 minutes, and therefore any influence on the experimental results should not be expected.

A combination of methomidate and azaperon was used to maintain anaesthesia. Methomidate is a hypnotic and azaperon is a neuroleptic. Both drugs are used for veterinary purposes, and the combination is sufficient to induce anaesthesia that will allow small to medium surgical procedures. The depth of anaesthesia was continuously registered by vital signs and neurological reflexes, and did not reveal any signs of pain in the animals.

In papers II, II and IV, suxamethonium was added to the methomidate/ azaperon anaesthesia during surgical exposure of the cauda equina. Suxamethonium is a depolarizing muscle relaxant. It may induce a slight elevation of the cerebrospinal fluid pressure. Its effects are potentiated by ketamine. However, the duration of action is very short. Since suxamethonium was used only during the surgical exposure of the cauda equina, an effect on the cerebrospinal fluid pressure is unlikely to have affected the results of the present investigation.

EXPERIMENTAL MODEL (PAPER I)

The normal neural and vascular anatomy of the porcine cauda equina was similar to that of the human cauda equina (Paper I). However, there were two anatomical features which will be discussed specifically.

First, with increasing age and bodyweight there was a sealing of the subarachnoid space that started from the caudal end of the nerve roots. This phenomenon was not observed in pigs below 40 kg bodyweight. It was recently observed that diffusion of nutrients from the cerebrospinal fluid may be an important nutritional pathway for the nerve roots (Rydevik *et al* 1990a). To mimic the anatomy of the human cauda equina, it may therefore advisable only to use pigs up to 40 kg bodyweight.

Second, the dorsal root gangliae of the compressed nerve roots were located cranial to the compression zone. By definition, the compressed segments of the nerve roots should therefore be termed "spinal nerves" instead of nerve roots. Fontana's spiral bands were also found to be present at the most caudal parts of some nerve roots. The question therefore arises whether the compressed parts of the nerve roots were morphologically more similar to peripheral nerves than spinal nerve roots.

By definition, the nerve roots are the part of the nervous system that run between the spinal cord and the dorsal root ganglion, or a corresponding level for the ventral roots. However, the difference in compression susceptibility between spinal nerve roots and peripheral nerves has been suggested to be based on differences in the surrounding connective tissue layers (Murphy 1977, Rydevik *et al* 1984). A relevant description of the spinal nerve root would thus be; the part of the nervous system that runs from the spinal cord and is enclosed only by the root sheath, cerebrospinal fluid and meninges. According to the present investigation, this description would be applicable to all parts

of the cauda equina compressed by the balloon. The microscopic anatomy typical of a peripheral nerve was instead found to be present only outside the spinal canal, (Figure 15 f, page 39).

There is an apparent difference in the vascular anatomy between the peripheral nerves and the nerve roots that may be of importance for differences in susceptibility to compression injury between these tissues. The effects of compression on nerve tissue at pressure levels below 200 mm Hg have been suggested to be based mainly on an impairment of the nutrition, rather than direct mechanical injury to the axons (Dahlin *et al* 1986a). However, the peripheral nerves have a much more developed network of arterioles and venules than the nerve roots, (Figures 16 a & f, page 40 & 42). Also, the main vessels of the cauda equina are always located superficially and might therefore easily be exposed to mechanical deformation, (Figures 15 a, page 37). Conversely, the vessels of the peripheral nerves may be found between the fascicles, in the epineurium, and may thereby be better protected from mechanical deformation, (Figure 15 f, page 39). This hypothesis is supported by experimental evidence which indicate that the pressure required to induce vascular stasis is lower for nerve roots (Paper II) than for peripheral nerves (Rydevik *et al* 1981), particularly on the venular side.

As opposed to the peripheral nerves, the nerve roots have no regional arteriolar blood supply. This might be particularly important in situations with compression at more than one site. The vascular anatomy of the porcine cauda equina, as described in Paper I, demonstrates all features that are characteristic of the vasculature of human spinal nerve roots (Parke & Watanabe 1985).

To achieve a reproducible pressure transmission from the compression balloon to the cauda equina it is important to fix the plexiglass plate and balloon as close to the cauda equina as possible, without compressing it *per se*, (Figure 8). This was also important in Paper II, in which the cauda equina was placed between the balloon and the plexiglass plate. The cauda equina was thus inevitably elevated by the balloon during compression. The elevation was measured to 2-3 millimeters. To study the effects of elevation on the blood flow, the balloon was inflated without the plexiglass plate mounted. This resulted in an elevation of 9-10 millimeters and did not result in any acute changes of the blood flow in the cauda equina vasculature, as judged by vital microscopy.

The presented model showed both a well-controlled pressure transmission and a close resemblance of neural and vascular anatomy to the human cauda equina. The easy surgical approach of the porcine cauda equina and the sufficient length of the nerve roots offer unique features for experimental studies on nerve roots. The present model allows for reproducible, pressure-induced changes in nerve root pathophysiology (Papers II-V). The porcine cauda equina may also be particularly suitable for chronic compression studies, since neurological deficits would be localized only to the tail.

EFFECTS OF COMPRESSION ON THE NUTRITIONAL SUPPLY TO THE PORCINE CAUDA EQUINA (PAPERS II & III)

Compression was found to impair the blood flow in the intrinsic vessels, particularly the venules, at very low pressure levels. In fact some venules were found to be occluded at 5-10 mm Hg. However, there were venules that did not become occluded until the cauda equina was exposed to compression at 60 mm Hg. This suggests that the intrinsic venules may have an uneven exposure to applied mechanical deformation. The cauda equina is not a homogenous structure. It is formed by a number of independent nerve roots. If a vessel is located in the groove formed by two nerve roots the superficial tissues need to be displaced before such a vessel would be exposed to the balloon pressure. It may therefore be more protected from mechanical deformation than if it was located on the surface of a nerve root or outside the spinal dura in the epidural fat. It is also evi-

dent that a venule that is located between two arterioles may not be occluded until the arteriles are more or less occluded. The finding that some venules were not occluded until high pressures were applied may thus probably be explained by the anatomical location of the vessels.

The venules may thus be occluded at pressures of 5-60 mm Hg. However, the results of Paper II do not indicate how blood flow might be affected at pressure levels below the occlusion pressure. Probably there is significant impairment of the blood flow already at pressure levels far below the occlusion pressure as well. Such an incomplete impairment of blood flow was indicated in a recent study on the same model as used in the present investigation (Olmarker *et al*, unpublished data). The results showed that complete restoration of venular blood flow, during stepwize deflation of the compression balloon, was not achieved until the compression was ended, (*ie.*, 0 mm Hg).

The flow in the capillaries was found to be dependant upon the venular flow. If the flow in the venules is impaired, there may be a reduced flow in the connected capillaries. This "retrograde stasis" has been suggested to be an important mechanism for the development of symptoms in the carpal tunnel syndrome (Sunderland 1976). Due to the less developed venular network (Parke & Watanbe 1985), capillaries in the nerve root may thus be more affected by venular stasis than the capillaries in peripheral nerves. Since the results indicated that venular occlusion pressure is lower in nerve roots than in peripheral nerves, retrograde stasis might affect the nerve root capillaries at lower pressure levels than in peripheral nerves.

The results in Paper II demonstrated that there was a correlation between the mean arterial blood pressure and the arteriolar occlusion pressure, (Figure 17, page 44). The average minimum pressure required to stop the blood flow in the arterioles (BPa) was therefore probably also higher than might be excpected in pigs with lower mean arterial blood presure. However, since there was no correlation between the mean arterial blood pressure and the pressure required to stop the blood flow in capillaries and venules, the obtained results for these two vessel types would probably not have been affected by the elevated blood pressure.

Nutrients are transported to the axons of the cauda equina both by the intrinsic vessels and by diffusion from the surrounding cerebrospinal fluid (Rydevik *et al* 1990a). The cerebrospinal fluid pressure in pigs is about 8-11 mm Hg (Mount & Ingram 1971). When the cauda equina is exposed to pressures of 5-10 mm Hg, which is known to induce venular congestion in the most compression susceptible venules (Paper II), there is thus probably a certain amount of cerebrospinal fluid present around the nerve roots. Since diffusion from the cerebrospinal fluid is an important nutritional pathway for the nerve roots (Rydevik *et al* 1990a), one may speculate that such diffusion might compensate for venular congestion with subsequent retrograde stasis of capillary networks. However, the results of Paper III, which reflect the total nutritional transport to the nerve roots, demonstrated that there were significant effects on the nutrition even at these low pressure levels. In fact, there was a statistically significant reduction of the nutritional transport, as compared to control, when only the balloon and plexiglass plate were placed on top of the cauda equina. Together, the balloon and plexiglass weigh 0.24 gram. The compressed area of the cauda equina was approximately 48 mm^2. The pressure on the cauda equina, induced by the uninflated balloon and plexiglass, was therefore much less than 1 mm Hg, (1 gram/mm^2 is equal to 76 mm Hg). Since compression-induced effects on the nutritional supply to the nerve roots were present even at this low pressure level, it seems that diffusion from the cerebrospinal fluid can not completely compensate for compression-induced effects on the blood flow in the intrinsic vessels. Compression-induced effects of either of the two transport mechanisms can not be separated using the present experimental model. The observed reduction of the nutritional

transport during sham-compression can therefore not specifically be contributed to either of them. The observed effect might be based on congestion of superficially located venules, and that diffusion from the cerebrospinal fluid may not have time to compensate for this loss during the 5 minutes of methyl glucose circulation time. However, although the mechanism is not clear, the study demonstrates that there may be impairment of the nutritional transport present even at extremely low pressure levels, particularly since the reduction was so clearly located to the "compression zone", (Figure 18, page 46). The possible significance for nerve root nutrition and function, acute and long-term, remains to be elucidated.

According to Paper II, compression of the cauda equina at 200 mm Hg will induce ischemia. However, some methyl-glucose was found within the compression-zone at 200 mm Hg - slow onset in Paper III, (Figure 18). This suggests that there are transport mechanisms present at this high pressure level. If the presence of methyl-glucose within the compression-zone was due to contamination of the specimens, there would probably not have been such a distinct difference between the two onset rates. However, there are at least three other possibilities which should be considered. First, methyl-glucose might have reached the compression zone by diffusion from the adjacent, and nutritionally better provided, parts of the nerve roots. However, since this probably would have resulted in a gradient of methyl-glucose in the compression-zone, this mechanism seems unlikely. Second, due to folds in the dura, cerebrospinal fluid might have been present to some extent around the nerve roots. In this way, methyl-glucose should have been able to reach the compressed nerve tissue due to diffusion. Although diffusion from the cerebrospinal fluid was considered not to fully compensate for the compression-induced reduction seen following sham-compression, such diffusion can not be excluded as a possible nutritional pathway at 200 mm Hg compression. The third, and most probable explanation, is that not all parts of the nerve roots may have been exposed to 200 mm Hg. As discussed, the cauda equina is not a homogeneous structure. It must be considered that blood vessels, that are located in the grooves between the different nerve roots, may escape some of the compression. Therefore, the most probable explanation for the presence of methyl-glucose within the compression-zone during compression at 200 mm Hg, is that there is a blood flow still present in a few arterioles located between the separate nerve roots. It is also known that there is a pressure gradient when pressure is applied to a structure, with the highest pressure closest to the compressing agent (Hargens *et al* 1987, Crenshaw *et al* 1988). It might therefore be possible that, although there was a pressure of 200 mm Hg acting on the surface of the nerve roots, a lower pressure level might be present in the center of the nerve roots.

There was a striking difference in the levels of methyl-glucose outside the compression-zone between the rapid and the slow onset of compression at corresponding pressure levels. The R/Rco-graphs at the slow onset rate approached the control graph more rapidly than at the rapid onset rate. This observation may be important for understanding the pathophysiologic mechanisms behind the differences in effects, seen between the two onset rates employed in the present study. Therefore, the possible mechanisms for this effect will be discussed below in the paragraph "rapid *vs* slow compression".

The R/Rco-graphs at the slow onset rate also suggested that the baselines outside the compression zone were dependant on the applied pressure. This may be an effect of stasis of the intrinsic vasculature at locations relativelly far from the compression zone, due to an impaired blood flow through the compressed nerve segment. The present study only comprized analyses of nerve root tissue upto 7 mm outside the compression zone. It is therefore unclear how far from the compression zone this effect was present. This difference between baselines at various compression pressure levels may also be the re-

sult of, for instance, vascular constriction outside the compressed segment due to metabolic or neurologic factors.

INTRANEURAL EDEMA FORMATION FOLLOWING COMPRESSION OF THE PORCINE CAUDA EQUINA (PAPER IV)

Intraneural edema is formed due to an increase in microvascular permeability of the endoneurial capillaries (Lundborg 1975, Rydevik & Lundborg 1977). This results in a leakage of fluid and macromolecules from these vessels out into the endoneurial space, which may negatively influence the nutrition of the nerve tissue by separating the axons and by altering the ionic balance within the endoneurium. Increasing amounts of fluid in the endoneurial space might also induce an increase in the endoneurial fluid pressure (Low & Dyck 1977, Myers & Powell 1981), particularly at locations where the nerve roots are enclosed by rigid structures, as for instance at the level of the intervertebral foramen. This may result in an subsequent impairment of the microcirculation within the endoneurium. An intraneural edema might thus result in a "compartment syndrome" within the peripheral nerve or the nerve root (Lundborg *et al* 1983, Rydevik *et al* 1989a), which may impair the nutritional supply (Low *et al* 1982, Myers *et al* 1982) and thus the function of the nerve roots.

Compression may induce edema formation in peripheral nerve tissue (Rydevik & Lundborg 1977), and dorsal root gangliae (Rydevik *et al* 1989a). According to Paper IV, such edema may be more easily induced in the cauda equina than in peripheral nerves (Rydevik & Lundborg 1977). An intraneural edema was also noted in Paper II by vital microscopy. However, the pressure/time thresholds for occurrence of such edema was higher than observed in Paper IV. This difference was most probably due to the higher sensitivity of the dye-tracing technique, employed in Paper IV. An intraneural edema, as judged by vital microscopy, may be difficult to detect, since this distinction is based upon increasing opacity of the nerve roots and difficulties in focusing on the borders of the intraneural vessels.

Intraneural edema may be formed as the result of ischemia. The blood-nerve barrier of peripheral nerves has been shown to be impaired, with a subsequent edema formation, when exposed to ischemia for 8 hours or more (Lundborg 1970). However, if compression was added, edema formation was observed after 2-4 hours (Lundborg 1970). The combination of compression and ischemia is thus more deleterious than ischemia alone regarding the integrity of the blood-nerve barrier in peripheral nerves.

Edema was found to be most pronounced at the edges of the compressed cauda equina segment (Paper IV). This is in agreement with previous observations in compressed peripheral nerves (Rydevik & Lundborg 1977). The mechanism for this phenomenon may be related to a displacement of the compressed nerve tissue (Rydevik *et al* 1984, -89b). When a nerve is compressed. there is a displacement of the compressed nerve tissue towards the uncompressed parts of the nerve (Ochoa *et al* 1972, MacGregor *et al* 1975). The superficial parts of the nerve are displaced more than the deeper parts. Shearing may thus occur between the different layers of the displaced nerve, which are maximized at the edge zones (Rydevik *et al* 1984). This shearing would be particularly injurious to the blood vessels which run obliquely in the endoneurial space.

Due to the less developed blood-nerve barrier of the endoneurial capillaries, a compression-induced edema has been suggested to be formed more easily in nerve roots than in peripheral nerves (Rydevik *et al* 1984). This suggestion was supported by the results of the present investigation (Paper IV). Another factor for the development of an intraneural edema that has been suggested is the release of "heparin and biogenic amines" from endoneurial mast cells (Lundborg 1975). However, unlike in peripheral nerves,

there are no mast cells present in the endoneurium of the spinal nerve roots (Gamble 1964).

Although more easily induced in nerve roots, intraneural edema is probably more deleterious to the peripheral nerves, once formed. In a peripheral nerve, each nerve fascicle is surrounded by the perineurium. The perineurium constitutes an efficient diffusion barrier for fluid and macromolecules (Olsson & Reese 1969, -71b, Klemm 1970, Rydevik & Lundborg 1977). An edema will therefore be "trapped" within the perineurium. The spinal nerve roots do not possess a similar diffusion barrier. An endoneurial edema will therefore more easily be drained out into the surrounding cerebrospinal fluid. However, at locations where the meninges enclose the nerve roots tightly, such as the intervertebral foramen, an edema may be more deleterious. Since the dorsal root ganglion is enclosed with a strong meningeal capsule, this location could also be particularly susceptible to the effects of an intraneural edema (Rydevik *et al* 1989a).

Intraneural edema is probably a common feature in nerve root compression lesions. The presence of edema in compressed lumbosacral nerve roots has been observed both with CT-scans (Takata *et al* 1988) and in histologic sections of nerve roots at cadaveric studies (Hoyland *et al* 1988). Even if compressed lumbosacral nerve roots are decompressed surgically, it would probably take some time for edema to be eliminated from the endoneurial space. The presence of edema may thus impair the nutrition of the nerve roots for longer periods of time than the compression itself. A longstanding edema may also be related to the formation of an intraneural fibrotic scar (Lundborg 1975, Rydevik *et al* 1976). Formation of an intraneural edema, with or without fibrosis, might thus contribute to the slow recovery observed in some patients with nerve root compression syndromes.

EFFECTS OF COMPRESSION ON NUTRITION (PAPERS II & III) vs FUNCTION OF THE PORCINE CAUDA EQUINA (PAPER V)

It was recently demonstrated that 50 mm Hg compression of spinal nerve roots using the present compression model, did not significantly impair impulse propagation during a 2 hour compression period (Pedowitz *et al* 1988, Rydevik *et al* 1990b) and only minor changes were observed during a 4 hour compression period (Pedowitz *et al* 1989). This is in agreement with the results of Paper V. The effects of compression on impulse propagation might thus seem contradictory to the results of Paper III, which showed a marked reduction of the nutritional transport at 50 mm Hg at both onset rates. However, there might probably be a delay before a nutritional impairment may lead to changes in nerve conduction properties. A significant impairment of the nutritional transport mechanisms may be injurious to the normal function of the nerve roots during prolonged compression periods. In various clinical situations, the compression periods are more likely to last for days or months rather than for minutes or hours. The results of papers II and III indicate that a significant impairment of the nutritional transport may be induced at 10-50 mm Hg. This suggests that neural dysfunction could be induced, even by low compression pressures, in nerve root compression syndromes.

Similar to papers III and IV, there was a significant difference in effects between the two compression onset rates employed. The mechanisms involved will be discussed below in the paragraph "rapid *vs* slow onset of compression".

RAPID vs SLOW ONSET OF COMPRESSION

The present investigation demonstrated that a rapid compression onset rate (0.05-0.1 sec.) induced more pronounced effects than a slower onset rate (20 sec.) on nutritional transport (Paper III), vascular permeability (Paper IV), and impulse propagation (Paper V) in the spinal nerve roots.

The first question that arises is if this observed difference may be based on differences in compression exposure, (*ie.*, compression level x compression duration). During the slow onset, the compression was not 100% of the intended value until 20 seconds after initiating the compression. The nerve roots subjected to the rapid onset rate were thus exposed to a higher compression exposure, (Figure 20). However, the compression exposure ratio between slow and rapid onset rates are 92% at compression for 2 minutes, 98.4% at 10 minutes and 99.9% at 2 hour compression. These differences thus seem too small to be solely responsible for the pronounced differences seen in papers III-V. Other mechanisms may therefore probably be found in the initial reaction pattern of the nerve tissue to the applied compression.

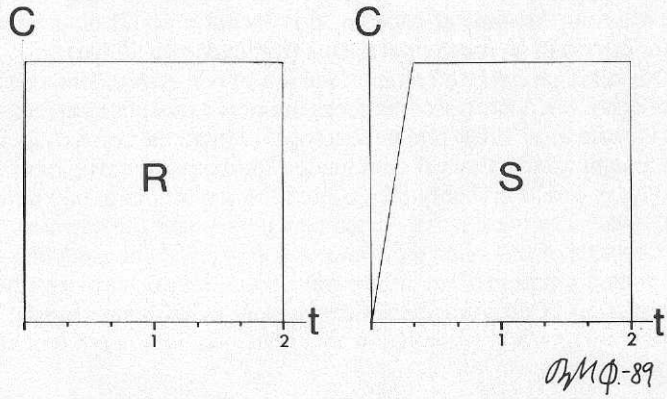

Figure 20: *Compression exposure during 2 minutes of compression for the rapid onset rate* (R) *and the slow onset rate* (S). *(C = compression pressure level, t = time).*

Nerve compression induces mechanical deformation of the nerve tissue and also effects on the nutritional supply to the nerve tissue (Dahlin *et al* 1986a). According to Paper V, there was no difference in reduction of muscle action potential between the two onset rates during the first minute of compression, (Figure 19, page 50). This implies that there are probably no severe mechanical effects, such as axonal breakage, induced early in the compression onset. However, since there is a difference visible after 2-5 minutes, any potential mechanisms are probably present early in the compression period, most probably during the compression onset. The results of Paper V also indicate that the effects are progressive, since the MAP-amplitudes decreased with time.

Nerve tissue has visco-elastic properties (Rydevik *et al* 1989b, -90c). This implies that the rate of mechanical deformation is of a certain importance for the injury pattern. The energy that is imposed on the nerve tissue during compression is probably equivalent between the two onset rates. However, at the rapid onset rate, the energy is transferred to the nerve tissue during a shorter period of time than at the slow onset rate. This implies that the energy per time unit transferred to the nerve tissue is higher at the rapid onset rate, a theory that might serve as one general explanation for the observed differences between the two onset rates.

If the energy that is transferred from the compresion balloon to the nerve tissue can not be absorbed as movement or heat, there will be plastic deformation, (*ie.*, irreversible mechanical deformation), of the compressed tissue. This would probably result in structural changes, even at the sub-cellular level. However, although such a mechanism might be present, there is in fact a movement of the nerve tissue from the compressed to the uncompressed parts of the nerve roots (Ochoa *et al* 1972, MacGregor *et al* 1975).

This displacement of nerve tissue may suggests one possible theory for the observed difference between rapid and slow onset rates, that might also be supported by results from Papers III-V:

An arbitrary point (A) is displaced from its initial position (A_o) to the position at equilibrium (A_e) during compression, (Figure 21). The distance A_o-A_e is dependant on the magnitude of the applied compression pressure and on the biomechanical properties of the nerve tissue. The rate at which the point A is displaced is dependant on the onset rate of the applied compression. If the compression is applied slowly, there will be a slow displacement of A towards A_e. If the compression onset rate is increased, the displacement rate will increase accordingly. However, at a certain threshold of onset rate, A may be displaced slightly further than to A_e, which means that there will be an "over-displacement" of A before it will rebound towards A_e, (Figure 21). With increasing onset rates, this over-displacement will increase. A rapid compresion onset rate would thus induce a higher over-displacement than a slower onset rate. Although probably not present more than during fractions of seconds, this over-displacement might induce local mechanical deformation that might negatively influence the normal nutrition and function of the spinal nerve roots.

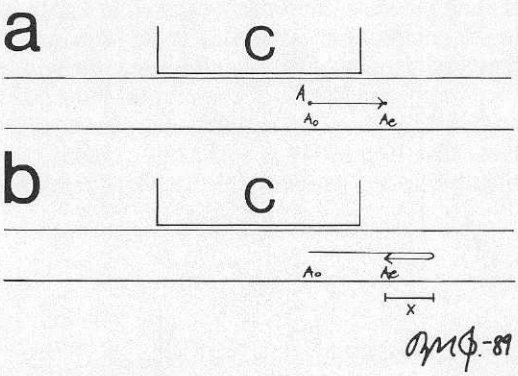

Figure 21. *When compression is applied gradually (a), there will be a slow displacement of an arbitrary point (A) from its initial position (A_O) to its position at equilibrium (A_e) during compression. If the compression is applied rapidly (b), A may be displaced slightly further before rebounding to A_e. There will thus an "over-displacement" of A (x) before reaching equilibrium during compression.*

It has been observed that compression-induced effects on peripheral nerves are most pronounced at the edges of the compression zone (Bentley & Schlapp 1943, Edwards & Cattell 1928, Ochoa *et al* 1972, Rydevik & Lundborg 1977). It has been suggested that this so called "edge-effect" is due to a displacement of the compressed nerve tissue towards the uncompressed parts of the nerve. Mathematical models have indicated that the displacement is maximal at the edges of the compressed segment, and also that the superficial parts of the nerve are displaced more than the deeper parts (Rydevik *et al* 1984, -89b). During displacement, occurs between the different layers of the nerve. A structure passing obliquely through the nerve tissue might therefore be more susceptible to injury induced by the displacement. This would suggest that endoneurial capillaries would be more at risk, than longitudinally running nerve fibers, of being injured by the induced shear-strain. The injury pattern for the nerve fibers with paranodal invagination (Ochoa

et al 1972, Rydevik & Nordborg 1980a) is compatible with deformation due to the longitudinal displacement *per se* in a given layer of the nerve or nerve root (Rydevik *et al* 1989b).

The rapid onset rate was found to increase the microvascular permeability more than the slow onset. The edema that was formed due to this increase in permeability was most pronounced at the edge-zones. This suggests that the displacement might be of importance for the increase in vascular permeability. If the difference in microvascular permeability should be based on differences in over-displacement induced by the two compression onset rates, the injury would have been induced early in the compression onset. This would result in a vascular injury with subsequent progressive edema formation developing in the nerve. This mechanism may thus relate to the progressive impairment of impulse propagation seen in Paper V. An edema would probably not be formed only within the compression zone. Instead it would be formed mainly in the uncompressed parts of the nerve roots, adjacent to the compression zone. In such a way, it could thus interfere with the nutritional transport to both the compressed and the uncompressed parts adjacent to the compression zone of the nerve roots. The degree of edema would therefore also relate to the width of the nutritionally impaired nerve root segment, (Figure 22). The zone of impaired nutritional transport outside the compression zone may also relate to the differences in R/Rco-ratios outside the compression zone between the rapid and the slow onset rate observed in Paper III, (Figure 18, page 46), as well as within the compression zone, due to an impairment of the nutritional transport into the compressed segment. The hypothesis that the width of the compressed segment is of importance for the magnitude of compresion-induced effects is partly supported by on-going studies in which two balloons are placed over the cauda equina. Preliminary results show that 10 mm Hg is sufficient to induce a significant impairment of MAP-amplitude when two balloons are placed 10 mm apart, (Olmarker *et al* 1990).

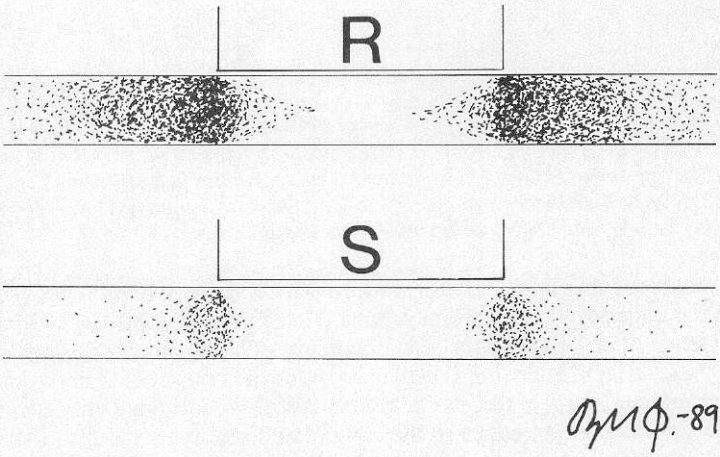

Figure 22. *Drawing illustrating the hypothesis that a more pronounced edema might affect a wider nerve root segment than a less pronounced edema. The edema induced by a rapid onset rate (top) is more pronounced than for a slow onset rate (bottom). The former may thus affect a longer segment of the nerve roots.*

Grundfest observed in *in vitro* experiments that a nerve that is subjected to high pressures in a pressure chamber is relatively resistant to compression regarding impulse propagation as long as adequate concentrations of oxygen are present (Grundfest 1936). However, at comparatively low pressure levels, local compression can block impulse conduction (Bentley & Schlapp 1943, Rydevik & Nordborg 1980a). These data have stressed the importance of the pressure gradient between compressed and uncompressed nerve tissue. It is possible that pressure distribution at the compression site may vary between the two onset rates, and that this may contribute to the observed differences.

Another possible mechanism that might be responsible for the difference in effects between the two onset rates is a trapping phenomenon of blood within the compression zone. Blood was often seen macroscopically in the vessels within the compression zone in nerve roots exposed to the rapid onset rate. This was not observed at the slow onset rate. It thus seems that the vessels might have been occluded at the edge zones by the displacement, when exposed to the rapid onset rate (Lauritzen *et al* 1981). The blood was thus "trapped" within the compression zone. However, when applying pressure at the slow onset rate, the blood might have been able to leave the compressed segment. Trapped leucocytes may leak agents such as toxic oxygen compounds, proteolytic enzymes and longacting oxidants, which may damage the endothelial cells of the endoneurial capillaries (Ernst *et al* 1987). These substances may impair the normal barrier function of the capillaries, which thus may lead to edema formation. Such mechanisms may be initiated when the blood cells are in contact with oxygenated blood. The most critical phase, with respect to trapped blood cells, will therefore be the recirculation of a compressed nerve segment. However, trapped blood cells might probably also reach the edges of the compression zone with time. Since oxygenated blood may be present in the nerve tissue adjacent to the compression zone (Paper III), there is a possibility that any effects of substances from the formerly trapped blood cells may act at the edges of the compressed nerve segment. In such a way they might contribute to differences in edema formation between the two compression onset rates studied, which were most pronounced at this location (Paper IV).

SUMMARY & CONCLUSIONS

Paper I. A model for experimental studies of acute, graded compression of the cauda equina in pigs was presented. Detailed analyses of the neural and vascular anatomy demonstrated a close resemblance to the human cauda equina. There were structural and vascular differences between spinal nerve roots and peripheral nerves that could contribute to differences in compression susceptibility between these two parts of the nervous system. The pressure transmission from the balloon to the nerve roots showed to have a high accuracy.

Paper II. The occlusion-pressures for the arterioles, capillaries and venules of the cauda equina were determined. Arteriolar blood flow was stopped at a pressure close to the mean arterial blood pressure. Capillary blood flow was found to be dependent upon flow in the connected venules. The blood flow in some venules was found to be stopped at 5-10 mm Hg. However, venular occlusion pressures ranged from 5 to 60 mm Hg. Compression up to 200 mm Hg for 2 hours did not induce a "no-reflow" phenomenon when the compression was ended. However, a transient hyperemia was noted at all pressure/time relations studied, indicating nutritional deficit in the compressed segment during compression. Signs of edema were seen in nerve roots exposed to compression for 2 hours at either 50 or 200 mm Hg.

Paper III. The nutritional supply to the cauda equina was found to be impaired at low pressure levels (less than 10 mm Hg). Diffusion from adjacent tissues with a better nutritional supply, including the cerebrospinal fluid, could thus not compensate comple-

tely for compression-induced effects on the transport of nutrients. However, a certain nutritional supply to the compressed segment was present even at 200 mm Hg compression. There were more pronounced effects on the nutritional supply induced by a rapid (0.05-0.1 sec.) than a slow (20 sec.) compression onset rate. Nutritional impairment was noted both within and outside the compressed nerve segment.

Paper IV. An increase in vascular permeability was induced by compression at 50 mm Hg for 2 minutes. The magnitude of this permeability increase was dependant on both the magnitude and the duration of compression. The permeability increase was more pronounced for the rapid than for the slow compression onset rate at all pressure/time relations studied.

Paper V. Reduction of muscle action potential (MAP) amplitude in tail muscles, after stimulation cranial to the compression zone, was induced by compression at 100 and 200 mm Hg for 2 hours. The reduction was more pronounced at 200 than 100 mm Hg. The recovery after compression was also slower at 200 than 100 mm Hg. Sham compression and compression at 50 mm Hg induce no or only minor reduction of MAP-amplitude. The reduction of MAP-amplitude was more pronounced for the rapid than for the slow compression onset rate, and was statistically significant at 100 and 200 mm Hg compression.

The spinal nerve roots are generally well protected from external trauma by the vertebrae. However, if subjected to a direct trauma the nerve roots may be severely affected, even at low pressure levels. The compression onset rate also seems to be of importance for the degree of compression-induced effects that might be acquired in various conditions resulting in nerve root compression.

The present investigation focused on the acute effects of nerve root compression in an experimental model. The pathogenetics in clinical nerve root compression conditions is of course much more complex. For instance, the presence of an intraneural edema may be related to fibroblast invasion. Furthermore, chronic impairment of axonal transport and intraneural microcirculation may induce changes that could not be assessed in a model for acute compression. Such a complex sequence of events could via various mechanisms lead to nerve root pain production and nerve dysfunction. However, although the present investigation was limited to acute changes in nerve root nutrition and function, it may serve as a basis for continued evaluation of pathogenetic mechanisms in both acute and chronic nerve root compression disorders.

ACKNOWLEDGEMENTS

This thesis is the result of cooperation between the Laboratory of Experimental Biology, Department of Anatomy and the Department of Orthopaedics, Sahlgren Hospital, both at the University of Göteborg.

I would like to express my sincere gratitude to:
Professor *Per-Ingvar Brånemark*, head of the Laboratory of Experimental Biology, for providing excellent working conditions and for his generous support throughout the investigations.
Associate professor *Björn Rydevik*, for initiating the investigations, for introducing me into the field of experimental research and for stimulating collaboration.
Associate professor *Sten Holm*, for introducing me into the field of experimental surgery and for stimulating collaboration.
Professor *Alf Nachemson*, chairman of the Department of Orthopaedics, for his generous support throughout the investigations.
Dr. *Robert Pedowitz*, University of California San Diego, USA, for inspiration and for scientific and linguistic guidance.
Associate professor *Ulf Bagge* and Professor *Tommy Hansson*, for stimulating collaboration and discussions.
Anna-Lena Rosenqvist for excellent technical assistance.
Professor *Richard Skalak*, University of California San Diego, USA, Professor *Malcolm Pope*, Vermont University, Burlington, USA, and Professor *Manohar Panjabi*, Yale University, New Haven, USA, for valuable comments on the nerve root compression model and on biomechanical aspects of nerve compression.
Assistant professor *Nils Danielsen* and Assistant professor *Lars B Dahlin* for introducing me to experimental research.
Erik Hult and *Lars Ekström* for stimulating discussions and valuable biomechanical comments.
Family, friends and colleagues.

The investigations have been supported by grants from the Swedish Medical Research Council (8685), the Folksam Research Foundation, the Institute for Applied Biotechnology, Greta and Einar Asker's Research Foundation, the Carin Trygger Memorial Foundation, the Gothenburg Medical Society and the University of Göteborg.

REFERENCES

Adamkiewicz A: Die Blutgefässe des menschlichen Rückenmarkes. I. Die Gefässe der Rückenmarkssubstanz. Sitzungsb. d. k. Akad. d. Wissensch. in Wien. math.-naturw. 84:469-502, 1881

Adamkiewicz A: Die Blutgefässe des menschlichen Rückenmarkes. II. Die Gefäse der Rückenmarksoberfläche. Sitzungsb. d. k. Akad. d. Wissensch. in Wien math.-naturw. 85:101-130, 1882

Adams HD & van Geertruyden HH: Neurolgic complications of aortic surgery. Ann Surg 144:574-610, 1956

Andres KH: Über die Feinstruktur der Arachnoidea und Dura mater von Mammalia. Z Zellforsch 79:272-295, 1967

Arnoldi CC, Brodsky AE, Cauchoix J, Crock HV, Dommisse GF, Edgar MA, Gargano FP, Jacobson RE, Kirkaldy-Willis WH, Kurihara A, Langenskiöld A, Macnab I, McIvor GWD, Newman PH, Paine KWE, Russin LA, Sheldon J, Tile M, Urist MR, Wilson WE & Wiltse LL: Lumbar spinal stenosis and nerve root entrapment syndromes. Definition and classification. Clin Orthop 155:4-5, 1976

Arvidson B: A study of the perineurial diffusion barrier of a peripheral ganglion. Acta Neuropathol (Berl) 46:139-144, 1979a

Arvidson B: Distribution of intravenously injected protein tracers in peripheral ganglia of adult mice. Exp Neurol 63:388-410, 1979b

Bailey P & Casamajor L: Osteo-arthritis of the spine as a cause of compression of the spinal cord and its roots. With report of 5 cases. J Nerv Ment Dis 38:588-609, 1911

Bentley FH & Schlapp W: The effects of pressure on conduction in peripheral nerve. J Physiol 72-82, 1943

Berthold CH, Carlstedt T & Corneliuson O: Chapter 6. Anatomy of the nerve root at the central-peripheral transitional region. In: Peripheral Neuropathy, vol 1. PJ Dyck, PK Thomas, EH Lambert, R Bunge (Eds). WB Saunders Company, Philadelphia, London, Toronto, Mexico City, Rio de Janerio, Sydney & Tokyo, pp 156-170, 1984

Bromage PR: Epidural analgesia. WB Saunders Co., Philadelphia, 1978

Burton CV: Diagnosis and treatment of lateral spinal stenosis: Implications regarding the "failed back surgery syndrome". Spine update, 235-242, 1984

Charnley J: The imbibition of fluid as a cause of herniation of the nucleus pulposus. Lancet 1:124-127, 1952

Ciric I, Mikhael MA, Tarkington JA & Vick NA: The lateral recess syndrome. A variant of spinal stenosis. J Neurosurg 53:433-443, 1980

Clarke E & Bearn JG: The spiral nerve bands of Fontana. Brain 95:1-20, 1972

Coggeshall RE, Coulter JD & Willis WD Jr: Unmyelinated axons in the ventral roots of the cat lumbosacral enlargement. J Comp Neurol 153:39-58, 1974

Cohen MS, Wall EJ, Brown RB & Garfin SR: Cauda equina anatomy. Part II: Extrathecal nerve roots and dorsal root ganglia. Spine (in press), 1990

Corbin JL: Anatome et pathologie arterielles de la moelle. Masson et Cie, Paris, 1961

Crenshaw AG, Hargens AR, Gershuni DH & Rydevik B: Wide tourniquet cuffs more effective at lower inflation pressures. Acta Orthop Scand 59:447-451, 1988

Crock HV & Yoshizawa H: The blood supply of the lumbar vertebral column. Clin Orthop 115:6-21, 1976

Crock HV: Normal and pathological anatomy of the lumbar spinal nerve root canals. J Bone Joint Surg 63B:487-490, 1981

Dahlin LB, Rydevik B, McLean WG & Sjöstrand J: Changes in fast axonal transport during experimental nerve compression at low pressures. Exper Neurol 84:29-36, 1984

Dahlin LB, Rydevik B & Lundborg G: Pathophysiology of nerve entrapments and nerve compression injuries. In: Tissue nutrition and viability. Hargens AR (ed). Springer-Verlag, Berlin, Heidelberg & New York, pp135-160, 1986a

Dahlin LB, Sjöstrand J & McLean WG: Graded inhibition of retrograde axonal transport by compression of rabbit vagus nerve. J Neurol Sci 76:221-230, 1986b

Dahlin LB & McLean WG: Effects of graded experimental compression on slow and fast axonal transport in rabbit vagus nerve. J Neurol Sci 72:19-30, 1986c

Dahlin LB, Shyu BC, Danielsen N & Andersson SA: Effects of nerve compression or ischemia on conduction properties of myelinated and non-myelinated nerve fibres. An experimental study in the rabbit common peroneal nerve. Acta Physiol Scand 136:97-105, 1989

Delamarter RB, Bohlman HH, Dodge LD & Biro C: Experimental lumbar spinal stenosis: Analysis of the cortical evoked potentials, microvasculature and histopathology. J Bone Joint Surg 72A:110-120, 1990

Desproges-Gotteron R: Contribution à l'étude de la sciatique paralysante. Thesis no 342, Paris, 1955

Dommisse GF: Morphological aspects of the lumbar spine and lumbosacral region. Orthop Clin N Am 6:163-175, 1975

Domisse GF: Arteries and veins of the lumbar nerve roots. Clin Orthop 115:22-29, 1976

Duret H: Note sur les artères nourricières et sur les vaisseaux capillaires de la moelle épinière. Progr. méd. 1:284, 1873a

Duret H: Conclusion d'un mémoire sur la circulation bulbaire. Arch Physiol Norm et Path 50:88-89, 1873b

Edwards DJ & Cattell MK: Further observations on decrement in nerve conduction. Am J Physiol 87:359-367, 1928

Ernst E, Hammerschmidt DE, Bagge U, Matrai A & Dormandy JA: Leukocytes and the risk of ischemic disease. JAMA 257:2318-2324, 1987

Fowler TJ & Ochoa J: Unmyelinated fibers in normal and compressed peripheral nerves of the babboon: A quantitative electron microscopic study. Neuropathol Appl Neurobiol 1:247-265, 1975

Fried LC & Doppman J: The arterial supply to the lumbo-sacral spinal cord in the monkey. A comparison with man. Anat Rec 178:41-48, 1958

Gamble HJ: Comparative electron-microscopic observations on the connective tissues of a peripheral nerve and a spinal nerve root. J Anat (Lond) 98:17-25, 1964

Gamble HJ & Eames RA: Electron microscopy of human spinal-nerve roots. Arch Neurol 14:50-53, 1966

Gasser HS & Erlanger J: The role of fiber size in the establishment of a nerve block by pressure and cocain. Am J Physiol 88:581-591, 1929

Gelfan S & Tarlov IM: Physiology of spinal cord, nerve root and peripheral nerve compression. Am J Physiol 185:217-229, 1956

Ghormley RK: Low back pain with special reference to the articular facets, with presentation of an operative procedure. JAMA 101:1773-1777, 1933

Gillilan LA: The arterial blood supply of the human spinal cord. J Comp Neurol 110:75-103, 1958

Goldthwait JE: The lumbo-sacral articulation. An explanation of many cases of "lumbago", "sciatica" and paraplegia. Boston Med Surg J 164:365-372, 1911

Grundfest H: Effects of hydrostatic pressure upon the excitability, the recovery, and the potential sequence of frog nerve. Cold Spring Harb Symp Quant Biol 4:179-187, 1936

Haller FR & Low FN: The fine structure of the peripheral nerve root sheath in the subarachnoid space in the rat and other laboratory animals. Am J Anat 131:1-20, 1971

Hammerstad JP, Lorenzo AV & Cutler RWP: Iodide transport from the spinal subarachnoid fluid in the cat. Am J Physiol 216:353-358, 1969

Hargens AR, McClure AG, Skyhar MJ, Lieber RL, Gershuni DH & Akeson WH: Local compression patterns beneath pneumatic tourniquets applied to arms and thighs of human cadavera. J Orthop Res 5:247-252, 1987

Hasue M, Kikuchi S, Sakuyama Y & Ito T: Anatomic study of the interrelation between lumbosacral nerve roots and their surrounding tissues. Spine 8:50-58, 1983

Hasue M, Kunogi J, Konno S & Kikuchi S: Classification by position of dorsal root ganglia in the lumbosacral region. Spine 14:1261-1264, 1989

Hendry NGC: Hydration of the nucleus pulposus and its relation to intervertebral disc derangement. J Bone Joint Surg (Br) 40:132-144, 1958

Herren RY & Alexander L: Sulcal and intrinsic blood vessels of human spinal cord. Arch Neurol Psychiat 41:678-687, 1939

Hildebrand C, Risling M & Dalsgaard C-J: Magendies lag om ryggmärgens ventrala och dorsala rötter gäller ännu. Läkartidningen (Swedish, with abstract in english) 86: 2597-2599, 1989

Holm S, Maroudas A, Urban JPG, Selstam G & Nachemson A: Nutrition of the intervertebral disc. Connect Tiss Res 8:101-119, 1981

Holm S & Urban JPG: The intervertebral disc: Factors contributing to its nutrition and matrix turnover. In: Joint loading: Biology and health of articular structures. H Helminen (ed). Williams & Wilkins, Baltimore & London, pp187-226, 1987

Hofmann M: Die Befestigung der Dura Mater im Wirbelkanal. Arch Anat Physiol (Anat Abteilg) 403, 1898

Hörnicke H: Blutdruck des Schweines unter verschiedenen Einflüssen. Eine Übersicht. Arch Exp Vet Med 20:1035-1047, 1966

Hoyland JA, Freemont AJ & Jayson MIV: Peri-radicular vascular changes in relation to disc prolapse and osteophytosis. Trans. the International Society for the Study of the Lumbar Spine, Miami, Florida, April, 1988

Jacobs JM, MacFarlane RM & Cavanagh JB: Vascular leakage in the dorsal root ganglia of the rat, studied with horseradish peroxidase. J Neurol Sci 29:95-107, 1976

Kadyi H: Über die Blutgefässe des menschlichen Rückenmarkes. Anat Anz 1:304-314, 1886 (Cited by Gillilan 1958)

Karnovsky MJ: A formaldehyde-glutaraldehyde fixative of high osmolality for use in electron microscopy. J Cell Biol 27:137A-138A, 1965

Klatzo I, Miquel J, Ferris PJ, Prokop JD & Smith DE: Observations on the passage of the fluorescein labelled serum proteins (FLSP) from the cerebrospinal fluid. J Neuropath Exp Neurol 23:18-35, 1964

Klemm H: Das Perineurium als Diffusionsbarriere gegenüber Peroxydase bei epi- und endoneuraler Applikation. Z Zellforsch 108:431-445, 1970

Lauritzen C, Bagge U & Romanus M: The effects of pressure and its duration on microcirculation and healing of skin flaps. An experimental study in rabbits. Scand J Plast Reconstr Surg 15:5-8, 1981

Lazorthes G, Gouazé A, Bastide G, Soutoul J-H, Zadeh O & Santini J-J: La vascularisation artérielle du renflement lombaire. Étude des variations et des suppléances. Rev Neurol 114:109-122, 1966

Lazorthes G, Gouaze A, Zadeh JO, Santini JJ, Lazorthes Y & Burdin P: Arterial vascularization of the spinal cord. Recent studies of the anastomtic substitution pathways. J Neurosurg 35:253-262, 1971

Low PA & Dyck PJ: Increased endoneurial fluid pressure in experimental lead neuropathy. Nature 269:427-428, 1977

Low PA, Dyck PJ & Schmelzer JD: Chronic elevation of endoneurial fluid pressure is associated with low-grade fiber pathology. Muscle Nerve 5:162-165, 1982

Low PA, Nukada H, Schmelzer JD, Tuck RR & Dyck PJ: Endoneurial oxygen tension and radial topography in nerve edema. Brain Res 341:147-154, 1985

Lundborg G & Brånemark PI: Microvascular structure and function of peripheral nerves. Adv Microcirc 1:66-88, 1968

Lundborg G: Ischemic nerve injury. Experimental studies on intraneural microvascular pathophysiology and nerve function in a limb subjected to temporary circulatory arrest. Scand J Plast Reconstr Surg (Supl 16), 1970

Lundborg G, Nordborg C, Rydevik B & Olsson Y: The effects of ischemia on the permeability of the perineurium to protein tracers in rabbit tibial nerve. Acta Neurol Scand 49:287-294, 1973

Lundborg G: Structure and function of the intraneural microvessels as related to trauma, edema and nerve function. J Bone Joint Surg 57A: 938-948, 1975

Lundborg G, Gelberman RH, Minteer-Convery M, Lee YF & Hargens AR: Median nerve compression in the carpal tunnel - Functional response to experimentally induced controlled pressure. J Hand Surg 7:252-259, 1982

Lundborg G, Myers R & Powell H: Nerve compression injury and increased endoneurial fluid pressure: a "miniature compartment syndrome". J Neurol Neurosurg Psychiat 46:1119-1124, 1983

Lundborg G: Nerve injury and repair. Churchill-Livingstone, Edinburgh, London, Melbourne & New York, 1988

Lundskog J, Brånemark PI & Lindström J: Biomicroscopic evaluation of microangiographic techniques. Adv Microcirc 1:152-160, 1968

MacGregor RJ, Sharpless SK & Luttges MW: A pressure vessel model for nerve compression. J Neurol Sci 24:299-304, 1975

Maroudas A: Nutrition and metabolism of the intervertebral disc. In: Idiopathic low back pain. White AA, Gordon SL (ed). The C V Mosby Co., St Louis, Missouri, pp 370-390, 1982

McCabe JS & Low FN: The subarachnoid angle: An area of transition in peripheral nerve. Anat Rec 164:15-34, 1969

Magnaes B: Clinical recording of pressure on the spinal cord and cauda equina. 1. The spinal block infusion test: method and clinical studies. J Neurosurg 57:48-56, 1982

Mita F, Ooi Y, Sunaga A, Suzuki S & Satoh Y: Myeloscopic study on lumbar spinal canal stenosis with special reference to intermittent claudication. Trans. International Society for the Study of the Lumbar Spine, Kyoto, Japan, May 1989

Mixter WJ & Barr JS: Rupture of the intervertebral disc with involvement of the spinal canal. New Engl J Med 211:210-215, 1934

Mooney V & Robertson J: The facet syndrome. Clin Orthop 115:149-156, 1976

Moore RA, Bullingham RES, McQuay HJ, Hand CW, Aspel JB, Allen MC & Thomas D: Dural permeability to narcotics: in vitro determination and application to epidural administration. Br J Anaesth 54:1117-1128, 1982

Mount LE & Ingram DL: The pig as a laboratory animal. Academic Press, London & New York, 1971

Murphy RW: Nerve roots and spinal nerves in degenerative disk disease. Clin Orthop 129:46-60, 1977

Myers RR & Powell HC: Endoneurial fluid pressure in perpiheral neuropthies, Tissue fluid pressure and composition, Ed AR Hargens, Baltimore, Williams & Wilkins, pp 193-207, 1981

Myers RR, Mizisin AP, Powell HC & Lampert PW: Reduced nerve blood flow in hexachlorophene neuropathy. Relationship to elevated endoneurial fluid pressure. J Neuropathol Exp Neurol 41:391-399, 1982

Myers RR & Powell CC: Galactose neuropathy: Impact of chronic endoneurial edema on nerve blood flow. Ann Neurol 16:587-594, 1984

Nachemson A & Elfström G: Intravital dynamic pressure measurements in lumbar discs. Scand J Rehab Med, (Suppl 1), 1970

Nachemson A : The lumbar spine - An orthopaedic challenge. Spine 1:59-71, 1976

Nachemson AL & Andersson GBJ: Classification of low back pain. Scand J Work Environ Health 8:134-136, 1982

Nachemson A: Advances in low-back pain. Clin Orthop 200:266-278, 1985

Nukada H, Dyck PJ & Karnes JL: Spatial distribution of capillaries in rat nerves: correlation to ischemic damage. Exp Neurol 87:369-376, 1985

Ochoa J, Fowler TJ & Gilliat RW: Anatomical changes in peripheral nerves compressed by a pneumatic tourniquet. J Anat 113:433-455, 1972

Olmarker K, Holm S & Rydevik B: More pronounced effects of double level compression than single level compression on impulse propagation in the porcine cauda equina. To be presented at the annual meeting of the International Society for the Study of the Lumbar Spine, Boston, MA, June, 1990

Olsson Y: Studies on vascular permeability in peripheral nerves. I. Distribution of circulating fluorescent serum albumin in normal, crushed and sectioned rat sciatic nerve. Acta Neuropathol 7:1-15, 1966

Olsson Y: Topographical differences in the vascular permeability of the peripheral nervous system. Acta Neuropathol 10:26-33, 1968

Olsson Y & Reese TS: Inaccessibility of the endoneurium of mouse sciatic nerve to exogenous proteins. American association of anatomists' 82nd Annual session. Anat Rec 163:138, 1969

Olsson Y: Studies on vascular permeability in peripheral nerves. IV. Distribution of intravenously injected protein tracers in the peripheral nervous system of various species. Acta Neuropathol (Berl) 17:114-126, 1971a

Olsson Y & Reese TS: Permeability of vasa nervorum and perineurium in mouse sciatic nerve studied by fluorescence and electronmicroscopy. J Neuropathol Exp Neurol 30:105-119, 1971b

Ooi Y, Mikanagi K, Satoh Y, Inoue K & Shibuya K: Clinical experiences of myeloscopy. Trans. International Society for the Study of the Lumbar Spine, New Orleans, LA, May 1980

Parke WW, Gamell K & Rothman RH: Arterial vascularization of the cauda equina. J Bone Joint Surg 63A:53-62, 1981

Parke WW & Watanabe R: The intrinsic vasculature of the lumbosacral spinal nerve roots. Spine 10:508-515, 1985

Pedowitz RA, Rydevik BL, Hargens AR, Swenson MR, Myers RR & Garfin SR: Motor and sensory nerve root conduction deficit induced by acute graded compression of the pig cauda equina. Trans. Orthopaedic Research Society, Atlanta, Georgia, Feb 1988

Pedowitz RA, Rydevik BL, Hargens AR, Swenson MR, Massie J, Lee S, Myers RR & Garfin SR: The effects of magnitude and duration of acute compression upon impulse conduction in the pig cauda equina: differential recovery of sensory and motor nerve roots. Trans. Orthopaedic Research Society, Las Vegas, Nevada, Feb 1989

Petterson CÅV & Olsson Y: Blood supply of spinal nerve roots. An experimental study in the rat. Acta Neuropathol 78:455-461, 1989

Porter RW, Hibbert C & Evans C: The natural history of root entrapment syndrome. Spine 9:418-422, 1984

Rauschning W: Computed tomography and cryomicrotomy of lumbar spine specimens. A new technique for multiplanar anatomic correlation. Spine 8:170-180, 1983

Rauschning W: Normal and pathologic anatomy of the lumbar root canals. Spine 12:1008-1019, 1987

Richardsson KC, Jarett L & Finke EH: Embedding in epoxy resins for ultrathin sectioning in electron microscope. Stain Technol 35:313-323, 1960.

Rydevik B, Lundborg G & Nordborg C: Intraneural tissue reactions induced by internal neurolysis. Scand J Plast Reconstr Surg 10:3-8, 1976

Rydevik B & Lundborg G: Permeability of intraneural microvessels and perineurium following acute, graded nerve compression. Scand J Plast Reconstr Surg 11:179-187, 1977

Rydevik B & Nordborg C: Changes in nerve function and nerve fiber structure induced by acute, graded compression. J Neurol Neurosurg Psychiatry 43:1070-1082, 1980a

Rydevik B, McLean WG, Sjöstrand J & Lundborg G: Blockage of axonal transport induced by acute, graded compression of the rabbit vagus nerve. J Neurol Neurosurg Psychiatry 43:690-698, 1980b

Rydevik B, Lundborg G & Bagge U: Effects of graded compression on intraneural blood flow. J Hand Surg 6:3-12, 1981

Rydevik B, Brown MD & Lundborg G: Pathoanatomy and pathophysiology of nerve root compression. Spine 9:7-15, 1984

Rydevik B, Myers RR & Powell HC: Pressure increase in the dorsal root ganglion following mechanical compression. Closed compartment syndrome in nerve roots. Spine 14:574-576, 1989a

Rydevik B, Lundborg G & Skalak R: Biomechanics of peripheral nerves. In: Basic biomechanics of the musculoskeletal system. M Nordin & VH Frankel (Eds). Lea and Febiger, Philadelphia, pp 75-87, 1989b

Rydevik B, Holm S, Brown MD & Lundborg G: Diffusion from the cerebrospinal fluid as a nutritional pathway for spinal nerve roots. Acta Physiol Scand 138:247-248, 1990a

Rydevik BL, Pedowitz RA, Hargens AR, Swenson MR, Myers RR & Garfin SR: Effects of acute graded compression on spinal nerve root function and structure: An experimental study on the pig cauda equina. Spine (in press), 1990b

Rydevik BL, Kwan MK, Myers RR, Brown RA, Triggs KJ, Woo S L-Y & Garfin SR: An in vitro mechanical and histological study of acute stretching on rabbit tibial nerve. J Orthop Res (in press), 1990c

Sachs B & Fraenkel J: Progressive ankylotic rigidity of the spine. J Nerv Ment Dis 27:1-15, 1900

Schmorl G: Über knorpelknoten an der Hinterfläche der Wirbelbandscheiben. Fortschritte der Gebiete der Röntgenstrahlen 1926

Schönström NSR, Bolender NFr, Spengler DM & Hansson TH: Pressure changes within the cauda equina following constriction of the dural sac. An in vitro experimental study. Spine 9:604-607, 1984

Schönström NSR, Bolender NFr & Spengler DM: The pathomorphology of spinal stenosis as seen on CT-scans of the lumbar spine. Spine 10:806-811, 1985

Shanta TR & Bourne GH: The peripheral epithelium - a new concept. In: Structure and function of nervous tissue. Bourne GH (Ed). Vol. 1. Academic Press, New York & London, pp 379-459, 1969

Sharpless SK: Susceptibility of spinal nerve roots to compression block. The research status of spinal manipulative therapy. NIH-workshop, February 2-4 1975. NINCDS Monograph no.15, edited by M Goldstein, pp 155-161, 1975

Spencer DL, Irwin GS & Miller JAA: Anatomy and significance of fixation of the lumbosacral nerve roots in sciatica, Spine 8:672-679, 1983

Spencer DL, Miller JAA & Bertolini JE: The effects of intervertebral disc space narrowing on the contact force between the nerve root and a simulated disc protrusion. Spine 9:422-426, 1984

Steer JM: Some observations on the fine structure of rat dorsal spinal nerve roots. J Anat 109:467-485, 1971

Stenqvist O & Bagge U: Cuff pressure and microvascular occlusion in the tracheal mucosa. Acta Otolaryngol 88:451-454, 1979

Stodieck LS, Beel JA & Luttges MW: Structural properties of spinal nerve roots: Protein composition. Exp Neurol 91:41-51, 1986

Suh TH & Alexander L: Vascular system of the human spinal cord. Arch Neurol Psychiat 41:659-677, 1939

Sunderland S: The connective tissues of peripheral nerves. Brain 88:841, 1965.

Sunderland S: The nerve lesion in the carpal tunnel syndrome. J Neurol Neurosurg Psychiatry 39:615-626, 1976

Sunderland S: Nerves and nerve injuries. 2nd edition. Churchill & Livingstone, Edinburgh, 1978

Takata K, Inoue S-I, Takahashi K & Ohtsuka Y: Swelling of the cauda equina in patients who have herniation of a lumbar disc. J Bone Joint Surg 70A: 361-368, 1988

Tanon L: Les artères de la moelle dorsolombaire. Thesis, Paris 1908

Tarlov IM: Structure of the nerve root. I Nature of the junction between the central and the peripheral nervous system. Arch Neurol Psyciat 37:555-583, 1937

Tennyson M & Gershon MD: Chapter 5. Light and electron microscopy of dorsal root, sympathetic, and enteric ganglia. In: Peripheral Neuropathy, vol 1. PJ Dyck, PK Thomas, EH Lambert, R Bunge (Eds). WB Saunders Company, Philadelphia, London, Toronto, Mexico City, Rio de Janerio, Sydney & Tokyo,pp 121-155, 1984

Thomas PK & Jones PG: The cellular response to nerve injury. 2. Regeneration of the perineurium after nerve section. J Anat 101:45-55, 1967

Thomas PK & Olsson Y: Chapter 4. Microscopic anatomy and function of the connective tissue components of peripheral nerve. In: Peripheral Neuropathy, vol 1. PJ Dyck, PK Thomas, EH Lambert, R Bunge (Eds). WB Saunders Company, Philadelphia, London, Toronto, Mexico City, Rio de Janerio, Sydney & Tokyo, pp 97-120, 1984

Thomsen R: Über eigenthümlige aus veränderten Ganglienzellen hervorgegangene Gebilde in den Stämmen der Hirnnerven des menschen. Virschovs Arch f Path Anat 109:459, 1887

Upton RM & McComas AJ: The double-crush in nerve entrapment syndromes. Lancet 2:359-362, 1973

Urban JPG, Holm S, Maroudas A & Nachemson A: Nutrition of the intervertebral disc. An in vivo study of solute transport. Clin Orthop 129:101-05, 1977

Urban JPG, Holm S & Maroudas A: Diffusion of small solutes into the intervertebral disc: An in vivo study. Biorheology 15:203-223, 1978

Urban JPG, Holm S, Maroudas A & Nachemson A: Nutrition of the intervertebral disc. Effect of fluid flow on solute transport. Clin Orthop 170:296-99, 1982

Waggener JD & Beggs J: The membranous coverings of neural tissues: An electron microscopy study. J Neuropath 26:412-426, 1967

Waksman BH: Experimental studies of diphtheritic polyneuritis in the rabbit and guinea pig. III The blood-nerve barrier in the rabbit. J Neuropath Exp Neurol 20:35-77, 1961

Wall EJ, Cohen MS, Massie JM, Rydevik B & Garfin SR: Cauda equina anatomy. Part I: Intrathecal nerve root organisation. Spine (in press), 1990

Watanabe R & Parke WW: Vascular and neural pathology of lumbosacral spinal stenosis. J Neurosurg 64:64-70, 1986

Weinstein JN, Pope M & Schmidt R: The effects of low frequency vibration on dorsal root ganglion substance "P". Neuro Orthop 4:24-30, 1987

Weinstein JN, Pope M, Schmidt R & Seroussi R: Neuropharmological effects of vibration: An animal model. Spine 13:521-525, 1988

Weinstein J, LaMotte R & Rydevik B: Chapter 4. Nerve. In: New perspectives on low back pain. Frymoyer JW & Gordon SL (Eds). American Academy of Orthopaedic Surgeons, Parke Ridge, pp 35-130, 1989

Welch MH & Pollay M: The spinal arachnoid villi of the monkeys cercopithecus aethiops sabaeus and macaca irus. Anat Rec 145:43-48, 1963

Verbiest H: A radicular syndrome from developmental narrowing of the lumbar spine vertebral canal. J Bone Joint Surg 36B:230-237, 1954

Viraswami V: A study of the blood supply of the nerve roots in man and the rabbit with an experimental analysis of the collateral circulation following ligature of the arteries. Thesis, London, 1963

Yaksh TL: Spinal opiate analgesia: Characteristics and principles of action. Pain 11:293-346, 1981

Yaksh TL & Reddy SVR: Studies in the primate on the analgetic effects associated with intrathecal actions of opiates, alfa-adrenergic agonists and baclofen. Anaesthesiology 54:451-467, 1981

Yoshizawa H, Kobayashi S & Kubota K: Effects of compression on intraradicular blood flow in dog. Spine 14:1220-1225, 1989a

Yoshizawa H, Hachiya Y & Kobayashi S: Experimental study on disturbance of the blood flow in lumbar spinal ganglion. Trans. International Society for the Study of the Lumbar Spine, Kyoto, Japan, May 1989b

Goterna, Kungälv 1990.46727